

OPEN ANTERIOR CORDOTOMY AS A POSSIBLE TECHNIQUE FOR PAIN RELIEF IN CANCER PATIENT: AN EXPERIENCE WITH SEVEN CASES

Sheikhrezai, A., Tabatabai, A and Hussain Khan, Z.

Department of Neurosurgery, Tehran University of Medical Sciences, Tehran, Iran.

Abstract — Seven patients who had intractable pain of the pelvis and lower extremities were scheduled for cordotomy of the spinothalamic tracts after preliminary investigations. In three patients laminectomy was performed, to approach the anterior portion of the spinal cord, and in the rest anterior cordotomy was performed with anterior disectomy under direct vision of the spinal cord. It appears that anterior approach is an alternative technique for anterior cordotomy in some patients.

Acta Medica Iranica 34 (1 & 2): 46 - 48; 1996

Key words: Cordotomy; intractable pain; spinothalamic tract.

posterior approach cordotomy with laminectomy and four patients were approached anteriorly and underwent microscopic disectomy along with cordotomy and severing the spinothalamic tracts. One of the patients had parapelvic pain as a result of bullet injury to the spinal cord where as the other six patients as depicted in Table 1 had intraabdominal and intrapelvic malignant tumour. The latter category had severe pain despite radiotherapy and chemotherapy and had to get 10 to 16 injections of morphine daily.

INTRODUCTION

Treatment of excruciating pain in the lower limbs and the trunk specially when the causative agent is malignant tumour which can not be treated by radical surgery or when the pain is the result of trauma to the spinal cord, remains a problem for the physicians. Although the use of non narcotic and opioid analgesics in the beginning may temporarily alleviate the suffering, but gradually in a short span of time, these effects disappear (1,2,3,4). One of the effective surgical means of treating these pains is to interrupt the pain pathways. In 1912 Spiller and Martin (2,4) advocated anterior cordotomy by performing laminectomy, Cloward in 1968 performed anterior cervical approach for cordotomy (5). Although open cordotomy was a satisfactory operation the development of percutaneous technique by Mullan and associates in 1965 eclipsed the open cordotomy. But still some practitioners advocate open procedure because of nonavailability of percutaneous technique or in sick patients unable to travel long distances.

MATERIALS AND METHODS

Seven patients after necessary evaluation were selected for cordotomy. Three patients were to undergo

OPERATIVE TECHNIQUE

The technique commonly referred to in the text - books is laminectomy. Severing the spinothalamic pathways under direct vision is not feasible and a dental mirror is needed, therefore the possibility of anterior spinal artery insult or incomplete cordotomy exists. (2,6) But in the anterior approach, disectomy at levels C7/T1 or C6/C7 is performed and by the Cloward instrument and making a canal of the radius of 1.8 cm between the bodies of adjacent vertebrae; it is possible to open posterior longitudinal ligament and dura matter in a cruciate fashion, the anterior half of spinal cord and anterior spinal artery are brought under direct microscopic vision (Fig. 1). With the help of fine surgical blade or sharp microscopic dissector just in close proximity to the anterior spinal cord centered in a depth of 5 mm. By rotating and revolving these instruments the spinothalamic tract can be severed. Depending on whether the visceral pain unilateral or bilateral, this operation can be performed on and or both sides (although bilateral cordotomy presents a great risk in the upper cervical region, nevertheless it can be performed in the lower cervical and upper thoracic segments with comparatively low risk), after that the dura is closed with 7-0 nylon so as to prevent CSF leakage. In both surgical techniques, neurolept analgesia is utilised, so that the motor system of the patient remains within our control.

RESULTS

One of the patients who was paraplegic due to war injury did not respond well to cordotomy and the patient in addition developed radicular pain in the left hand. Eventually this patient underwent stereotactic thalamotomy but continues to use opioid analgesics. Among the rest of the 6 patients, 4 patients who were

operated by anterior approach did not need any opioids 3 days after the operation, whereas the other 2 patients who are treated with laminectomy had reduced pain but not were pain-free as in the anterior approach. The 6 patients whose pain was due to malignant lesions in the abdomen and pelvic region were not paraplegic prior to surgery and did not get neurological deficit or other complications after the operation (Table. 1)

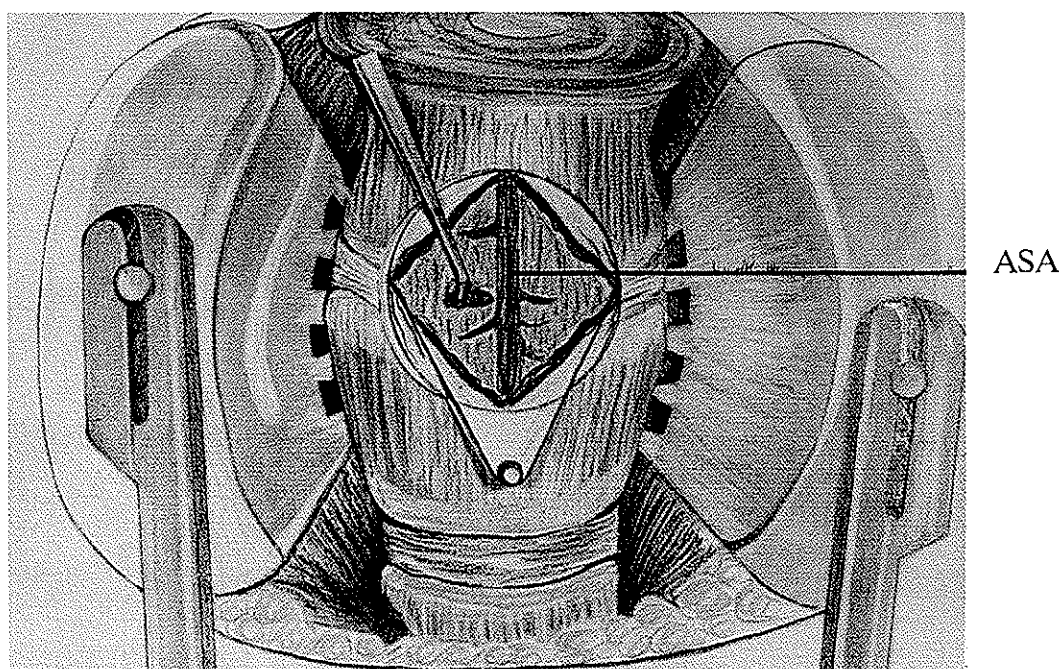


Fig. 1. A hand made diagram and an enlarged microscopic view of the operative field where Cloward instrument is used. Anterior portion of spinal cord and anterior spinal artery (ASA) are visible.

Table 1. Seven cases operated for intractable pain

Case No	Age sex	Malignancy	Cordotomy level	Analgesia	Pain relief on discharge	Complication	Late result
1	52 F	Cervix	bilat. T ₁ - T ₂	T ₆ - T ₈	++	non	5 month
2	63 M	Left hip sarcoma	R. T ₁ - T ₂	T ₆ - T ₈	+++	Transit left leg paresy	4 month
3	25 M	Spinal cord injury	bilat. T ₁ - T ₂	T _n	—	Root injury	talamotomy
4	20 M	Sacral sarcoma	bilat. C ₇ / T ₁	T ₄	+++	non	8 month
5	55 F	Cervix	bilat. C ₆ / C ₇	T ₄ - T ₅	++++	non	Still 9 month
6	65 M	adeno carcionoma (prostat)	bilat. C ₆ / C ₇	T ₅ - T ₆	++++	non	Still 8 month
7	35 M	Osteosarcoma	bilat. C ₆ / C ₇	T ₅ - T ₆	++++	non	Still 6 month

DISCUSSION

There are several modalities of treatment for intractable pain which in order of preference are as follow (2,3,4).

- * Radical treatment.
- * Non narcotic medication.
- * Opioid medication.
- * Nerve block
- * Acupuncture
- * Psychological treatment
- * Percutaneous neurectomy or rhizotomy
- * Morphine instillation into CSF
- * DREZ lesion
- * Neuro-medication
- * Cordotomy
- * Stimulation of pre-ventricular gray matter
- * Stereotactic mesencephalotomy
- * Intrahypophyseal injection of alcohol or hypophysectomy.

But now all of these treatments are overshadowed by chronic infusion of morphine.

Whenever one resorts to severing the spinothalamic pathways as a treatment modality for intractable pain secondary to malignant lesion, this can be performed by percutaneous cordotomy as well (2,4,6,7) but this technique needs sufficient skill in puncturing C1/C7 and radiofrequency.

As most of the cancer patients have midline or bilateral pain and severing spinothalamic tracts by C1/C2 puncture on both sides may endanger the reticulospinal tracts and even cause apnea (2,7).

In cordotomy by laminectomy technique, because of insufficient vision of the anterior 1/4 of spinal cord, there is a danger of bleeding of the anterior spinal artery (ASA) and inadequate cutting of the spinothalamic pathways (2,3,4,8). But with the anterior approach and with the help of a microscope the damage of ASA does

not arise and moreover the spinothalamic pathways are completely severed. The spinocerebellar tract can be preserved as well with further care. In addition supine position in this technique is more physiologically acceptable than the prone position in posterior approach. The end result is that these patients who have malignant lesions or have intractable pain in the lower trunk can reasonably benefit from this approach without causing added neurological deficits. However patients who have prolonged life span might develop pain later through other spinal tracts (1) and in such condition, other modalities of treatment should be considered.

REFERENCES

1. Adams, Maurice Victor.; Principles of Neurology Fifth Edition, pp, 111-128, 1993.
2. Brackett, C.E.: Cordotomy by open operative Techniques. In Youmans, J.R., ed.: Neurological, surgery, 2nd Ed., Vol.6. Philadelphia, W.B. Saunders Company, PP.3696-3701. 1982.
3. Sindou, M., and Lapras, C.: Neurosurgical treatment of pain in the pancoast syndrome: Advances in pain Research and therapy. Vol.2. Newyork, Raven press. PP.199-206. 1982.
4. Willis, W.D.: Spiothalamic system: physiological aspects. Advances pain Res. Ther., 1: 215-223. 1976.
5. Cloward, R.B.: Cervical Cordotomy by anterior approach: Technique & advantages. J. Neurosurgery., 21: 91-25. 1964.
6. R.R. Tasker.: Cordotomy by open operative technique. in Youmans, J.R., ed.: Neurological surgery, 3d Ed., Vol.6. Philadelphia, W.B. Saunders company PP.4059-40 69. 1990.
7. Ischia, S., Ischia, A., Luzzani, A., Toscano, D., and steel, A.: Results up to death in the treatment of Persistent cervico - thorasic (pancoast) and thorasic malignant pain by unilateral percutaneous cervical cordotomy. pain, 21: 339-355. 1985.