

Two cases of H1N1 influenza infection as the initial presentation of acute leukemia

Leylagül KAYNAR¹, Serdar ŞIVGIN¹, Osman BAŞPINAR¹, Fatih KURNAZ¹, Afra YILDIRIM²,
Gökhan METAN³

Abstract: Pandemic 2009 influenza A virus (H1N1) is a new influenza virus causing illness in human populations. Immunocompromised patients are at high risk for the acquisition of influenza and serious influenza-associated complications. However, there are no reports about patients with both newly diagnosed acute leukemia and H1N1 influenza infection. We reported 2 cases of previously healthy patients with H1N1 influenza infection as the initial presentation of acute leukemia.

Key words: H1N1 virus, influenza infection, acute leukemia

Akut lösemnin başlangıç bulgusu olarak H1N1 influenza enfeksiyonu olan iki vaka

Özet: Pandemik 2009 influenza A virusu insanlarda hastalığa yol açan yeni bir influenza virusüdür. İmmünkompromize hastalar, influenza enfeksiyonuna yakalanma ve enfeksiyon ilişkili komplikasyonların görülmesi açısından daha fazla riske sahiptirler. Bununla birlikte, literatürde H1N1 enfeksiyonu ile ortaya çıkan yeni tanı akut lösemi olgusuna rastlanmadı. Burada daha önce sağlıklı olduğu bilinen, ilk kez H1N1 influenza enfeksiyonu ile bulgu veren yeni tanı akut lösemili, iki vakayı sunduk.

Anahtar sözcükler: H1N1 virusu, influenza enfeksiyonu, akut lösemi

Introduction

A novel influenza A virus, pandemic 2009 influenza A (H1N1), has been identified as the cause of an epidemic outbreak of respiratory illness throughout the world. This new virus was first identified in April 2009 in symptomatic human infections in Mexico (1). The virus is spreading from person-to-person worldwide, probably in much the same way that regular seasonal influenza viruses spread (2). Patients with hematologic malignancies are likely to be at an increased risk for influenza or other infections.

In contrast with the common opinion/perception that pandemic H1N1 infection causes only mild disease in immunocompetent patients, hospitalization and death occurred at all ages (3). Immunocompromised patients may be at risk for serious influenza-associated complications (4).

We reported 2 cases of previously healthy patients with H1N1 influenza infection with severe pneumonia as the initial presentation of acute leukemia.

Received: 17.03.2010 – Accepted: 02.08.2010

¹ Department of Hematology, Faculty of Medicine, Erciyes University, Kayseri - TURKEY

² Department of Radiodiagnostics, Faculty of Medicine, Erciyes University, Kayseri - TURKEY

³ Department of Infectious Diseases and Clinical Microbiology, Faculty of Medicine, Erciyes University, Kayseri - TURKEY

Correspondence: Leylagül KAYNAR, Department of Hematology, Faculty of Medicine, Erciyes University, Kayseri - TURKEY
E-mail: drleylagul@gmail.com

Case report 1

A 23-year-old, previously healthy male patient complaining of fever, coughing, sore throat, headache, and diarrhea for the past few days was admitted to emergency services. In the emergency evaluation his clinical status was moderate, he had a fever (39.2 °C) and tachycardia (120/min), arterial blood pressure was 100/60 mmHg, and the oropharynx was hyperemic. On auscultation of the chest crepitant rales were noted, especially over both mid-zones and the lower lobes of the right lung. The findings of the complete blood count examination were as follows: WBC 5660/mm³, hemoglobin 10 g/dL, and platelet count 24,000/mm³. In peripheral blood staining, myeloblasts, some of which had Auer rods, were present at 70%. Consolidated areas were detected on the chest radiograph, especially on the mediate and lower zones of the right lung (Figure 1a). The patient diagnosis was confirmed with flow cytometric evaluation as acute myeloid leukemia. H1N1 infection was suspected, and nasal swabs were obtained just before oseltamivir treatment at doses of 75 mg twice daily. H1N1 PCR results were positive in nasal swabs obtained from the patient, as reported by the National Sanitation Institute, Ministry of Health, Ankara. In a computerized tomography (CT) examination of the chest area consolidated areas containing air bronchogram closure with ground glass regions were detected, especially in all

areas of the right lung (Figure 1b). Moxifloxacin and piperacillin-tazobactam were subsequently added to the treatment as a bacterial pneumonia diagnosis could not be excluded. The treatment was completed on the 10th day. The patient improved clinically and was given daunorubicin at a dose of 90 mg/m² for 7 days combined with cytarabine 200 mg/m² for 3 days, for the treatment of acute myeloid leukemia. The patient experienced a complete remission after the chemotherapeutic regimen and is still being treated with consolidation regimens.

Case report 2

A 24-year-old, previously healthy male patient complaining of fever, shivering, and sore throat which began 3 days previous was hospitalized in a medical center. In the center H1N1 infection was suspected, and a nasal swab was obtained and sent for PCR testing before beginning oseltamivir treatment at doses of 75 mg twice daily. Unfortunately, on the same day, due to worsening respiratory parameters, he was transported to our hospital for probable intensive care support. In the emergency services evaluation his clinical status was moderate. He had a fever (39 °C), the oropharynx was hyperemic, and there were rales over his entire right and left lungs, especially in the bases. The findings of the complete blood count examination were as follows: WBC

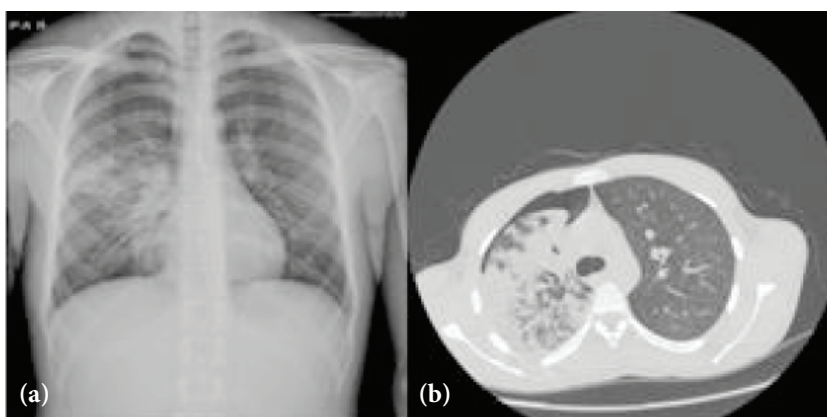


Figure 1. (a) Chest radiograph obtained at hospital admission shows poorly defined areas of consolidation in the middle and lower zones of the right lung. (b) Chest CT lung window image shows widespread areas of consolidation and ground-glass opacities in the right lung. A small-sized right pneumothorax was detected.

4060/mm³ (58% neutrophil, 29% lymphocyte, 12% monocyte, 1% eosinophil), hemoglobin was 8.7 g/dL, platelet count 239,000/mm³, and peripheral blood staining was morphologically normal. On the chest radiograph consolidated areas were detected on the entire right lung and mediate and lower zones of the left lung (Figure 2a). A CT examination of the chest showed peripheral and lower-lung-predominant consolidations and ground-glass opacities (Figure 2b). H1N1 PCR results were reported positive by the National Sanitation Institute, Ministry of Health, Ankara. Moxifloxacin was added to the treatment as a secondary bacterial pneumonia diagnosis could not be excluded. On the same day he clinically worsened; his blood pressure was low, dyspnea and hypoxia developed, and he was later admitted to the intensive care unit for bi-level positive airway pressure support. Later ampicillin-sulbactam was added at a dosage of 2 g, administered 3 times a day intravenously. On the third day of hospitalization pancytopenia was detected. Although no blast was seen in peripheral blood smear, bone marrow aspiration was found to be infiltrated by lymphoblasts. He was diagnosed with Philadelphia-positive acute lymphoblastic B-cell leukemia through flow cytometry and immunohistochemistry (Figure 1a, b). In a thoracic CT examination bilateral consolidated areas containing diffuse air bronchograms and partial

infiltrative sites were detected. Antiviral and antibiotic therapies were completed on the 10th day. Immediately following treatment, platelet and leukocyte counts recovered, but blasts still remained in the bone marrow specimen evaluation. Philadelphia chromosome t(9;22) p190 was positive in cytogenetic testing. The patient was diagnosed Philadelphia-positive ALL, and an appropriate chemotherapeutic regimen was started combined with imatinib. Treatment is ongoing.

Discussion

Pandemic 2009 H1N1 infection has generally been associated with mild symptoms that, in most of instances, are similar to those of seasonal influenza. The most common symptoms in patients with H1N1 virus infection are fever, cough, and sore throat. Other symptoms reported by patients include rhinorrhea, myalgia, arthralgia, nasal congestion, headache, fatigue, nausea and vomiting, and diarrhea (5). Cancer patients are at high risk for acquisition of influenza in both community and healthcare settings (4). Similar to immunocompetent patients, most patients with influenza infections and hematologic malignancies present with symptomatic respiratory symptoms consisting of sore throat, nasal symptoms, malaise, and/or headache (4).

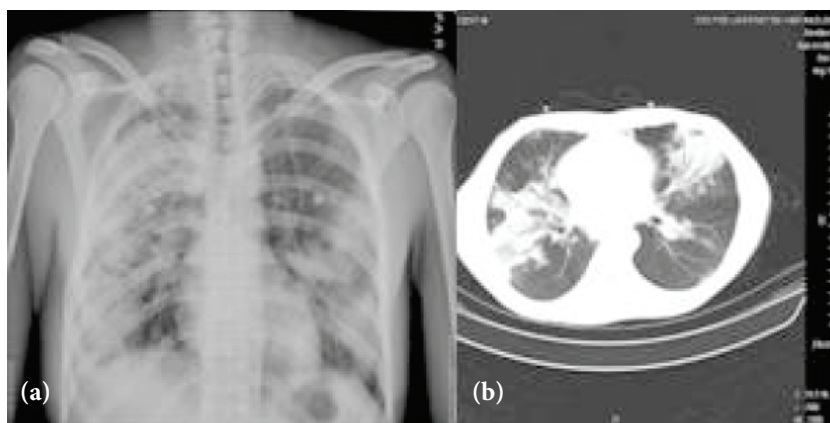


Figure 2. (a) Chest radiograph shows extensive peripheral opacities in the right lung and in the middle and lower zones of the left lung.
(b) Chest CT images show multifocal, bilateral consolidation and ground-glass opacities, predominantly in the right lung.

In laboratory evaluations Bin Cao et al. reported that mild leukopenia was observed in 21.4% of 412 patients with influenza infection and lymphopenia in 68.1% of adult influenza patients. No anemia was reported. Among the patients with leukopenia the condition developed 2 days after the onset of illness, and white cell counts returned to normal 7 days after the onset of illness (5).

The most commonly reported causes of death were viral pneumonia and acute respiratory distress syndrome (3). The most significant risk factor for progression to lower tract disease is profound lymphopenia. However, risk factors for 2009 H1N1 influenza disease progression to lower respiratory tract disease among hematologic malignancy patients are not known (4).

Immunocompromised patients are at very high risk for serious influenza complications that result in high rates of hospitalization, intensive care unit admission, and mortality (6). Different studies reported case fatalities from 11% to 33%. The available data are too limited to distinguish frequency and mortality differences among patients with different malignancies and different chemotherapeutic regimens (7).

The first case was diagnosed with H1N1 influenza infection, pneumonia, and acute myeloid leukemia at an emergency unit. Total blood count for the second case, however, showed only anemia, and the blood smear was normal. The patient in the second case was diagnosed with H1N1 influenza infection and pneumonia when he was admitted to the hospital. During hospitalization pancytopenia developed, but the reason for onset could not be explained. Bone marrow aspiration and trephine biopsy are recommended for patients with unexplained cytopenia (8). The bone marrow aspiration/biopsy showed acute leukemia. For this reason, bone marrow aspiration or biopsy should be considered both to determine the cause of prolonged cytopenia and to eliminate any other disease that may cause cytopenia,

even if H1N1 viral infection or other infections are accurately diagnosed in these patients.

Factors implicated in leukaemogenesis are very complex. In particular, the hypotheses of childhood acute leukemia suggest that common infections and lack of immunity shortly before the leukemia diagnosis could be the cause of leukemia (9). In a similar vein Timonen et al. suggested that influenza could cause successive and co-operative mutations leading to acute leukemia with a short latency (10). The 2 cases reported here occurred in previously healthy patients with H1N1 influenza infection as the initial presentation of acute leukemia. It is significant that they had no previous complaints before the onset of influenza symptoms. In the second case leukemia blasts were never seen in the blood smear. After the treatment for influenza the patient's leukopenia and thrombocytopenia improved. It was observed in the second bone marrow aspiration, however, that lymphoid blasts remained in the bone marrow, and t(9;22) p190 was positive. This may be explained by the diagnosis of leukemia at an early stage.

These cases invite us to consider whether leukemia may be triggered by infection occurring close to the time of leukemia diagnosis or exposure to influenza shortly before leukemia diagnosis (9).

It will be useful to report on additional patients in order to determine the clinical aspects and results of H1N1 and other influenza infections in patients newly diagnosed with leukemia and other malignancies. In patients who display cytopenia during H1N1 and other influenza infections the probable presence of acute leukemia and other diseases should be excluded. In addition, diagnostic methods such as bone marrow aspiration and biopsy should not be delayed.

Furthermore, in considering this ambiguous etiopathogenetic basis for leukemia, a large number of studies should be performed to evaluate the probable role of H1N1 and other viral infections.

References

1. Centers for Disease Control and Prevention. Outbreak of swine - origin influenza A (H1N1) virus infection - Mexico, March-April 2009. *Morb Mortal Wkly Rep.* 2009; 58: 467-70.
2. Swine Flu and You. CDC. 2009 – 04 - 26. Available from: URL: http://www.cdc.gov/swineflu/swineflu_you.htm. Accessed on 15 June 2010.
3. Louie JK, Acosta M, Winter K, Jean C, Gavali S, Schechter R et al. for the California Pandemic H1N1 Working Group. Factors Associated With Death or Hospitalization Due to Pandemic 2009 Influenza A (H1N1) Infection in California. *JAMA*, 2009; 302: 1896-1902.
4. Casper C, Englund J, Boeckh M. How we treat influenza in patients with hematologic malignancies. *Blood* 2010; 115: 1331-42.
5. Cao B, Li XW, Mao Y, Wang J, Lu HZ, Chen YS et al. National Influenza A Pandemic (H1N1) 2009 Clinical Investigation Group of China. Clinical features of the initial cases of 2009 pandemic influenza A (H1N1) virus infection in China. *N Engl J Med* 2009; 361: 2507-17.
6. Whitley RJ, Monto AS. Prevention and treatment of influenza in high-risk groups: children, pregnant women, immunocompromised hosts, and nursing home residents. *Clinical Features of the Initial Cases of 2009 Pandemic J Infect Dis* 2006; 194 Suppl 2: 133-8.
7. Kunisaki KM, Janoff EN. Influenza in immunosuppressed populations: a review of infection frequency, morbidity, mortality, and vaccine responses. *Lancet Infect Dis* 2009; 9: 493-504.
8. Ryan DH, Felgar RE. Examination of marrow. In Lichtman MA, Beutler E, Kipps T, Seligsohn U, Kaushansky K, Prchal J eds., *Williams Hematology*, 7th ed. New York: McGraw-Hill, 2006. p. 21-31.
9. Kroll ME, Draper GJ, Stiller CA, Murphy MF. Childhood leukemia incidence in Britain, 1974-2000: time trends and possible relation to influenza epidemics. *J Natl Cancer Inst* 2006; 98: 417-20.
10. Timonen T, Näyhä S, Koskela T, Pukkala E. Are sunlight deprivation and influenza epidemics associated with the onset of acute leukemia? *Haematologica* 2007; 92: 1553-56.