

Research Article

5-ALA Mediated Fluorescence Detection of Gastrointestinal Tumors

Ekaterina Borisova,¹ Borislav Vladimirov,² and Latchezar Avramov¹

¹*Institute of Electronics, Bulgarian Academy of Sciences, 72 Tsarigradsko Chaussee Boulevard, 1784 Sofia, Bulgaria*

²*Gastroenterology Department, University Hospital "Queen Giovanna", 8 Bjalo More Street, 1527 Sofia, Bulgaria*

Correspondence should be addressed to Ekaterina Borisova, borisova@ie.bas.bg

Received 7 March 2008; Revised 7 May 2008; Accepted 19 June 2008

Recommended by Stoyan Tanev

Delta-aminolevulinic acid/protoporphyrin IX is applied for fluorescent tumor detection in the upper part of gastrointestinal tract. The 5-ALA is administered per os six hours before measurements at dose 20 mg/kg weight. High-power light-emitting diode at 405 nm is used as an excitation source. Special opto-mechanical device is built to use the light guide of standard video-endoscopic system. Through endoscopic instrumental channel a fiber is applied to return information about fluorescence to microspectrometer. In such way, 1D detection and 2D visualization of the lesions' fluorescence are received, and both advantages and limitations of these methodologies are discussed in relation to their clinical applicability. Comparison of the spectra received from normal mucosa, inflammatory, and tumor areas is applied to evaluate the feasibility for development of simple but effective algorithm based on dimensionless ratio of the fluorescence signals at 560 and 635 nm, for differentiation of normal/abnormal gastrointestinal tissues.

Copyright © 2008 Ekaterina Borisova et al. This is an open access article distributed under the Creative Commons Attribution License, which permits unrestricted use, distribution, and reproduction in any medium, provided the original work is properly cited.

1. INTRODUCTION

The limitations of standard endoscopy for detection and evaluation of cancerous changes in gastrointestinal tract are significant challenge and initiative development of new diagnostic modalities, including optical detection of tissues alterations. One of the most widely examined spectroscopic techniques is laser- or light-induced fluorescence spectroscopy (LIFS), because of its rapid and highly sensitive response to early biochemical and morphological changes in the tissues. Fluorescent diagnosis of tumor tissues becomes a valuable tool in the clinical practice. This technique could be applied for detection and evaluation of tumors in different localizations using endoscopic equipment. Such combined white-light and fluorescent mode endoscopic systems are already developed and introduced in the clinic for the needs of bronchoscopy and lung cancer diagnosis, like D-Light system of Karl Storz GmbH, Tuttlingen, Germany, diagnostic autofluorescence endoscope (DAFE) system of Richard Wolf GmbH, Knittlingen, Germany, lung fluorescence endoscopy (LIFE) system of Xillix Technologies Corp., Richmond, Canada [1–4].

However, fluorescent gastroscopes are still on its research and development phases and from the best we know that the few existing systems, such as Olympus Evis Lucera, have not received yet approvals from FDA for access to the broad clinical market [5]. This system is a digestive tract videoscope used for observing blood vessels in mucous membranes under infrared light in the regions 790–820 nm and 905–970 nm. Variation of Xillix fluorescent endoscopic system is Xillix-LIFE-GI which is applied for autofluorescence detection of stomach neoplasia and has approval for Japan and European countries.

Several fluorescent endoscopy systems are developed and proposed also for practical applications by different research teams, demonstrating very good clinical results [4, 6–8], using autofluorescence or exogenous fluorescence detection of gastrointestinal neoplasia.

Despite of the fluorescent endoscopic systems developed mentioned above, the fluorescent diagnosis of tumors of the upper part of gastrointestinal tract still is very interesting and extensive research and development task worldwide. Spectral diagnosis can provide imaging and point spectroscopic information in both morphological and biochemical data

modes [1, 4, 9]. With the optimization of the procedures and evaluation of this technique diagnostic added value, through development of appropriate algorithms based on fluorescence properties of the investigated sites, a novel high-sensitive diagnostic tool could be successfully applied as complementary to the standard white light endoscopy [10–13].

In the case of autofluorescence detection, high sensitivity and specificity could be achieved if complex algorithms are applied for differentiation of the spectra [14]. However, on the current moment detecting the difference in autofluorescence as a gastroendoscopic image still has been relatively difficult task because of its faintness. Only combination of powerful light sources and highly sensitive detectors will lead to the development of autofluorescence gastroscopy clinical systems [1, 13]. Therefore, recent real-time gastrointestinal fluorescence endoscopy is all based on the use of exogenous fluorophores [1, 8, 12], as the addition of exogenous fluorescent compounds increases the contrast, improves endoscopic resolution and sampling, and could be used to receive better 2D visualization for the needs of clinicians.

Unfortunately, one typical problem of exogenous fluorophores' application, for example 5-ALA/PpIX for detection of gastrointestinal tumors, is the moderate specificity achieved. High false-positive values are obtained, mainly due to inflammation areas in the organs under interest. Sensitivity and specificity reported in different studies related to detection of esophageal neoplasia are 76% and 63% [15], 77% and 71% [16], 80% and 56% [17], respectively. Moreover, these values undergo significant changes in dependence of the amount of the photosensitizer applied—5, 10, 20, or 30 mg/kg 5-ALA and the way of sensitization—orally, using enema, or spray catheter [17, 18]. These differences are quite large—as the sensitivity and specificity for the cases of 10 mg/kg and 30 mg/kg oral application are 80% and 56%, as well as 100% and 27%, respectively. Local application of 5-ALA using spray catheter also reveals better values for sensitivity of the dysplastic lesions evaluation in colon than oral application of the drug, but specificity is lower—62% versus 73% (in the case of 20 mg/kg oral application) [18]. With increasing of the 5-ALA concentration orally applied, the specificity decreases very rapidly. Therefore, to achieve some optimization of the procedures and proper diagnosis, it is proposed to work with orally applied aminolevulinic acid, with concentration in the frames of 15–20 mg/kg for the gastrointestinal tract tumor detection [17, 18].

In the recent study, delta-aminolevulinic acid/protoporphyrin IX (5-ALA/PpIX) is also applied as fluorescent marker for tumor detection in esophagus and stomach. Normal and cancerous mucosas of esophagus and stomach as well as inflammatory areas fluorescence spectra are detected and compared in this study. Rapid lesions border determination using exogenous fluorescence signal is obtained in 1D scanning spectroscopic mode. Our results from in vivo detection show very good differentiation between normal and abnormal tissues in 1D spectroscopic regime, but moderate discrimination in 2D imaging. In the case of 2D video visualization, the problem of high autofluorescence signal in the red spectral region gives low contrast between

normal and abnormal mucosas when standard CCD camera of the endoscope is applied. This problem is in a process of resolve in our further investigations.

2. METHODS AND MATERIALS

Two variants of the fluorescent complimentary equipment to the standard gastroscope were applied for the needs of fluorescent diagnosis of the neoplasia in upper part of gastrointestinal tract. In the first one, we built light source that replace standard white light illuminator of the endoscope, and through instrumental channel a fluorescence collecting fiber (quartz-polymer single fiber, $d = 600 \mu\text{m}$, $NA = 0.22$) was applied. In the second variant, a fiber bundle was applied though instrumental channel of the endoscope, as the excitation light was delivered through central 1 fiber, and fluorescence response of the tissue was collected by surrounding 7 fibers and delivered to microspectrometer. The fiber bundle is specially developed for endoscopic applications in gastrointestinal tract (Polironik Ltd., Moscow, Russia), as the bundle used in this case consists of 8 quartz fibers, central one with diameter $200 \mu\text{m}$, and surrounding 7 fibers with diameter $100 \mu\text{m}$, all of them with numerical aperture 0.22. The central fiber is detached by thin aluminum folio from the surrounding fibers to avoid cross-signal between the fibers. Special resin is used on the end tip of the fiber bundle applied, due to its application in gastrointestinal tract—for patient safety and for enlarged resistance on the severe conditions in stomach environment. Both modalities have their advantages and disadvantages that will be described below.

In the first case, a special light source was developed for the needs of our experimental work, based on 405 nm high-power light-emitting diode OTLH-0360-UV-UV HIGH FLUX LED ILLUMINATOR (25 mW, Rhopoint Components Ltd, Oxted-Surrey, UK). This opto-mechanical device could replace common white light source of the standard endoscopic equipment (Olympus Corporation, Hertfordshire, UK) that is in use in the University Hospital “Queen Giovanna,” Sofia, Bulgaria. Through endoscopic instrumental channel, a quartz-polymer fiber was applied to return information about fluorescence to microspectrometer USB4000 (spectral range—350–1000 nm, FWHM~2 nm, Ocean Optics Inc., Fla, USA). A computer was used to control the spectrometric system and to store and display the data measured using specialized software Spectra Suite (Ocean Optics Inc.). Usage of the standard light guide of the endoscope for delivery of excitation light is beneficial due to the same geometry of illumination—view angle and illuminated area are preserved as for the white-light illumination mode. However, the optics of the light guide was not optimized for the short wavelength range and strong losses appeared in this case, therefore 2D visualization of the lesions obtained was not optimal for clinical observation needs [13].

In the second variant, excitation source was light emitting diode illuminator—AFS-405 (Polironik Ltd., Moscow, Russia) on 405 nm with 25 mW output power on the end of the fiber tip. Numerical aperture of the fiber was lower than that

one of light guide of the endoscope itself, and about 60% of the view area was illuminated in this case, reducing the field of view for the clinicians. However, in this case excitation light intensity was not faded by delivery optics, and bright 2D video visualization was achieved.

In the both cases, spectroscopic 1D measurements were with very good quality (high value of the signal-to-noise ratio), due to the significant sensitivity of the microspectrometer applied.

In the study, delta-aminolevulinic acid/protoporphyrin IX (“ALASENS,” NIOPIK JSCo, Russia) was used as fluorescent marker for dysplasia and tumor detection in esophagus and stomach. The δ -ALA is administered per os six hours before measurements at dose 20 mg/kg weight, according to clinical experience in gastrointestinal diagnostic applications of δ -ALA/PpIX fluorescence [4, 17].

Fluorescence diagnosis of esophageal and stomach lesions was made during standard endoscopic examinations of the patients in Gastroenterology Department of University Hospital “Queen Giovanna.” Twelve esophageal tumors and fifteen stomach tumors were detected using fluorescence endoscopy. The spectral measurements are made on several anatomic points during endoscopic procedures—on normal mucosa and cancerous sites. In the case of stomach endoscopic observations, spectral data from inflammatory areas were also detected and stored for subsequent analysis. All procedures are developed after local ethical committee approval received for the protocol of exogenous fluorescence diagnostic modality verification.

Five to seven points were measured from every section and averaged spectrum was used for evaluation of their state. The resultant spectrum was smoothed using Savitzky-Golay algorithm to reduce instrumental noise of the spectrometric system used. All results presented from spectral measurements in this paper are normalized with respect to back-scattered excitation signal at 405 nm from the mucosa surface for appropriate comparison of the signals obtained.

Measurements of the fluorescence spectra were made in 1D using spectrometer fibers and 2D visualization, and record of protoporphyrin IX distribution in the mucosa was made using video system of the endoscopic equipment. Up to three biopsy samples are collected from every suspicious area observed during observations of the patients using standard endoscopic biopsy clips and send for histological evaluation. Standard histology of all suspicious areas was used as “gold” standard, for comparison with the results obtained from spectral measurements.

3. RESULTS

The spectral measurements *in vivo* were made on several anatomic points during endoscopic procedures—on normal mucosa and suspicious sites, known from the previous diagnostic evaluation of the exact patient or where some red fluorescence signal was observed during current endoscopic observation. Standard histology applied as a “gold” standard for comparison with the results obtained from spectral measurements, revealed very good correlation between the fluorescence signals detected and histology examination results.

The fluorescence detected from tumor sites has very complex spectral origins. It consists of autofluorescence, fluorescence from exogenous fluorophores, and reabsorption from the chromophores accumulated in the tissue under investigation [1, 7–15, 19].

Spectral features observed during endoscopic investigations could be distinct as the next regions, according to their origin and spectral region appearance, after excitation at 405 nm:

- (i) 450–650 nm region, where tissue autofluorescence is observed;
- (ii) 630–710 nm region, where fluorescence of PpIX is clearly pronounced;
- (iii) 530–580 nm region, where minima in the autofluorescence signal are observed, related to reabsorption of oxy-hemoglobin in this spectral area.

Normal mucosa has bright autofluorescence, related mainly to the emission of coenzymes and protein cross-links [19]. The intensity of autofluorescence in the case of neoplasia rapidly decreases, which could be used as additional indicator of pathology evaluation; see Figures 1(a) and 1(b).

On Figure 1 are presented spectra of normal mucosa and tumor sites for esophagus and stomach for two patients. Standard deviation presented is a result of averaging of the spectra detected from different points of the pathological and normal tissues surface, respectively. In the case of stomach, autofluorescence of normal mucosa was significantly higher than that of tumor, and the contrast observed in green spectral area is usually higher than 3,5:1. For the esophagus fluorescence, this difference is not so strongly pronounced, but the autofluorescence of normal mucosa was also higher for all cases observed.

Such high autofluorescence leads to problems in 2D video-observation of the stomach tumor fluorescence, as the values of the area of the autofluorescence spectrum of normal mucosa for the region >600 nm in comparison with the same region for tumor fluorescence are comparable, and the ratio values between total areas of normal versus tumor spectra in the region 600–800 nm vary from 0.7 to 1.1 for different patients. This effect could not be avoided by application of filter before CCD camera, as the long-pass filter (>600 nm) passed both signals—from normal mucosa autofluorescence and from exogenous PpIX tumor fluorescence.

For both anatomic areas, esophagus and stomach, the same procedure was applied, 20 mg/kg 5-ALA oral application 6 hours before endoscopic observations. However, we received relatively big deviations of the fluorescence intensity of PpIX emission for both localizations for different patients, as in esophagus neoplastic lesions the fluorescence intensity of exogenous fluorophore was higher as a general than that for the stomach cancer sites; see Figures 2(a) and 2(b). On Figure 2 schematically are presented two endmost cases—of the highest signal detected from tumor—“Tumor 1” and the lowest signal detected from tumor—“Tumor 2” for both localizations—esophagus and stomach. All spectra are normalized with respect to the back-scattered

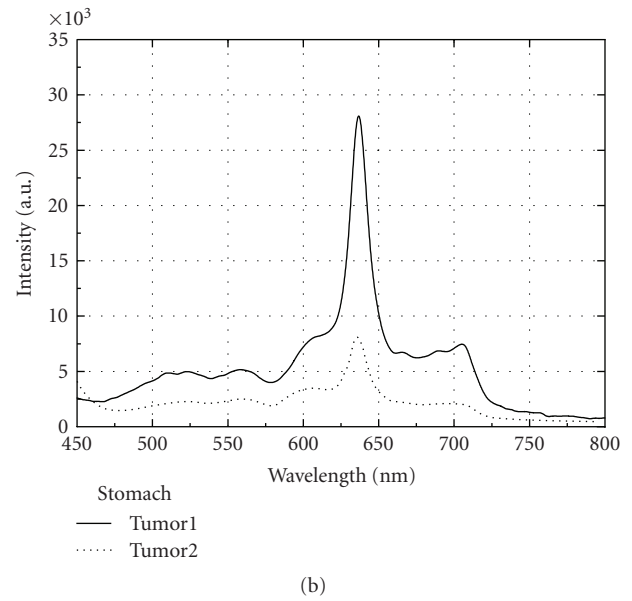
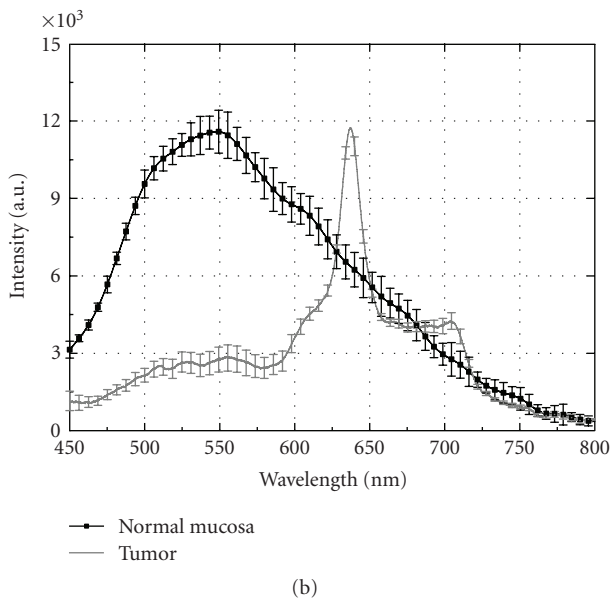
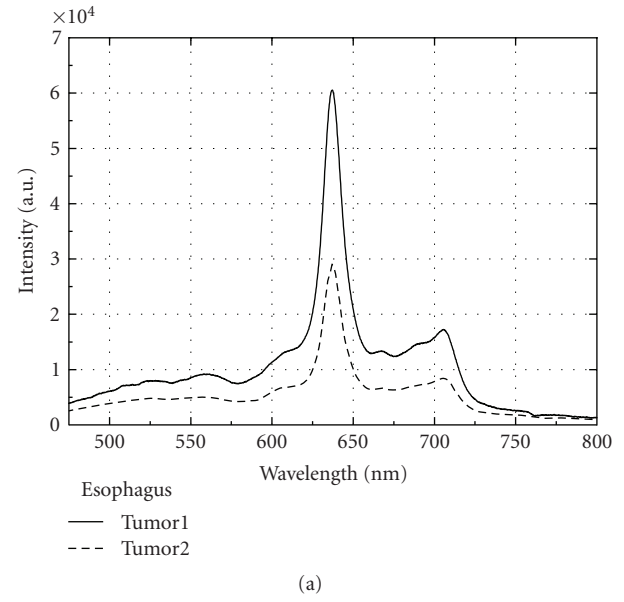
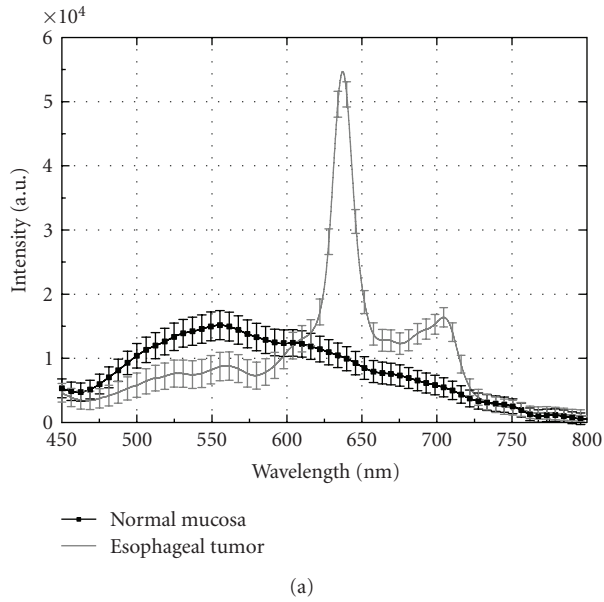


FIGURE 1: Fluorescence spectra of normal mucosa and tumor of patient with (a) esophageal carcinoma and patient with (b) stomach carcinoma at 405 nm excitation. Spectra are presented with their standard deviation, resulting of calculation of the mean value from the spectra detected from one section.

FIGURE 2: Fluorescence spectra of the lesions of two different patients with (a) esophageal tumors and two patients with (b) stomach tumors at 405 nm excitation. Spectra presented outlying cases of the highest (“Tumor 1”) and the lowest (“Tumor 2”) signals received from tumors in both localizations in different patients.

excitation signal at 405 nm. In general, stomach tumor PpIX fluorescence is about two times lower than that from esophagus neoplastic areas. It could be related to differences in the time of accumulation or the specific accumulation in both anatomic areas.

When inflammatory areas occurred in the organ under investigation, red fluorescence is also observed, which could give false-positive results for tumor determination, during observation in video channel of the endoscope. This fluorescence is observed due to the accumulation of PpIX in the both tumor and inflammatory areas. These signals could be

distinguished when 1D measurements of the inflammation are carried out; see Figure 3. The contrast between the fluorescent signals at 635 nm between tumor regions and inflammations observed in all patients, where such comparison was possible, usually is higher than two. In such way, we could be sure in general that by using this detection approach one could distinguish inflammation from tumor site, and moreover, could distinguish inflammatory areas from normal mucosa.

However, the fluorescent intensities of the maximum at 635 nm of inflammatory area detected from stomach

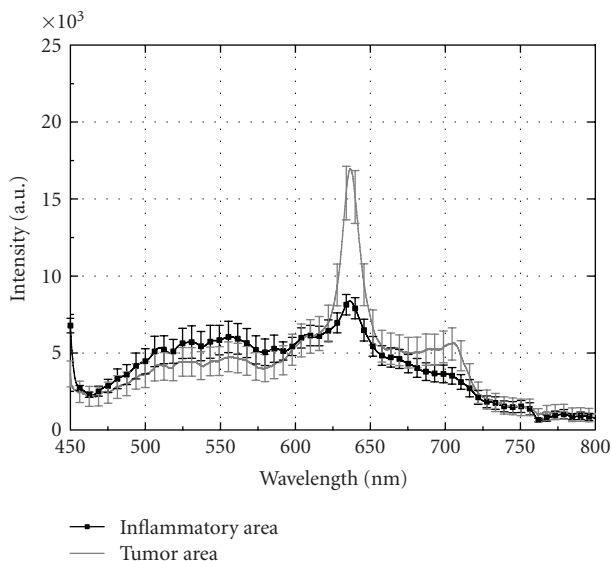


FIGURE 3: Fluorescence spectra of stomach inflammation and tumor of one patient, using excitation at 405 nm. Spectra are presented with their standard deviation, received after averaging of several point measurements in the respective abnormal mucosa areas.

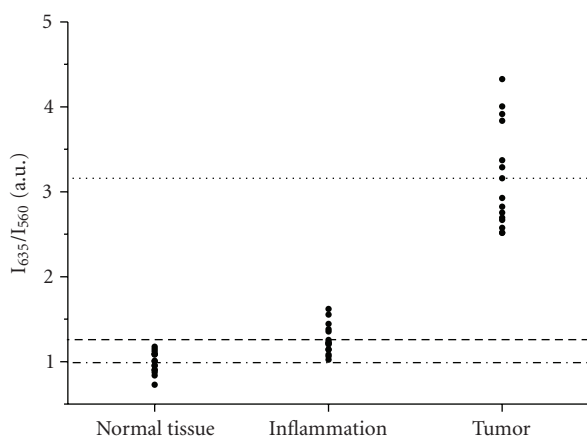


FIGURE 4: Dimensionless ratio (\bullet) $R = I_{635}/I_{560}$ calculated for all cases detected from normal mucosa, inflammation, and tumor of stomach. Lines represent the mean values of this ratio calculated.

wall are close to the lowest signals received from tumors (see Figure 2(b)). Therefore, an additional criterion could be applied for better differentiation of inflammation from tumor. We used for these goals a dimensionless ratio $R = I_{635}/I_{560}$. In such way, we received excellent differentiation of malignancies from benign and normal tissues of the stomach with significant gap between values corresponded; see Figure 4.

On Figure 4 are presented values of the dimensionless ratio of the all cases detected with tumors and inflammations in stomach wall, compared with normal mucosa values. Using this simple algorithm, very good differentiation tumor/inflammation is obtained that could be applied for clinical practice needs.

Moreover, similar approaches are proposed by other research groups for differentiation of normal and cancerous sites in bronchi and lungs. Using green and red band-pass filters, two complimentary images are received and ratio between them is calculated to receive more contrast image and to improve sensitivity and specificity of the fluorescent endoscopy approach [8, 20, 21].

4. DISCUSSION

Gastrointestinal tumors have major place in the statistics of newly developed cancers every year, and usually the tumors are detected on advanced III and IV stages, where perspectives for the patients are not very optimistic. Up to now, white light endoscopy is the main method in detection of gastrointestinal tumors. White-light endoscopy is well-established and wide used modality. However, despite the many technological advances that have been occurred, conventional white-light endoscopy is suboptimal and usually detects lesions, which already have symptoms of obstruction, bleeding and pain, related to tumor growth. Misdiagnoses, related to difficulties in differentiation of inflammatory from initial stage adenocarcinoma, also have negative effect on the diagnostic accuracy [1]. Only experienced gastroenterologists with long practice in endoscopy observations could find slight initial changes to dysplastic and neoplastic stages of esophageal, stomach or colon mucosa.

In gastroenterology, several optical methods are applied recently, such as optical coherent tomography [7], chromoendoscopy, confocal fluorescent microscopy [10], Raman spectroscopy [22], reflectance spectroscopy [11], and laser- and light-induced fluorescence spectroscopy [4, 15–17]. Combination of optical techniques (laser autofluorescence and diffuse reflectance) is also applied to increase the values of sensitivity and specificity of diagnostic procedure up to 93% and 100%, respectively [11].

Exogenous fluorescence spectroscopy is suggested to be very promising modality for early diagnosis of gastrointestinal tumors, and one of the most widely applied compound is delta-aminolevulinic acid/protoporphyrin IX [9, 16, 17]. 5-ALA is a natural precursor of heme, which induces the formation of endogenous PpIX. The administration of exogenous 5-ALA results in the accumulation of PpIX in tissue due to feedback inhibition of the final step of the heme biosynthetic cycle. Enzymatic differences in dysplastic tissue (e.g., decreased ferrochelatase activity) can lead to an increase in PpIX fluorescence in the tumor cells. Fluorescence spectroscopy of gastrointestinal tract is not yet in routine clinical use, but increasingly compelling data in patients will likely to lead to its introduction to the diagnostic practice in near future.

In the current study are presented data from exogenous fluorescence spectroscopy of esophageal and stomach tumors in vivo after oral application of 20 mg/kg 5-ALA six hours before spectroscopic measurements and video visualization of the patients using excitation at 405 nm. The spectra received in 1D point spectroscopic measurements consist from three fundamental compounds—autofluorescence of endogenous fluorophores, fluorescence of exogenous

protoporphyrin IX, and reabsorption of their emission from the hemoglobin. Video 2D observation which is the most user—friendly tool for the needs of anatomically connected visualization of the pathology from the clinicians is not presented, as due to high level of autofluorescence of the gastrointestinal wall in the red spectral region, it is not representative enough. Similar observations were found from other investigators for detection of esophageal carcinoma lesions [23]. This problem could be solved by change of excitation wavelength applied and this task is in a process of solving in our further investigations using longer wavelengths for excitation of PpIX (e.g., its peaks of absorption at 509 nm, 544 nm, or 584 nm), where autofluorescence is not so strong factor, as well as back scattered excitation light from the mucosal surface does not lie in the spectral region of PpIX fluorescence itself.

In the case of normal mucosa, the hemoglobin reabsorption is not strongly pronounced. The mucosal autofluorescence is observed in the region of 450–700 nm and could be related to signals from protein cross-links, coenzymes, and phospholipids, using excitation at 405 nm [4, 19, 24–26]. The lack of fluorescence peaks at 636 nm and 704 nm for normal mucosa is an indication for highly selective accumulation of 5-ALA/PpIX only in abnormal sites and gives high contrast when lesion borders are determined. In the cases of advanced tumor progress, where necrosis appears, a lack of autofluorescence or exogenous signal is noticed, which visually is observed as a dark spot in the center of tumor lesion.

In the case of inflammation and tumor very strong minima are presented in the spectra at 545 and 573 nm, related to oxy-hemoglobin reabsorption of the autofluorescence signals from these areas. These strongly pronounced minima in the green spectral region could be used as additional indication of abnormality of the tissue investigated.

Dimensionless ratio at two wavelengths 560 nm and 635 nm is proposed to be used for better differentiation of tumors from inflammatory areas. This ratio allows receiving of 100% selective discrimination of tumors versus mucosal inflammation. However, additional comparison must be applied when dysplasia is evaluated. On this stage, only three cases of dysplasia are evaluated during clinical observations and their ratio' values lie between values of inflammations' and tumors' spectral ratios, namely, values of R for detected spectra of inflammation are between $1 < R < 1,6$, of dysplasia— $1,5 < R < 2,3$, and $2,5 < R < 4,4$ for the tumors' fluorescence spectra measured.

5. CONCLUSIONS

Advances in spectroscopic instruments will improve imaging's role as a facilitator of research translation. Results received in our study could serve for development of novel tools for quantifying in vivo tumor growth and origin and for accelerating the transition from preclinical studies to early clinical trials and to routine diagnostic practice. Fluorescent spectroscopy and imaging will help for further understanding of gastrointestinal tract tumors and to improve cancer patients' lives.

ACKNOWLEDGMENTS

This work was supported by the Bulgarian Ministry of Education and Science under Grant VU-L-01/05 "Optical biopsy of dysplasia and tumors in upper part of gastrointestinal tract."

REFERENCES

- [1] R. S. DaCosta, B. C. Wilson, and N. E. Marcon, "Photodiagnostic techniques for the endoscopic detection of premalignant gastrointestinal lesions," *Digestive Endoscopy*, vol. 15, no. 3, pp. 153–173, 2003.
- [2] T. Gabrecht, B. Lovisa, F. Borle, and G. Wagnieres, "Design of an endoscopic optical referent to be used for autofluorescence bronchoscopy with a commercially available diagnostic autofluorescence endoscopy (DAFE) system," *Physics in Medicine and Biology*, vol. 52, pp. 163–171, 2007.
- [3] "Xillix and Olympus Finalize Distribution and Development Agreement—Product Launch Scheduled for Early 1997," *Business Wire*, January 1997.
- [4] V. Chissov, V. Sokolov, N. Bulgakova-Zharkova, and E. Filonenko, "Fluorescence endoscopy, dermoscopy and spectrophotometry for diagnosis of malignant tumors," *Russian Biotherapeutic Journal*, vol. 4, pp. 45–56, 2003.
- [5] "World's First Auto Fluorescent Endoscope, medGadget—Internet Journal of Emerging Medical Technologies," April 2007, <http://www.medgadget.com/>.
- [6] G. V. Papayan and U. Kang, "Fluorescence endoscopic video system," *Journal of Optical Technology*, vol. 73, no. 10, pp. 739–743, 2006.
- [7] A. R. Tumlinson, L. P. Hariri, U. Utzinger, and J. K. Barton, "Miniature endoscope for simultaneous optical coherence tomography and laser-induced fluorescence measurement," *Applied Optics*, vol. 43, no. 1, pp. 113–121, 2004.
- [8] V. V. Sokolov, E. V. Filonenko, L. V. Telegina, N. N. Boulgakova, and V. V. Smirnov, "Combination of fluorescence imaging and local spectrophotometry in fluorescence diagnostics of early cancer of larynx and bronchi," *Quantum Electronics*, vol. 32, no. 11, pp. 963–969, 2002.
- [9] S. Svanberg, "Environmental and medical applications of photonic interactions," *Physica Scripta*, vol. T110, pp. 39–50, 2004.
- [10] R. DaCosta and N. Marcon, "Neue dimensionen in der bildgebung: bioendoskopie," *Endo Heute*, vol. 16, no. 2, pp. 75–90, 2003.
- [11] I. Georgakoudi, B. C. Jacobson, J. Van Dam, et al., "Fluorescence, reflectance, and light-scattering spectroscopy for evaluating dysplasia in patients with Barrett's esophagus," *Gastroenterology*, vol. 120, no. 7, pp. 1620–1629, 2001.
- [12] R. L. Probst and J. Gahlen, "Fluorescence diagnosis of colorectal neoplasms: a review of clinical applications," *International Journal of Colorectal Disease*, vol. 17, no. 1, pp. 1–10, 2002.
- [13] E. G. Borisova, B. G. Vladimirov, I. G. Angelov, and L. A. Avramov, "Fluorescence spectroscopy of gastrointestinal tumors using δ -ALA," in *14th International School on Quantum Electronics: Laser Physics and Applications*, vol. 6604 of *Proceedings of SPIE*, pp. 1–5, Sunny Beach, Bulgaria, September 2006.
- [14] C. Ell, "Improving endoscopic resolution and sampling: fluorescence techniques," *Gut*, vol. 52, supplement 4, pp. 30–33, 2003.
- [15] M.-A. E. J. Ortner, B. Ebert, E. Hein, et al., "Time gated fluorescence spectroscopy in Barrett's oesophagus," *Gut*, vol. 52, no. 1, pp. 28–33, 2003.

- [16] S. Brand, T. D. Wang, K. T. Schomacker, et al., "Detection of high-grade dysplasia in Barrett's esophagus by spectroscopy measurement of 5-aminolevulinic acid-induced protoporphyrin IX fluorescence," *Gastrointestinal Endoscopy*, vol. 56, no. 4, pp. 479–487, 2002.
- [17] E. Endlicher, R. Knuechel, T. Hauser, R. Szeimies, J. Scholmerich, and H. Messmann, "Endoscopic fluorescence detection of low and high grade dysplasia in Barrett's oesophagus using systemic or local 5-aminolevulinic acid sensitization," *Gut*, vol. 48, no. 3, pp. 314–319, 2001.
- [18] H. Messmann, E. Endlicher, G. Freunek, P. Rummele, J. Scholmerich, and R. Knuchel, "Fluorescence endoscopy for the detection of low and high grade dysplasia in ulcerative colitis using systemic or local 5-aminolevulinic acid sensitization," *Gut*, vol. 52, no. 7, pp. 1003–1007, 2003.
- [19] L. M. Song and K. K. Wang, "Optical detection and eradication of dysplastic Barrett's esophagus," *Technology in Cancer Research & Treatment*, vol. 2, no. 4, pp. 289–302, 2003.
- [20] D. Goujon, M. Zellweger, H. van den Bergh, and G. Wagnières, "Autofluorescence imaging in the tracheo-bronchial tree," *Photodynamics News*, vol. 3, no. 3, pp. 11–14, 2000.
- [21] V. Sokolov, V. Chissov, E. Filonenko, et al., "Fluorescence diagnostics of early central cancer of the lung," *Pulmonology*, vol. 1, pp. 107–116, 2005.
- [22] X.-L. Yan, R.-X. Dong, L. Zhang, X.-J. Zhang, and Z.-W. Zhang, "Raman spectra of single cell from gastrointestinal cancer patients," *World Journal of Gastroenterology*, vol. 11, no. 21, pp. 3290–3292, 2005.
- [23] M.-A. E. J. Ortner, K. Zumbusch, J. Liebetrueth, et al., "Is topical δ -aminolevulinic acid adequate for photodynamic therapy in Barrett's esophagus? A pilot study," *Endoscopy*, vol. 34, no. 8, pp. 611–616, 2002.
- [24] S. Andersson-Engels, C. A. Klinteberg, K. Svanberg, and S. Svanberg, "In vivo fluorescence imaging for tissue diagnostics," *Physics in Medicine and Biology*, vol. 42, no. 5, pp. 815–824, 1997.
- [25] P. Wilder-Smith, T. Krasieva, W.-G. Jung, et al., "Noninvasive imaging of oral premalignancy and malignancy," *Journal of Biomedical Optics*, vol. 10, no. 5, Article ID 051601, 8 pages, 2005.
- [26] G. Zonios, R. Cotheren, J. Crawford, et al., "Spectral pathology," in *Advances in Optical Biopsy and Optical Mammography*, R. Alfano, Ed., vol. 838, pp. 108–115, Annals of the New York Academy of Sciences, New York, NY, USA, 1998.