

Clinical Report

FP Core Carrier Technique: Thermoplasticized Gutta-percha Root Canal Obturation Technique Using Polypropylene Core

Hiroshi Kato and Kan-Ichi Nakagawa

*Department of Endodontics and Clinical Cariology, Tokyo Dental College,
1-2-2 Masago, Mihama-ku, Chiba 261-8502, Japan*

Received 17 February, 2010/Accepted for publication 28 May, 2010

Abstract

Core carrier techniques are unique among the various root canal filling techniques for delivering and compacting gutta-percha in the prepared root canal system. Thermafil (TF), considered the major core carrier device, is provided as an obturator consisting of a master core coated with thermoplasticized gutta-percha. We have devised a thermoplasticized gutta-percha filling technique using a polypropylene core, FlexPoint® NEO (FP), which was developed as a canal filling material that can be sterilized in an autoclave. Therefore, FP can be coated onto thermoplasticized gutta-percha and inserted into the prepared canal as a core carrier. The FP core carrier technique offers many advantages over the TF system: the core can be tested in the root canal and verified radiographically; the core can be adjusted to fit and surplus material easily removed; furthermore the core can be easily removed for retreatment. The clinical procedure of the FP core carrier technique is simple, and similar that with the TF system. Thermoplasticized gutta-percha in a syringe is heated in an oven and extruded onto the FP core carrier after a trial insertion. The FP core carrier is inserted into the root canal to the working length. Excess FP is then removed with a red-hot plastic instrument at the orifice of the root canal. The FP core carrier technique incorporates the clinical advantages of the existing TF system while minimizing the disadvantages. Hence the FP core carrier technique is very useful in clinical practice. This paper describes the FP core carrier technique as a new core based method.

Key words: Root canal filling—Obturation technique—Gutta-percha—Polypropylene point—Core carrier

Introduction

Root canal filling is the final step in endodontic treatment. Complete obturation of the prepared root canal system with filling materials and creation of a hermetic apical

seal are the goals of successful endodontic treatment^{1,4,8,17}.

Most root canal filling methods use gutta-percha in the form of a solid or softened core. There are various techniques for delivering and compacting gutta-percha in root canals.

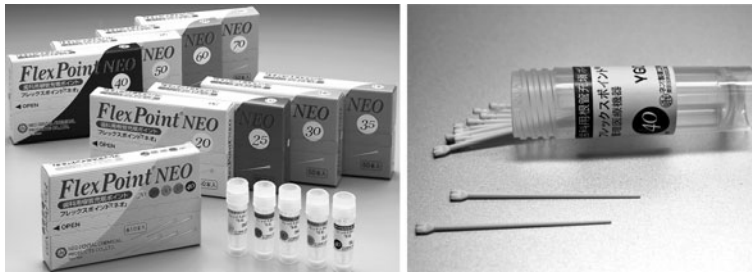

Fig. 1 FlexPoint® NEO (FP): Polypropylene obturation points.




Fig. 2 Outline of FP core carrier technique: (a) Thermoplasticized gutta-percha syringes (ObturationGutta NT) are loaded into Hot Spot oven. (b) Sealer is applied to root canal orifice to a depth of a few millimetres. (c) FP is inserted into gutta-percha syringe. (d) FP coated with thermoplasticized gutta-percha. (e) FP core carrier is inserted to the full working length of the root canal.

In addition to conventional root canal filling techniques such as the lateral condensation, many thermoplasticized gutta-percha filling techniques have been developed aiming at closer, 3-dimensional obturation^{8,17}.

The core carrier technique is a unique method for delivering and compacting gutta-percha^{1,8,9}. Thermafil (Dentsply/Tulsa Dental, Tulsa, USA), considered to be a major core carrier device⁸, is provided as an obturator combining a master core with thermoplasticized gutta-percha. Thermafil (TF) heated in a special oven is inserted into the root canal to the correct working length. Advantages of the core carrier technique include ease and speed of placement and the potential for the plasticized gutta-percha to flow into canal irregularities^{2,3,6,7,11–13,18}.

We have devised a new thermoplasticized

gutta-percha root canal filling technique using a polypropylene obturation point, FlexPoint® NEO (Neo Dental Chemical Products Co., Tokyo, Japan, Fig. 1), as the core carrier¹⁰.

FlexPoint® NEO (FP) was developed as a sterilizable filling material¹⁴, and is made of polypropylene (30% w/w) with barium sulfate (70% w/w) added as the contrast medium¹⁴. It can withstand temperatures of up to 148.7°C, allowing it to be sterilized in an autoclave while retaining its original form and elasticity¹⁴.

Therefore, FP can be coated onto thermoplasticized gutta-percha and inserted into the root canal as a core carrier (Fig. 2). The FP core carrier technique offers the clinical advantages of the existing TF system while reducing the disadvantages. This paper describes the FP core carrier technique as a new core-based method.

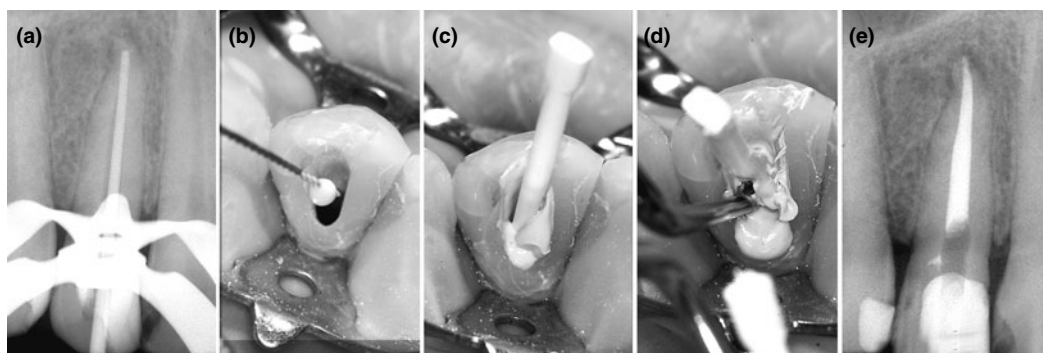


Fig. 3 Clinical procedure for FP core carrier technique: (a) Fit of FP core is verified radiographically. (b) Sealer is placed in canal orifice with canal instrument. (c) FP core carrier is inserted to full working length. (d) Hot instrument is used to remove excess FP core and gutta-percha. (e) Post-operative radiograph.

Methods

1. Filling materials

The following materials are used in this technique:

- 1) Polypropylene point: "FlexPoint® NEO"
- 2) Gutta-percha syringe: "ObturationGutta NT" (Toyo Chemical, Tokyo, Japan)
- 3) Root canal sealer: "Sealapex" (SybronEndo, Orange, USA)

ObturationGutta NT consists of a syringe containing β -phase gutta-percha which is heated in a gutta-percha oven (Hot Spot/Aceptico, Woodinville, USA, Fig. 2-a) at 80°C for 5 min.

2. Root canal preparation

As with all obturation methods, the root canal is ready to be filled when the canal is cleaned and shaped to the optimum size^{4,6,17}. It should be so shaped that a continuously tapering funnel is created with the narrowest diameter at the dentin-cementum junction^{1,9}. In the FP core-carrier technique, the apical preparation size must be over ISO No. 40 to allow the gutta-percha coated FP core to reach the root canal terminus¹⁰.

After canal irrigation, the cleaned and shaped canal is dried completely with paper points and suction in preparation for obturation.

3. Filling procedure

The outline of the filling procedure and clinical procedure of the FP core carrier technique are shown in Figs. 2 and 3. The filling procedure is performed according to the following 5 steps.

1) Preparation of solid core

The FP for the core carrier should be selected to match the size of the last instrument used at the apical terminus. The FP can be inserted to full working length, and upon removal exhibits apical tug-back by tactile sensation. If an FP of size equal to the apical preparation size is not supplied, the tip of the FP core can be cut to fit the apical terminus. It is necessary to correct the FP tip size, so that the FP may fit the apical preparation conditions, as all sizes of ISO standards are not produced. After trial and fitting of FP core, its position must be confirmed radiographically.

2) Sealer placement

A very thin coat of sealer is placed on the coronal third of the canal wall (Fig. 2-b, 3-b). It is important to use only small amount of the sealer.

3) Coating FP with softened gutta-percha (Fig. 2-c, d)

The FP core is prepared for use by carefully coating it with the softened gutta-percha from the ObturationGutta NT syringe which has been heated in the Hot Spot oven. The correct

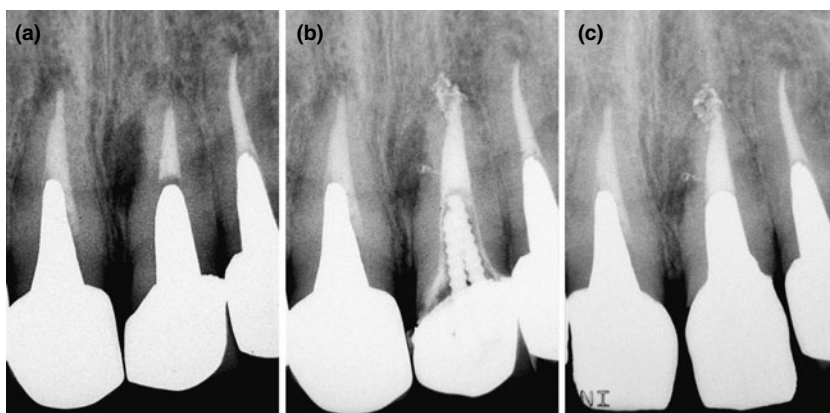


Fig. 4 Case 1: (a) Preoperative radiograph of maxillary central incisor showing lateral and apical radiolucencies. (b) Radiograph taken immediately after treatment showing obturation of lateral canal and apical branches which caused endodontic lesions. (c) Follow-up radiograph 2 months after treatment showing significant bone healing.

size FP core is inserted into the syringe tip, and the plunger pushed immediately, covering the FP carrier in thermoplasticized gutta-percha. 4) Obturation (Fig. 2-e, 3-c)

The FP carrier is inserted slowly to full working length without rotation (to avoid exfoliation of the gutta-percha from the FP surface). The softened gutta-percha around the FP is compacted apically with root canal pluggers. In summary, the FP performs as a “carrier” (transferring thermoplasticized gutta-percha to the root canal) and as a “core” for root canal obturation. Insertion of the FP accomplishes obturation by pushing thermoplasticized gutta-percha into the canal irregularities.

5) Remove surplus filling materials (Fig. 3-d)

The final mass of FP and gutta-percha is severed at 1–2 mm above the canal orifice with a red-hot instrument to below the free gingival level, and final vertical compaction is performed with a large plugger. Longneck round engine burs, such as Muller burs, can be used to clean the surface of the FP core. Therma-cut (Dentsply) burs (smooth, round-headed burs for cutting the thermoplastic obturator) can be used in the FP core carrier technique. After the intraorifice barrier and coronal temporary sealing material are placed, a final radiograph is taken for verification (Fig. 3-e).

Clinical Cases

Case 1: A 43-year-old man was referred to our department by a general practitioner Tokyo Dental College, Chiba Hospital for evaluation and root canal retreatment. The patient’s upper left central incisor showed a periradicular radiolucency and external root resorption (Fig. 4-a). The presence of a lateral branch was suspected since there was a lateral lesion. The canal was obturated using the FP core carrier technique at the third visit. In the immediate postoperative radiograph (Fig. 4-b), the lateral and apical branches which had caused the lesion were confirmed as being obturated. After 2 months follow-up, prosthetic treatment was completed, and the periradicular lesion showed good evidence of bone healing (Fig. 4-c). We suggest that the initial treatment failed to seal the lateral branch, and use of the FP core carrier technique during retreatment enabled this branch to be sealed.

Case 2: A 52-year-old woman was referred to our department by a general practitioner for root canal treatment of her lower left first molar because of a fistula that did not heal. A large radiolucent lesion appeared to involve the first and second molar (Fig. 5-a). Clinical examination revealed pulpal necrosis of the

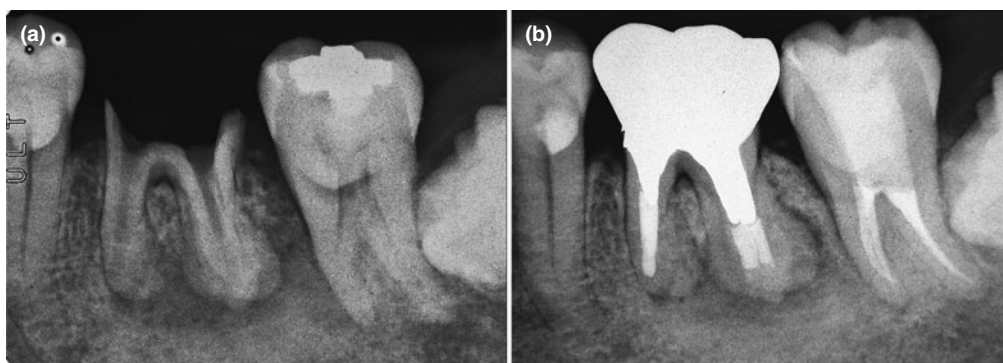


Fig. 5 Case 2: (a) Preoperative radiograph of lower left first and second molars showing contiguous apical bone lesions. (b) Radiograph taken at recall 2 years later showing reduction in size of lesions.

lower left second molar with chronic periradicular periodontitis caused by a cervical carious lesion on the lingual gingival margin. The canals of the lower left first molar were instrumented to size 90 with excessive instrumentation beyond the apical foramen, and the canals of the lower left second molar were narrow. Root canal treatment was commenced, and following correct root canal preparation, the FP core carrier technique was used to obturate the root canals of both molars. A radiograph after 2 years shows almost complete healing of the periapical lesion (Fig. 5-b). Although the open apex makes retention of the filling material in the canal more difficult, canal obturation with good length control led to stable apical healing.

Case 3: A 24-year-old man was referred to our department with the chief complaint of a fractured upper right central incisor with a porcelain veneer crown. Root canal filling with the FP core carrier technique was undertaken after a routine retreatment procedure; however, the postoperative radiograph indicated that the filling material was extruded beyond the apical foramen (Fig. 6-a). The FP core carrier and the GP were easily removed as a mass using an H-file (Fig. 6-b, c). Over-extension of the core was caused by an error in the core size adjustment; therefore, the apical foramen was gauged using a hand K-file. The apical width was found to be equivalent to a size 100 K-file. Replacement

of the canal filling was completed with an FP core which was adjusted to fit the apical stop (Fig. 5-d).

Discussion

The concept of a root canal filling technique involving thermoplasticized gutta-percha with a core-carrier was introduced by Johnson in 1978⁹. Recently, these techniques have been recognized as offering many advantages: notably, that they are quick and relatively easy to perform^{1,5,7,8,17}. Core carrier techniques provide a seal equivalent to that gained using a lateral condensation technique^{7,18}. In clinical cases treated with the FP core carrier technique, we found that it was extremely effective in filling the root canal system in a short operation time. Excellent filling results were observed in our preliminary fundamental research¹⁰.

Ohne and Yamazaki¹⁴ developed a polypropylene obturating point which could be sterilized for use in a single-cone technique. Toda *et al.*¹⁶ investigated the outcome of endodontically treated teeth filled using a single-cone technique (using the FP core and sealer) and a multiple-cone technique (using the FP core, sealer and accessory gutta-percha points). They reported a success rate of approximately 93% for pulpectomy and infected root canal treatment; however, all the failed cases used

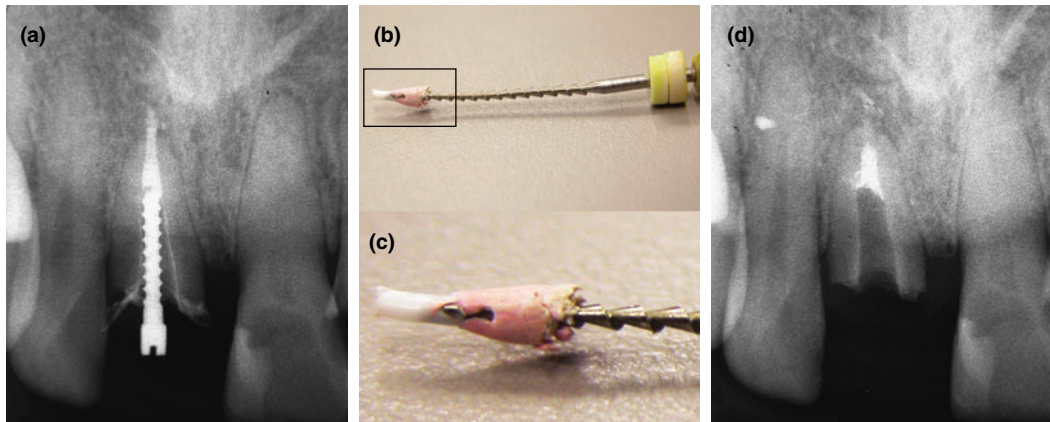


Fig. 6 Case 3: (a) Radiograph taken after upper right central incisor underwent obturation with FP core carrier technique, showing extrusion of filling material beyond apical foramen. (b, c) FP and gutta-percha after removal with H-file. (d) Radiograph taken after root canal was refilled using adjusted FP core to fit apical stop size.




Fig. 7 Representative photograph of cross-section of root canal filled using FP core carrier technique¹⁰.
FP: FlexPoint NEO, GP: Gutta-percha, *: Lateral canal.

the FP single cone technique.

The single-cone technique may be used when the canal walls are reasonably parallel and the primary cone fits snugly in the apical third of the canal; the sealing of the canal is therefore completely accomplished by the sealer^{6,8,17,18}.

In comparison to the single-cone technique, almost all core carrier techniques provided a more homogeneous obturation with a relatively small amount of sealer. Hence, it is thought that the core carrier technique is more effective than the single point tech-

nique for the application of the FP to the root canal.

The disadvantages of the TF core carrier technique include the inconvenience of post space creation, and difficulty in removing the core material for retreatment^{6,15,17}. However, these problems are resolved in the FP core carrier technique. Postoperative canal filling with this technique can be achieved using conventional drills for post space creation under dry conditions (Figs. 4–6). The core material can be removed easily and safely using H-files (Fig. 6).

Potential problems include stripping the gutta-percha from the core carrier^{6,17}. However, during our clinical practice using the FP core carrier technique, we did not experience this problem. We found that the incidence of voids in cross-sectional observation of root canals filled with the FP core carrier technique was less than 1%, confirming a very low incidence of stripping of the gutta-percha (Fig. 7)¹⁰.

Cantatore and Johnson¹⁾ enumerated the disadvantages of the Thermafil technique, stating that particular attention was required in cases with very long or short canals, confluent canals and canals with bifurcations or trifurcations in the middle third. If a hollow space occurs after vertical compaction of the gutta-percha around the FP core, such as in cases with long oval- or ribbon-shaped canals, the space can be filled using the hybrid method⁹⁾ (a thermomechanical compaction technique using an engine operated compactor coated with softened gutta-percha in an ObturationGutta NT syringe). A gutta-percha injection method device such as the Obtura II (Obtura-Spartan) can also be used. The FP core carrier technique can deal with most root canal anatomical anomalies by using the techniques mentioned.

Conclusion

We have devised a new thermoplasticized gutta-percha root canal filling technique using a polypropylene obturation point (FlexPoint[®] NEO) as the core carrier. The FP core carrier technique offers many advantages by using a custom-made core: the ability to adapt the core material to the shape of apical terminus, control of the core length by radiographic verification, a quick and easy filling operation, excellent 3-dimensional root canal filling by gutta-percha and easy removal for retreatment. We therefore consider that the FP core carrier technique is superior to other core-based obturation methods.

References

- 1) Cantatore GC, Johnson WB (2005) The Thermafil system, Endodontics, Castellucci A, 2nd ed., pp. 701–729, il Tridente, Firenze.
- 2) De-Deus G, Reis C, Beznos D, de Abranches AM, Coutinho-Filho T, Paciornik S (2008) Limited ability of three commonly used thermoplasticized gutta-percha techniques in filling oval-shaped canals. J Endod 34:1401–1405.
- 3) Gençoğlu N, Garip Y, Baş M, Samani S (2002) Comparison of different gutta-percha root filling techniques: Thermafil, Quick-fill, System B, and lateral condensation. Oral Surg Oral Med Oral Pathol Oral Radiol Endod 93:333–336.
- 4) Glickman GN, Walton RE (2009) Obturation, Endodontics; Principles and Practice, Torabineejad M, Walton RE, 4th ed., pp. 298–321, Elsevier, St. Louis.
- 5) Gound TG, Sather JP, Kong TS, Makkawy HA, Marx DB (2009) Graduating dental students' ability to produce quality root canal fillings using single- or multiple-cone obturation techniques. J Dent Educ 73:696–705.
- 6) Gutmann JL, Dumsha TC, Lovdahl PE (2006) Problem solving in Endodontics, 4th ed., pp. 204–255, Elsevier, St. Louis.
- 7) Gutmann JL, Saunders WP, Saunders EM, N Nguyen L (1993) An assessment of the plastic Thermafil obturation technique. Part I. Radiographic evaluation of adaptation and placement. Int Endod J 26:173–178.
- 8) Ingle JI, Carl W, Newton CW, West JD, Gutmann JL, Glickman GN, Korzon BH, Martin H (2002) Obturation of the radicular space, Endodontics, Ingle JI, Bakland LK, 5th ed., pp. 598–615, BC Decker, Hamilton.
- 9) Johnson WB (1978) A new gutta-percha technique. J Endod 4:184–188.
- 10) Kato H, Yamaguchi Y, Nakagawa K (2010) Evaluation of a new thermoplasticized gutta-percha obturation techniques using polypropylene core for filling of lateral and main canals. The Shikwa Gakuho 110:331–338. (in Japanese).
- 11) Levitan ME, Himel VT, Luckey JB (2003) The effect of insertion rate on fill length and adaptation of a thermoplasticized gutta-percha technique. J Endod 29:505–508.
- 12) Lipski M (2006) *In vitro* infrared thermographic assessment of root surface temperatures generated by high-temperature thermoplasticized injectable gutta-percha obturation technique. J Endod 32:438–441.
- 13) Lipski M (2004) Root surface temperature rises *in vitro* during root canal obturation with

- thermoplasticized gutta-percha on a carrier or by injection. *J Endod* 30:441–443.
- 14) Ohne M, Yamazaki Y (2005) Effects of auto-claving on dimensional qualities and physical properties (flexural rigidity and brittleness) of newly developed root canal filling point made of polypropylene (FLEX POINT NEO). *Bull Tokyo Dent Coll* 46:27–32.
- 15) Ozawa T, Taha N, Messer HH (2009) A comparison of techniques for obturating oval-shaped root canals. *Dent Mater J* 28:290–294.
- 16) Toda T, Hata G, Murakami S, Shimabukuro Y, Amano Y, Isohata M, Kubota M, Kawashima T, Tokura Y, Ito A, Nakagawa K, Ryuzaki N, Hirai Y (2005) Clinical evaluation of polypropylene cone for root canal filling. *Jpn J Conserv Dent* 48:681–686. (in Japanese)
- 17) Wesselink P (2003) Root filling techniques, *Textbook of Endodontology*, Bergenholtz G, Horsted-Bindslev P, Reit C, 1st ed., pp.286–299, Wiley-Blackwell, London.
- 18) Wolcott J, Himel VT, Powell W, Penney J (1997) Effect of two obturation techniques on the filling of lateral canals and the main canal. *J Endod* 23:632–635.

Reprint requests to:

Dr. Hiroshi Kato
Department of Endodontics and
Clinical Cariology,
Tokyo Dental College,
1-2-2 Masago, Mihama-ku,
Chiba 261-8502, Japan
Tel: +81-43-270-3950
Fax: +81-43-270-3951
E-mail: hirokato@tdc.ac.jp