

# Surgical Management of Two Simultaneously Occurring Epiphrenic Esophageal Diverticula

Marcello Migliore\*, Giuseppa Pulvirenti, Damiano Calvo, Alessandra Criscione, Mariapia Gangemi, Francesco Borrata, Daniela Palumbo

Section of General Thoracic Surgery, Department of Surgery, University of Catania, Catania, Italy.  
Email: \*mmiglior@unict.it

Received August 31<sup>st</sup>, 2012; revised September 30<sup>th</sup>, 2012; accepted October 15<sup>th</sup>, 2012

## ABSTRACT

Among all diverticula of the esophagus, epiphrenic diverticula occur less frequently than those in the pharyngo-esophageal segment. Two simultaneously occurring diverticula in the epiphrenic esophagus are very rarely reported in the English literature. A 52-year-old woman had a 3-year history of troublesome dysphagia, heartburn, chest pain and cough. Initial investigation included a physical examination and a barium swallow, which showed the presence of two diverticula in the epiphrenic esophagus. Esophagoscopy confirmed the presence only of the lower diverticulum. The patient underwent a left thoracotomy, the esophagus was mobilised from the hiatus to the aortic arch. The necks of the diverticula were localised in the posterior wall and between them there was a bridge of circular muscular fibres, which was divided. Diverticulectomy over an intra-esophageal 54 F Maloney dilator was performed. The upper diverticulum was left intact because it disappeared after the bridge of esophageal muscles has been myotomized. A long myotomy was carried out, and a modified Belsey fundoplication was added. The postoperative course was uneventful, and the patient remains well at 10 years with no recurrence of symptoms.

**Keywords:** Esophageal Epiphrenic Diverticulum; Esophageal Myotomy; Belsey Mark IV

## 1. Introduction

Among all diverticula of the esophagus, epiphrenic diverticula (ED) occur less frequently than those in the pharyngo-esophageal segment. They arise in the distal 10-cm of the esophagus and are commonly associated with motility disorder. Diverticulectomy and myotomy is the most accepted surgical treatment, and a nonobstructive antireflux repair is added only in few centres [1]. Recently some Authors advocate the laparoscopic approach [2]. Because the mortality after diverticulectomy and myotomy has been reported as high as 9.1% [3], the management is still today controversial.

The clinical, diagnostic and treatment findings of two simultaneously occurring diverticula in the epiphrenic esophagus have not previously reported in the English literature.

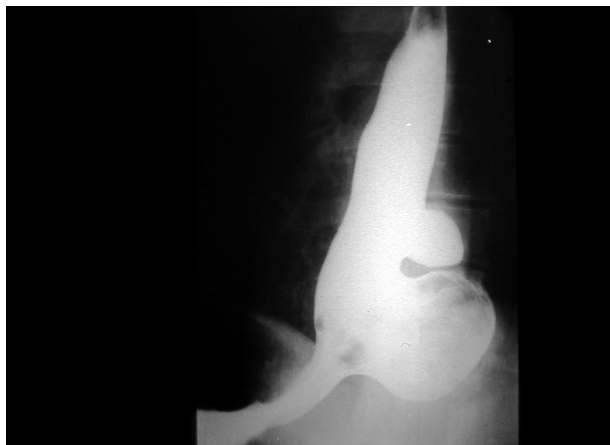## 2. Clinical Summary and Operative Technique

A 52-year-old woman had a 3-year history of troublesome dysphagia, heartburn, chest pain and cough. Initial investigation included a physical examination and a bar-

ium swallow, which showed the presence of two diverticula in the epiphrenic oesophagus (**Figure 1**) and delay of the esophago-gastric transit. Esophagoscopy confirmed the presence only of the lower diverticulum. Manometry demonstrated normal pressure with 50% incomplete relaxation in the upper esophageal sphincter (UES). The esophageal body studies showed simultaneous, high amplitude (350 mmHg) and long duration (10 sec) contractions. The lower esophageal sphincter (LES) was not studied because it was impossible to pass the probe into the stomach. Twenty-four-hours pH-metry was negative for pathological gastro-esophageal reflux (GER).

The patient underwent a left thoracotomy, the esophagus was mobilised from the hiatus to the aortic arch. The necks of the diverticula were localised in the posterior wall. The size of the diverticular neck was 5 cm in the distal diverticulum and 2.5 cm in the more proximal diverticulum, and between them there was a bridge of circular muscular fibres, which was divided. The lower diverticulum was resected using a stapler over an intra-esophageal 54 F Maloney dilator. The upper diverticulum was left intact because it disappeared after the bridge of esophageal muscles has been myotomized. The esophageal muscles were approximated above the diverticulectomy suture and the upper diverticulum. A long

\*Corresponding author.



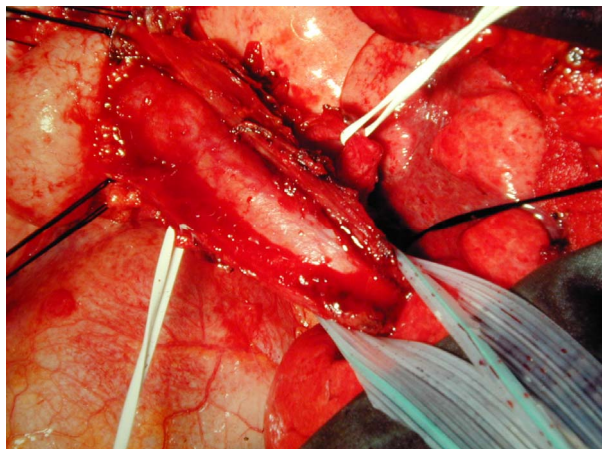
**Figure 1.** pre-operative barium swallow. Preoperative barium swallow demonstrates two simultaneously occurring epiphrenic esophageal diverticula. The proximal diverticulum is situated 1 cm above the upper margin of the neck of the distal diverticulum.

myotomy was carried out 180 degrees away from the suture line, extending onto the stomach for 2 cm. and as far proximally as the arch of the aorta (**Figure 2**). A modified Belsey fundoplication was added. The postoperative course was uneventful. Postoperative barium swallow showed a regular transit of the contrast through the LES and few tertiary contractions in the lower esophagus. Manometry was performed at 6 months and showed the UES and LES with a tone of 56 and 8 mmHg respectively, and the absence of contractions in the distal esophagus. She remains well at 10 years with no recurrence of symptoms.

### 3. Discussion and Conclusion

Although esophageal diverticula can develop at any level of the esophagus they are better classified according to the anatomical location in pharyngoesophageal, mid-esophageal and distal esophagus. Diverticula arising in the pharyngoesophageal segment are known as Zenker diverticula, by far the most common diverticulum of the esophagus. Mid-esophageal diverticula arise in the esophagus in the area of the tracheal bifurcation. Distal esophageal diverticula are known as epiphrenic diverticula. Epiphrenic diverticula have historically been considered as “pulsion” diverticula due to high intraluminal pressures in a short segment of the esophagus (with or without esophageal wall weakness).

The presence of a diverticulum is not an indication for surgery, and the decision whether to operate or not is still controversial. We operate only on patients with severe dysphagia, regurgitation, and contrast retention on esophagography, with risk of aspiration pneumonia, and when the dimension of the diverticulum causes esophageal obstruction and/or compression on adjacent organs



**Figure 2.** Intraoperative view. Long transthoracic esophageal myotomy. The esophageal mucosa is clearly visible.

such as heart and lung. Diverticula must be empty before any operation is started to avoid possible intraoperative aspiration during anaesthesia.

Two are the main reasons for performing the operation in a patient with a double simultaneously occurring epiphrenic esophageal diverticula, the first is that the possibility of a developing carcinoma within the diverticula has been reported in less than 1% of patients whilst esophageal leiomyomas are found in 2% - 6% of patients with ED [4], and the second is because the associated pulmonary complication such as aspiration pneumonia can be severe, and death can occur [1]. The commonest symptom in esophageal diverticulum is dysphagia. Other symptoms are chest pain, weight loss, and regurgitation. Physical examination is necessary to exclude other less common diseases [5]. Cough and arrhythmia though uncommon can also be a presenting symptom [6]. If the double epiphrenic diverticula are suspected during barium screening, the patient should be screened to identify the possible associated achalasia and diffuse esophageal spasm. Endoscopic examination helps to discover the associated esophagitis, but failed, in our patient, to localise the upper diverticulum. This could have been happened because the neck of the proximal diverticulum was only 2.5 cm. As in Zenker’s diverticulum, manometry is necessary to localise the extension of the motility disorder and therefore helps in the planning of surgery [7,8]. Twenty-four-hour pH-metry should always be performed in order to ascertain the presence of pathological GER. We know that in the minimally invasive era VATS or laparoscopic approach can be preferred [9], but in this circumstance because of the unusual presentation in this patient of two simultaneous occurring esophageal diverticula, we preferred the operation through the left chest. Although the lower diverticulum was resected by mean of a stapler, the upper diverticulum was left intact because it was with a neck less than 3 cm, but if the dimen-

sion of the diverticulum were larger we would have performed another diverticulectomy. Every residual circular muscular fibre between the upper and lower diverticula must be accurately divided to avoid recurrences.

The extension of the myotomy is chosen on the basis of the manometric study, and is performed on the opposite site where the diverticulum is excised; in our patient we preferred a long esophagomyotomy extending from the LES to the level of the arch of aorta. Nevertheless, because the cardia was mobilised and the LES included in the myotomy, and in order to avoid postoperative GER, we added a modified Belsey partial fundoplication [1, 10-12]. Antireflux repair after a myotomy is used to avoid post operative gastro-esophageal reflux, and therefore it is justified if myotomy of the LES is performed in patients with ED. Thomas *et al.* have demonstrated that the use of a fundoplication in patients treated for ED decrease the risk of postoperative GERD [13], on the other side D'Journo *et al.* have demonstrated that in patients with ED partial fundoplication did not prevent reflux damage [14].

It is clear that there is no consensus as to whether a fundoplication should be added. If the decision is taken to add a fundoplication a partial type fundoplication such as Dor or Belsey seems mandatory to avoid the risk of obstructive complications putting the suture lines at risk of disruption and leakage.

Postoperatively, the disappearing of clinical symptoms suggested the efficacy of the myotomy, which was confirmed by means of the manometry.

Leak rates have been reported up to 21% in open series and up to 23% in laparoscopic reports. Similarly, mortality rates in open and laparoscopic series have been reported up to 9% and 7%, respectively [9].

The documentation of the associated esophageal motility disorder has been reported uniformly by several authors ranging from 75% to 100%, and has led to believe that a cause-effect relationship exists between esophageal motility disorders and the development of epiphrenic diverticula. This has important implications as it supports a routine selective cardiomyotomy [9] as in Zenker's diverticulum [7].

In conclusion, in the author experience, double esophageal diverticula could be repaired by surgical resection, the preferred option being through an open exposure of the diverticula via a left thoracotomy. The principles of surgical management are the same for a single diverticulum and it is important that surgery follows physiologic principle.

## REFERENCES

- [1] N. K. Altorki, M. Sunagawa and D. B. Skinner, "Thoracic Oesophageal Diverticula. Why Is Operation Necessary?" *The Journal of Thoracic and Cardiovascular Surgery*, Vol. 105, No. 2, 1993, pp. 260-264.
- [2] R. Rosati, U. Fumagalli, S. Bona, L. Bonavina and A. Peracchia, "Diverticulectomy, Myotomy, and Fundoplication through Laparoscopy: A New Option to Treat Epiphrenic Esophageal Diverticula?" *Annals of Surgery*, Vol. 227, No. 2, 1998, pp. 174-178. [doi:10.1097/0000658-199802000-00004](https://doi.org/10.1097/0000658-199802000-00004)
- [3] J. C. Benacci, C. Deschamps, V. F. Trastek, M. S. Allen, R. C. Daly and P. C. Pairolero, "Epiphrenic Diverticulum: Results of Surgical Treatment," *The Annals of Thoracic Surgery*, Vol. 55, No. 5, 1993, pp. 1109-1113. [doi:10.1016/0003-4975\(93\)90016-B](https://doi.org/10.1016/0003-4975(93)90016-B)
- [4] E. Avisar and J. D. Luketich, "Adenocarcinoma in a Mid-Esophageal Diverticulum," *The Annals of Thoracic Surgery*, Vol. 69, No. 1, 2000, pp. 288-289. [doi:10.1016/S0003-4975\(99\)01201-1](https://doi.org/10.1016/S0003-4975(99)01201-1)
- [5] M. Migliore and M. Signorelli, "Episodic Abdominal and Chest Pain in a Young Adult," *JAMA*, Vol. 307, No. 16, 2012, pp. 1746-1747. [doi:10.1001/jama.2012.506](https://doi.org/10.1001/jama.2012.506)
- [6] S. C. Clark, S. A. Norton, K. Jeyasingham and P. D. Ridley, "Oesophageal Epiphrenic Diverticulum: An Unusual Presentation and Review," *Annals of the Royal College of Surgeons of England*, Vol. 77, No. 5, 1995, pp. 342-345.
- [7] M. Migliore, H. Payne and K. Jeyasingham, "Pathophysiologic Basis for Operation of Zenker's Diverticulum," *The Annals of Thoracic Surgery*, Vol. 57, No. 6, 1994, pp. 1616-1620. [doi:10.1016/0003-4975\(94\)90134-1](https://doi.org/10.1016/0003-4975(94)90134-1)
- [8] M. Migliore, "The Upper Esophageal Sphincter and the Cricoesophageal Coordination," *Annali Italiani di Chirurgia*, 2012, in Press. pii: S0003469X12019926
- [9] P. M. Fisichella, M. Pittman and P. C. Kuo, "Laparoscopic Treatment of Epiphrenic Diverticula: Preoperative Evaluation and Surgical Technique. How I Do It," *Journal of Gastrointestinal Surgery*, Vol. 15, No. 10, 2011, pp. 1866-1871. [doi:10.1007/s11605-011-1631-6](https://doi.org/10.1007/s11605-011-1631-6)
- [10] M. Migliore, M. Arcerito, A. Vagliasindi, R. Puleo, F. Basile and G. Deodato, "The Place of Belsey Mark IV Fundoplication in the Era of Laparoscopic Surgery," *European Journal of Cardio-thoracic Surgery*, Vol. 24, No. 4, 2003, pp. 625-630. [doi:10.1016/S1010-7940\(03\)00445-7](https://doi.org/10.1016/S1010-7940(03)00445-7)
- [11] M. Migliore and K. Jeyasingham, "Re-Operations for Failed Anti-Reflux Surgery. Lessons from the Past and Prospects for the Future," *Annali Italiani di Chirurgia*, Vol. 80, No. 4, 2009, pp. 267-274.
- [12] M. Migliore, "Reoperation for Failed Antireflux Surgery," *Multimedia Manual of Cardio-Thoracic Surgery*, Vol. 2011, No. 0311, 2011. [doi:10.1510/mmcts.2009.004226](https://doi.org/10.1510/mmcts.2009.004226)
- [13] M. L. Thomas, A. A. Anthony, B. G. Fosh, J. G. Finch and G. J. Maddern, "Oesophageal Diverticula," *British Journal of Surgery*, Vol. 88, No. 5, 2001, pp. 629-642. [doi:10.1046/j.1365-2168.2001.01733.x](https://doi.org/10.1046/j.1365-2168.2001.01733.x)
- [14] X. B. D'Journo, P. Ferraro, J. Martin, L. Q. Chen and A. Duranceau, "Lower Oesophageal Sphincter Dysfunction Is Part of the Functional Abnormality in Epiphrenic Diverticulum," *British Journal of Surgery*, Vol. 96, No. 8, 2009, pp. 892-900. [doi:10.1002/bjs.6652](https://doi.org/10.1002/bjs.6652)