

Poisoning with acetylcholinesterase inhibitors in dogs: two case reports

E. SREBOČAN¹, G. HRLEC³, Ž. GRABAREVIĆ², J. POMPE-GOTAL¹, R. SABOČANEC²

¹Department of Pharmacology and Toxicology, ²Department of General Pathology and Pathological Morphology, Faculty of Veterinary Medicine, University of Zagreb, Zagreb, Croatia

³Institute for Plant Protection, Zagreb, Croatia

ABSTRACT: Poisoning with acetylcholinesterase inhibitors in dogs is described. Diagnosis is confirmed by presence of carbofuran, chlorpyrifos and their metabolites in livers of poisoned dogs

Keywords: acetylcholinesterase inhibitors (carbofuran, chlorpyrifos); dog

Several cases of sudden death in dogs suspect of poisoning were recorded in the Split mountain hinterland over a 10-day period in November 2002. One of the cases referred to a 2.5-year-old Border collie specially trained for tracking people. The dog spent all day long training on the Mosor mountain. Late afternoon, on descent from the mountain, it was seen to eat something. Half an hour later, the dog started drooling and exhibited tremor. It was taken to the car and died on the way to the veterinarian, i.e. in some 30 minutes.

Due to the long time elapsed from death and advanced decay processing, autopsy was not performed, only the liver was taken for toxicology. The method of thin-layer and gas chromatography revealed the presence of carbofuran (3.2 mg/kg) and its main metabolites ketocarbofuran (7.8 mg/kg); 3-hydroxycarbofuran (12.9 mg/kg), which is the main metabolite and is as toxic as the original molecule; respective phenol (9.1 mg/kg), unbound; and respective 3-hydroxyphenol (4.6 mg/kg).

Carbofuran is an insecticide and nematocide used in crop protection, classified by the Environmental Protection Agency (EPA) in group I according to toxicity. The acute oral LD₅₀ for dog is 15 mg/kg and for rat 8 mg/kg (The Pesticide Manual, 2000).

The second case referred to four Balkan pointers released to the hunting ground at 7.15 a.m. After 1–1.5 h, all four dogs were found dead within 150-m distance, with abundant foam around the mouth.

One of the four dogs, an 11-month-old bitch, was transferred to the School of Veterinary Medicine, where autopsy was performed and material for toxicology was obtained.

Necropsy changes were unspecific and the predominant finding was general congestion of all parenchymatous organs with pancreatic interstitial hemorrhages, severe lung hemorrhagic edema, and very mild icteric discoloration. However, histopathologic changes were more specific and revealed, besides lung congestion and edema, various stages of reversible liver and myocardial degeneration. The most prominent finding was vacuolar gangliocyte degeneration in the lumbar segment of the spinal cord (Figure 1).

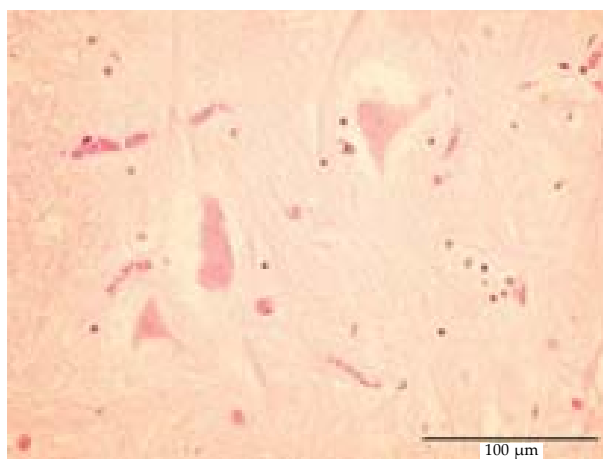


Figure 1. Vacuolar gangliocyte degeneration in the spinal cord (HE, 40×)

The method of thin-layer and gas chromatography indicated the presence of chlorpyrifos ethylester (24 mg/kg) and its metabolites trichlorpyridinol (7 mg/kg) and chlorpyrifos oxone (12 mg/kg).

Chlorpyrifos is an insecticide used in crop protection, classified by EPA in group II according to toxicity. The acute oral LD₅₀ for rat is 135–163 mg/kg (Tomlin, 2000).

DISCUSSION

The concentrations of both insecticides and their metabolites found in the liver of dead animals were high enough to cause acute poisoning with lethal outcome. The mechanism of toxic action of the two compounds is almost identical, differing only in the fact that carbofuran belonging to the group of carbamates, and chlorpyrifos belonging to the group of organophosphates, induce reversible and irreversible inhibition of the acetylcholinesterase enzyme (AChE), respectively, with consequential accumulation of acetylcholine which causes excessive synaptic neurotransmitter activity in the parasympathetic (cholinergic) nervous system and at neuromuscular (nicotinic) sites. This usually results in an acute onset of clinical signs categorized into three syndromes: muscarinic (vomiting, diarrhea, salivation, lacrimation, myosis, dyspnea, bradycardia); nicotinic (muscle tremor and twitching, paresis progressing to paralysis); and central (depression, behavioral or personality changes, hyperactivity, seizures).

The treatment, if timely, includes the administration of emetics (if the animal has not vomited), adsorbent and atropine or diphenhydramine (not along with atropine), and cholinesterase reactivators (pralidoxime chloride, 2-PAM – not recommended for use with carbamate poisoning) (Osweiler, 1996).

Pathomorphological changes in acute organophosphorous poisoning with AChE inhibition are quite unspecific, and in most cases death is primarily due to respiratory failure. However, the present finding of vacuolar gangliocyte degeneration differs from the findings reported in the literature, mainly pointing to axonal edema and degeneration, and this only in organophosphorous compound (cresyl compounds) induced delayed neurotoxicity (Storts and Montgomery, 2001).

Both events reported herewith occurred in the local hunting grounds. The poison must have been brought there by some irresponsible individuals, in the first case for elimination of predators inflicting damage to the game, and in the second case probably due to some disagreements among local people. Both events are also an example of misusing plant protection chemicals. Based on the positive toxicologic reports, both cases will probably be taken to court.

REFERENCES

- Osweiler G.D. (1996): Toxicology. Williams and Wilkins, Philadelphia. 231–237.
- Tomlin C. (2000): The Pesticide Manual. A World Compendium, Crop Protection Publication. 12th ed. The Royal Society of Chemistry. 152–153; 200–201.
- Storts R.W., Montgomery D.L. (2001): The nervous system. In: McGavin M., Carlton W.W., Zachary J.F. (eds.): Thompson's Special Veterinary Pathology. Mosby, A Harcourt Healthy Sciences Company, St. Louis, London, Philadelphia, Sydney, Toronto.

Received: 03–04–14

Accepted after corrections: 03–05–05

Corresponding Author

Prof. dr. Emil Srebočan, Department of Pharmacology and Toxicology, Faculty of Veterinary Medicine, University of Zagreb, Heinzelova 55, 10000 Zagreb, Croatia
Fax +385 244 1390, e-mail: emil@vef.hr
