

## Reduction of *Chlamydomphila-felis*-associated signs by roxithromycin treatment regimen in cats showing doxycycline intolerance

K. PLONECZKA-JANECZKO, J. BANIA, K. BIEROWIEC, M. KIELBOWICZ,  
Z. KIELBOWICZ

Faculty of Veterinary Medicine, Wrocław University of Environmental and Life Sciences,  
Wrocław, Poland

**ABSTRACT:** *Chlamydomphila felis* (*C. felis*) causes chronic conjunctivitis in cats, and is frequently treated with tetracyclines. However, tetracyclines may cause gastrointestinal side effects, such as vomiting, loss of appetite, diarrhoea, and increased liver enzyme activity in some pets. We evaluated the effect of a four-week treatment regimen with roxithromycin – RXM (Rulid® Sanofi-Aventis, France) in 14 cats with conjunctivitis that tested *C. felis*-positive, and exhibited doxycycline intolerance. The treatment was given for four weeks. Assessment of clinical disease was performed on Day 0 and Day 56. Changes in severity of clinical signs were assessed on a three-step scale (increased, decreased, or no changes) every week of the therapy (Days 7, 14, 21, and 28). Additionally, conjunctival swabs were collected on Days 0 and 56 from each animal, and the *C. felis*-count was assessed through amplification of the ompA gene by real-time PCR with fluorogenic probes and normalisation to the feline DNA signal. Animals receiving RXM improved regarding the ophthalmological parameters related to manifestation of conjunctivitis, severity of ocular discharge and nasal discharge and breathing patterns ( $P \leq 0.05$ ). A visible improvement in relation to these parameters was already observed after two weeks of RXM administration. *C. felis*-counts decreased in nine cats that were given RXM, but in the other five *C. felis* was not eliminated. Interestingly, however, aggravation of symptoms was not observed in these five animals. Further studies are needed to fully confirm that a reduction of clinical signs and pathogen counts under conditions of natural infection can be attributed to RXM treatment, since there was no control group that received placebo or another drug in this study. The present results also indicate that in some cases 28 days of RXM administration will not be sufficient to eliminate infection.

**Keywords:** cats; chlamydomphilosis; conjunctivitis; alternative therapy; roxythromycin RXM

*Chlamydomphila felis* (*C. felis*) is an important pathogen in feline conjunctivitis. Infected cats are frequently treated with tetracyclines (e.g., doxycycline and oxytetracycline) (Dean et al. 2005; Stephens et al. 2009; Hartmann et al. 2010), although fluoroquinolones may also be an effective treatment (Hartmann et al. 2008). However, tetracyclines (especially doxycycline) may cause gastrointestinal side effects, such as vomiting, loss of appetite, diarrhoea, and increased liver enzyme activity in some pets. For example, a long-term study indicated that anorexia, diarrhoea, and vomiting occurred in 6% to 13% of cats treated with this

antibiotic, with increased liver enzymes noted in 6% to 18% of cats (Schulz et al. 2011; Schulz et al. 2013). Furthermore, German et al. (2005) described a risk of damage resulting in oesophageal strictures after doxycycline treatment, concluding that the therapy should be accompanied by water or food supplementation. Tetracycline treatment should also be avoided in pregnant queens and growing kittens (Hartmann et al. 2008).

Roxithromycin (RXM) is a semi-synthetic macrolide antibiotic derivative of erythromycin (Koopaei et al. 2012) that shows high tissue penetration and activity against *Rickettsia* spp., *Chlamydia* spp., and

doi: 10.17221/8534-VETMED

*Mycoplasma* spp. (Steel et al. 2012). RXM showed good efficacy and safety in treating genitourinary chlamydial infections, as well as in *Chlamydophila pneumoniae*-associated peripheral arterial occlusive disease in human medicine (Worm et al. 1989; Krayenbuehl et al. 2005). RXM restored the epithelial defence function of the respiratory tract in chronic inflammatory diseases in rabbits (Nakano et al. 1998). RXM also prevented the occurrence or recurrence of *otitis media* with effusion in guinea pigs (Sugiura et al. 1997a). RXM was effective in treating *Borrelia burgdorferi* infections in experimental animals (Preac-Mursic et al. 1989), with no hepatic first-pass effect in rats (Padovan et al. 2012).

Macrolide therapy may have anti-inflammatory properties, as described in human patients with chronic respiratory infections (Amsden 2005). Erythromycin, azithromycin, clarithromycin, and RXM may inhibit chemotaxis and neutrophil infiltration into the respiratory tract, thereby decreasing mucus secretion. Macrolides inhibit the production of many pro-inflammatory cytokines (interleukin – IL-1, IL-6, IL-8, and tumour necrosis factor TNF-alpha *in vitro* and *in vivo*). Macrolides also block the formation of the adhesive molecules necessary for neutrophil migration, and they enhance ciliary activity in chronic inflammatory diseases (Sugiura et al. 1997b; Tamaoki et al. 2004).

The efficacy of RXM in treating *Chlamydia*, as well as its anti-inflammatory properties suggests that it might be a good alternative in the treatment of feline chlamydophilosis. Therefore, the aim of this study was to evaluate the clinical efficacy of oral RXM treatment in tetracycline-intolerant cats with chronic conjunctivitis caused by *C. felis*.

## MATERIAL AND METHODS

This study included 14 privately owned cats with predominant conjunctivitis that were positive for *C. felis* by PCR, based on methodology described by Marsilio et al. (2004). All cats were also tested by RT-PCR and PCR to determine the presence of feline herpesvirus 1 (FHV-1) and *Mycoplasma felis* infections, according to published protocols (Helps et al. 2003; Chalker et al. 2004). The owners gave their consent for participation and also answered a questionnaire. The main criterion for study inclusion was a negative response to doxycy-

cline, including vomiting and/or diarrhoea, within the first three days of administration. Other frequent causes of the sudden appearance of these symptoms, such as dietary errors, foreign bodies, and hairballs, were excluded during anamnesis and clinical examination. The characteristics of the examined population are provided in Table 1. A scoring system for the evaluation of clinical signs was adapted from Hartmann et al. (2008) to enable the assessment of clinical disease (Table 2). Each sign was assessed separately and subsequently the total score was calculated summarising the score of each signs. Clinical signs were independently assessed by the same person, with a maximum score of 18. All cats were retested to confirm *C. felis* infection by RT-PCR, with a less than a one-week interval between discontinuation of doxycycline treatment and sampling.

Conjunctival samples from the ventral conjunctival fornix were collected in pairs using sterile cotton-tipped swabs and prepared for RT-PCR, as described by Sykes (2005). Briefly, DNA from each swab pair was extracted directly with the QIA Amp Ultra Sens Virus kit (Qiagen, Syngen Biotech, Wrocław, Poland). Primers specific to the *C. felis* ompA gene (forward primer, 5'-GAACTGCAAG CAACACCACT G-3' and reverse primer 5'-CCATTCGGCA TCTTGAAGAT G-3') were used together with a fluorogenic probe: 6-FAM-CGCTGCCGAC AGATCAAATT TTGCC-BHQ. The feline 28S rDNA gene served as the endogenous housekeeping gene for feline conjunctival cells, using the primers described by Helps et al. (2003) and the probe, CGCGCACCTT ACTGATGATG TGTTGTTGCC GCGCG, labelled with Texas red on the 5' end and the appropriate BHQ1 on the 3' end. All reactions were performed in duplicate. Each RT-PCR-reaction was performed in a 20- $\mu$ l mixture containing 10 pM of each ompA gene primer, 20 pM of each 28S rDNA gene primer, 10 pM of the FAM/BHQ, and 20 pM of the Texas red/BHQ1 probes, 1  $\mu$ l of template, and 10  $\mu$ l of Kappa Probe FAST qPCR Master mix (Kappa Biosystems, USA). The reaction mixture was heated to 95 °C for 3 min, followed by 45 cycles of PCR consisting of 10 s at 95 °C and 30 s at 60 °C. Fluorescence was detected at the annealing step (iQ5 Multicolor Real-Time PCR Detection System, Bio-Rad Laboratories Ltd., Poland).

DNA from the vaccine 905 *C. felis* strain was used as a control. The relative count of *C. felis* DNA was

calculated from the *C. felis* DNA signal normalised to the feline DNA signal, as described by Dean et al. (2005) and Beshir et al. (2010). The difference between the threshold cycles Ct ( $\Delta$ Ct) of the *C. felis* ompA gene and the Ct of the feline 28 S rDNA gene was calculated using the  $2^{-\Delta\Delta Ct}$  method (Livak and Schmidtgen 2001). The change in  $\Delta$ Ct was calculated after a 4-week treatment ( $\Delta\Delta$ Ct), with time 0 representing the time of pre-treatment diagnostic sampling. To calculate relative *C. felis*-levels, ompA levels from cat No. 1 were arbitrarily set to 1. The percent knockdown (% KD) was calculated by subtracting the normalised  $\Delta\Delta$ Ct of the ompA gene levels at Day 0 and Day 56 and multiplying by 100.

Cats were treated with an oral suspension containing 50 mg RXM (5 mg/kg body weight) every 12 h for four weeks (from Day 0 to Day 28), followed by

a four-week post-treatment-period. Conjunctival swabs were collected on Days 0 and 56. Clinical exams using a scoring system were performed at the start of the study (Day 0) and at the four-week, post-treatment follow-up (Day 56). Additionally, changes in symptom severity were assessed on a three-step scale (increased, decreased, or no changes) every week of the therapy (Days 7, 14, 21, and 28).

The Wilcoxon matched pairs test (a nonparametric alternative to the *t*-test for dependent samples) was used to compare proportions and statistical analysis was performed in Statistica 10.0.0 (StatSoft).

The study was performed in accordance with the ethical principles of the Ethics Committee of the Wrocław University of Environmental and Life Sciences.

Table 1. Characteristics of the examined cat population including clinical signs, environmental factors and potential problems with antibiotic administration, which may influence the clinical efficacy of Rulid® (Sanofi-Aventis, France)

Cat No	Breed, gender, age (years)	Problems with antibiotic administration declared by the owners*	Direct contact with other cats during therapy*	“Outside” animal*	Duration of the disease before treatment (in months)	Other symptoms (accompanying conjunctivitis)
1	BRI, ♂, 8	–	+	+/-	3–6	rubbing the eyes with paws
2	SPH, ♂, 2	–	+	–	6–12	dried scabs around eyes
3	MB, ♂, 2	–	–	–	6–12	blepharospasmus
4	MB, ♀, 6	–	+/-	+	> 12	dried scabs around eyes
5	PER, ♂, 10	+	+	+	> 12	not reported
6	EXO, ♂, 8	+/-	+	–	6–12	coinfection with FHV-1, sequestratio corneae
7	SPH, ♂, 2	+/-	–	–	> 12	dried scabs around eyes and nostrils
8	MB, ♂, 11	–	–	–	> 12	dried scabs around eyes and nostrils
9	DRX, ♀, 7	–	+	–	> 12	earlier coinfection with <i>P. areuginosa</i> , dried scabs around eyes and nostrils
10	EXO, ♀, 3	+/-	–	–	> 12	sequestratio corneae (L), dried scabs around eyes and nostrils
11	MCO, ♂, 5	+	+	–	> 12	not reported
12	PER × EXO, ♀, 3	+/-	+	–	> 12	dried scabs around eyes and nostrils, breathing problems
13	MB, ♀, 4	+/-	+	–	6–12	not reported
14	MB, ♀, 3	–	–	–	6–12	not reported

Breeds (according to EMS/Easy Mind System): MB = mixed breed, PER = Persian, BRI = shorthair British cat, EXO = exotic cat, DRX = devon rex, SPH = sphinx, MCO = Maine Coon

Positive answer (+); negative answer (–); ambiguous answer (+/-, sometimes)

Gender: female ♀ and male ♂

\*questionnaire data

doi: 10.17221/8534-VETMED

Table 2. Evaluation of changes in clinical symptoms between Day (0) and Day (56), after four weeks of RXN (Rulid®, Sanofi-Aventis, France) therapy. Estimation of the severity of clinical signs was performed as proposed by Hartmann et al. (2008). The maximum possible total clinical score was 18 (shaded in bold)

Cat No.	Discharge from one or both eyes <sup>1</sup>		Character of ocular discharge <sup>2</sup>		Conjunctivitis <sup>3</sup>		Nasal discharge <sup>4</sup>		Breathing pattern <sup>5</sup>		Lung sounds <sup>6</sup>		Sneezing <sup>7</sup>		Improvement of clinical signs illustrated as the total clinical score based on the assessment of each clinical symptom*	
									day							
	0	56	0	56	0	56	0	56	0	56	0	56	0	56	0	56
1	2	0	1	0	1	0	0	0	0	0	0	0	0	0	2	0
2	2	0	2	0	2	0	1	0	0	0	0	0	0	0	5	0
3	1	2	4	1	4	1	0	0	0	0	0	0	0	0	8	2
4	2	0	2	0	3	0	1	0	1	0	0	0	0	0	7	0
5	2	1	2	1	3	1	0	0	0	0	0	0	0	0	5	2
6	2	0	2	0	3	0	0	0	0	0	0	0	0	0	5	0
7	2	0	3	1	3	0	1	0	1	0	0	0	0	0	8	1
8	2	1	3	1	3	0	0	0	1	0	0	0	0	0	7	1
9	2	0	3	0	4	0	1	0	1	0	0	0	0	0	9	0
10	2	1	4	2	4	1	1	0	1	1	0	0	1	0	10	4
11	2	0	3	0	1	0	0	0	0	0	0	0	0	0	4	0
12	2	1	4	2	4	2	3	0	2	0	1	0	1	1	15	5
13	2	2	2	1	2	1	0	0	0	0	0	0	0	0	4	2
14	1	0	3	0	2	0	0	0	0	0	0	0	0	0	5	0
P-value (Wilcoxon matched pair test for dependent samples)		<i>P</i> < 0.001		<i>P</i> < 0.001		<i>P</i> = 0.028		<i>P</i> = 0.043		not analysed		not analysed		<i>P</i> < 0.001		

<sup>1</sup>0 = no discharge, 1 = unilateral, 2 = bilateral;

<sup>2</sup>0 = no clinical signs, 1 = minor serous discharge, 2 = moderate serous to mucoid discharge, 3 = moderate mucopurulent discharge, 4 = severe mucopurulent discharge

<sup>3</sup>0 = no clinical signs, 1 = mild conjunctival hyperaemia, 2 = moderate conjunctival hyperaemia and mild chemosis, 3 = moderate to severe conjunctival hyperaemia and moderate chemosis, 4 = severe conjunctival hyperaemia and severe chemosis

<sup>4</sup>0 = no clinical signs, 1 = minor serous discharge, 2 = moderate serous to mucoid discharge, 3 = moderate mucopurulent discharge, 4 = severe mucopurulent discharge

<sup>5</sup>0 = normal, 1 = mild dyspnoea, 2 = moderate to severe dyspnoea; <sup>6</sup>0 = normal, 1 = mild abnormal lung sounds, 2 = moderate to severe lung sounds; <sup>7</sup>0 = absent, 1 = occasionally, 2 = frequently

\*the maximum possible total pre-treatment clinical score (Day 0) = 18, (Day 56) = 18

## RESULTS

All 14 cats from the examined group were positive for *C. felis* DNA on day 0. FHV-1 was detected in one cat (No. 10). *Mycoplasma* spp. were not detected.

All cats receiving RXM improved significantly in all parameters (Table 2), with pre-treatment (Day 0) clinical scores of 6.71 (± 3.24) decreasing to 1.21 on Day 56 (± 1.62) (*P* < 0.001). In clinical examination, there was a reduction in the ocu-

lar discharge (scores changed from 2.71 on day 0 to 0.64 on day 56, *P* < 0.001) and conjunctivitis manifestation (2.78 on day 0 to 0.42 on Day 56, *P* < 0.001). Resolution of the conjunctivitis symptoms was observed in nine cats (64%) by Day 7 of RXM administration, and in all cats by Day 14. Moreover, an improvement in cats receiving RXM was also observed with respect to the severity of nasal discharge (*P* = 0.028) and breathing patterns (*P* = 0.043). Comparability of statistics for lung

sounds and sneezing were excluded due to small variability. According to the owners, there were no reported episodes of vomiting or diarrhoea that could be considered as side effects of RXM therapy. On Day 56, nine cats (64.2%) showed reduced *C. felis* DNA signals relative to pre-treatment (1.006 to 17.1 times smaller than the initial copy number), but increased positive signals (1.2 to 128.5 times greater than the initial copy number) were seen in the other five cats (35.7%) (Figure 1).

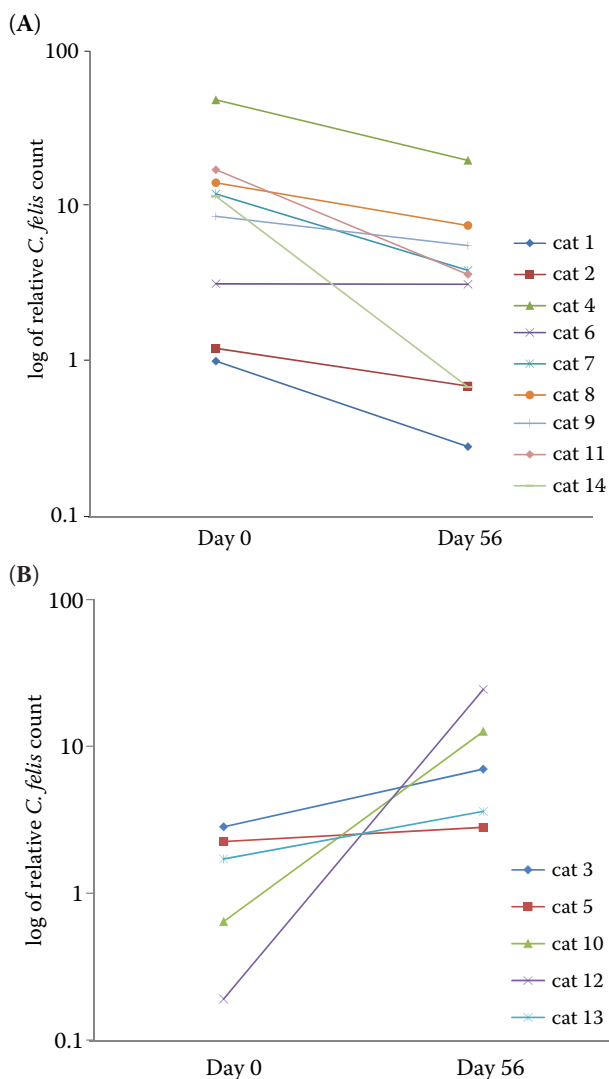


Figure 1. Relative *C. felis*-counts in conjunctival swabs from cats that had been naturally infected with *C. felis* and were suffering from conjunctivitis and doxycycline intolerance. Counts are shown from treatment Day 0 and after 56 days, with RXM treatment for 28 days (5 mg/kg BID, every 12 h) followed by 28 days of no treatment. A = shows animals in which *C. felis* counts decreased after RXM treatment, B = shows animals with increased *C. felis* counts

## DISCUSSION

The lack of standard procedures for the culture-based detection of pathogens from the Chlamydiaceae family, low recovery rates from clinical isolates, and potential heterotypic resistance to antimicrobials make diagnosis and treatment difficult. Antibiotic therapy may be inefficient against *Chlamydia/Chlamydomphila* infections, leading to long-term infections or perturbations in the chlamydial replication cycle (Sandoz and Rockey 2010). Treatment efficacy can also be influenced by factors such as inadequate owner compliance in administering antibiotics; contact with other cats, potentially allowing cross-contamination with *Chlamydomphila*; or variability in exposure to other immune challenges, if the animals are outdoors.

Treatment alternatives to doxycycline for *Chlamydomphila* have been extensively studied. Sturgess et al. (2001) described the efficacy of 19-day-treatment with amoxicillin and clavulanic acid in specific pathogen-free cats experimentally infected with a *C. felis*-isolate. Treatment initially reduced isolate levels and improved clinical status, but recurrence occurred in 62% of cats within 40 days, requiring an additional four weeks of treatment to eradicate the infection. Enrofloxacin (5 mg/kg, for 14 days) improved the clinical signs of conjunctivitis, but an immunofluorescent antibody test on conjunctival swabs revealed that some cats were still positive for *Chlamydia/Chlamydomphila* spp., despite enrofloxacin levels in tears that exceeded the minimum inhibitory concentration for those pathogens (Gerhard et al. 2006). Owen et al. (2003) described the efficacy of azithromycin for the treatment of feline chlamydophilosis. Azithromycin (10–15 mg/kg daily for three days and then twice weekly, at the mean treatment period of 20 days) also improved the clinical signs, but *C. felis* was re-isolated from the majority of examined cats. Initially, daily treatment with 10 mg/kg doxycycline for two weeks was the standard of care for *C. felis* infection. However, even a three-week treatment may be insufficient to eradicate the pathogen completely, as *C. felis* DNA was still detected in some animals 35 days after treatment (Dean et al. 2005). Therefore, we selected a study design with a four-week RXM treatment and a four-week post-treatment period.

To our knowledge, this is the first clinical study in which RXM was used to treat chlamydophilosis in cats with conjunctivitis and doxycycline intolerance.

doi: 10.17221/8534-VETMED

ance. We used a standardised clinical assessment score proposed by Hartmann et al. (2008) to allow inter-study comparison. In Hartmann and others, this score ranged from 4.5 to 4.9 on Day 0, which was lower than in our study, indicating that those animals had better initial clinical presentations. However, both studies showed similar overall improvement rates. In their study pradofloxacin therapy reduced clinical conjunctivitis during the first week of drug administration, and they observed as well as we, an improvement with respect to local effects within the conjunctiva or respiratory tract. Therefore, our four-week oral RXM regimen may be suitable for treating the clinical manifestation of chlamydial conjunctivitis in cats.

A controlled, double-blinded study, performed by Hartmann et al. (2008), involved cats receiving pradofloxacin (5 mg/kg daily for 42 days), doxycycline (5 mg/kg every 12 h) or placebo. We measured *C. felis* DNA levels with the same ompA RT-PCR primers (Dean et al. 2005) and quantification methods. In their study, of the 23 cats positive for *C. felis* on Day 0, 17% had pathogen-specific DNA at the end of the treatment. Some cats were still *C. felis*-positive on Day 42, despite being negative in the RT-PCR test during the study. We found that 35.7% of cats treated with RXM remained *C. felis*-positive on Day 56. Dean et al. (2005) concluded that 21 days of doxycycline therapy eradicated *C. felis* in 53% of pathogen-free-derived cats infected with *C. felis* ( $3 \times 10^3$  infectious units of field isolate). However, the differences in infectious route (inoculation onto the conjunctiva in SPF cats vs. natural infection) and timing make comparison of these studies difficult. In some cases even longer (28 days) therapy is needed to eradicate *C. felis*, according to Hartmann et al.'s studies (Hartmann et al. 2008). In naturally infected cats treated with doxycycline the initial infection level may also determine *C. felis* clearance. The variability in initial infection levels and inter-animal responses to therapy are a major study limitation. The long duration of infection (six to 12 months or longer) may have prevented complete *Chlamydomphila* clearance in the five cats that tested positive at the end of the study. Three cats that showed increased *C. felis* counts after RXM treatment also showed mucopurulent discharge during the therapy, suggesting concomitant bacterial infection. Variability in epidemiological differences, such as the risk of re-infection from contact with carriers at home or outside, could also make in-

terpretation difficult. Three cats that did not show reduced *C. felis* counts were exposed to other cats in the house, although the infection status of these other cats is unknown. One cat was permanently living outside, which may have affected its exposure to *C. felis* from other animals. We conclude that a limited ability to isolate cats from the environment or to change owner habits makes it difficult to rule out the contribution of environmental factors to infection or re-infection rates. There are a few possible reasons for the observed improvement of clinical signs in all cats despite the increases in *C. felis* counts in some individuals. The most important ones in our opinion include, potentially additional secondary bacterial pathogens involved in conjunctivitis and sensitive to RXM and/or the possibility of *C. felis* re-infection. The incidence of these types of re-infections during conjunctivitis (under natural conditions) is not well known and should be studied in more detail. Therefore, there is no evidence regarding the replication and quantitative analysis of *C. felis* in such cases.

Outcomes of RXM therapy may also be influenced by the initial doxycycline treatment. Inhibiting the normal replication cycle of Chlamydiae by transient antibiotic administration can result in persistence and subsequent long-term infection. Antibiotic treatment causes the formation of aberrant reticular bodies that continue to synthesise proteins and replicate DNA but halt cell division (Sandoz and Rockey 2010). Doxycycline treatment was discontinued because of negative side effects in the animals, but such discontinuation may lead to chlamydial persistence *in vitro*, and increased difficulty in eradicating it *in vivo* (Sandoz and Rockey 2010). However, the limited extent of doxycycline administration (three days) makes it difficult to assess its contribution to the persistence of the infection. Wyrick and Knight (2004) reported the appearance of azithromycin-resistant *Chlamydia* strains in response to penicillin exposure.

In conclusion, we report a marked clinical improvement in cats infected with *C. felis* receiving a four-week dosing regimen of RXM. However, RXM treatment does not guarantee the clearance of *C. felis* from the animals, especially, if some epidemiological factors may not be eliminated. Further studies on feline populations with control groups are necessary in order to determine the whole potential of RXM in the treatment of cats with *C. felis* conjunctivitis.

## REFERENCES

- Amsden GW (2005): Anti-inflammatory effects of macrolides—an underappreciated benefit in the treatment of community acquired respiratory tract infection and chronic inflammatory pulmonary conditions? *Journal of Antimicrobial Chemotherapy* 55, 10–21.
- Beshir KB, Hallet LR, Ezieula AC, Bailey R, Watson J, Wright SG, Chiodini P, Polley SD, Sutherland CJ (2010): Measuring the efficacy of anti-malarial drugs in vivo: quantitative PCR measurement of parasite clearance. *Malaria Journal* 9, 312. doi:10.1186/1475-2875-9-312.
- Chalker VJ, Owen WM, Paterson CJ, Brownlie J (2004): Development of a polymerase chain reaction for the detection of *Mycoplasma felis* in domestic cats. *Veterinary Microbiology* 100, 77–82.
- Dean R, Harley R, Helps C, Canney S, Gruffydd-Jones TJ (2005): Use of quantitative real-time PCR to monitor the response of *Chlamydomphila felis* infection to doxycycline treatment. *Journal of Clinical Microbiology* 43, 1858–1864.
- Gerhard N, Schultz BS, Werckhentin C, Hartmann K (2006): Pharmacokinetics of enrofloxacin and its efficacy in comparison with doxycycline in the treatment of *Chlamydomphila felis* infection in cats with conjunctivitis. *Veterinary Record* 159, 591–594.
- German AJ, Cannon MJ, Dye C, Booth MJ, Pearson GR, Reay CA, Gruffydd-Jones TJ (2005): Oesophageal strictures in cats associated with doxycycline therapy. *Journal of Feline Medicine and Surgery* 7, 33–41.
- Hartmann AD, Helps CD, Lappin MR, Werckhentin C, Hartmann K (2008): Efficacy of pradofloxacin in cats with feline upper respiratory tract disease due to *Chlamydomphila felis* or *Mycoplasma* infections. *Journal of Veterinary Internal Medicine* 22, 44–52.
- Hartmann AD, Hawley J, Werckhentin C, Lappin MR, Hartmann K (2010): Detection of bacterial and viral organisms from the conjunctiva of cats with conjunctivitis and upper respiratory tract disease. *Journal of Feline Medicine and Surgery* 12, 785–782.
- Helps CD, Reeves N, Egan K, Howard P, Harbour D (2003): Detection of *Chlamydomphila felis* and feline herpesvirus by multiplex real-time PCR analysis. *Journal of Clinical Microbiology* 41, 2734–2736.
- Koopaei MN, Maqhaei MS, Mostavi SH, Jamalifar H, Samadi N, Amini M, Malek SJ, Darvishi B, Atyabi F, Dinavand R (2012): Enhanced antibacterial activity of roxithromycin loaded pegylated poly-lactide-co-glycolide nanoparticles. *Daru* 20, 92. doi: 10.1186/2008-2231-20-92.
- Krayenbuehl PA, Wiesli P, Maly FE, Vetter W, Schultess G (2005): Progression of peripheral arterial occlusive disease is associated with *Chlamydia pneumoniae* seropositivity and can be inhibited by antibiotic treatment. *Atherosclerosis* 179, 103–110.
- Livak KJ, Schmittgen TD (2001): Analysis of relative gene expression data using real-time quantitative PCR and the  $2^{-\Delta\Delta Ct}$  method. *Methods* 25, 402–408.
- Marsilio F, Di Martino B, Di Francesco C (2004): Use of a duplex-PCR assay to screen for feline herpesvirus-1 and *Chlamydomphila* spp. in mucosal swabs from cats. *New Microbiologica* 27, 287–292.
- Nakano T, Ohashi Y, Tanaka A, Kakinoki Y, Washio Y, Nakai Y (1998): Roxithromycin reinforces epithelial defence function in rabbit trachea. *Acta Oto-Laryngologica* 538 (Suppl.), 233–238.
- Owen WM, Sturgess CP, Harbour DA, Egan K, Gruffydd-Jones TJ (2003): Efficacy of azithromycin for the treatment of feline chlamydomphilosis. *Journal of Feline Medicine and Surgery* 5, 305–311.
- Padovan J, Ralic J, Letvus V, Milic A, Benetic Mihajlevic V (2012): Investigating the barriers to bioavailability of macrolide antibiotics in the rat. *European Journal of Drug Metabolism and Pharmacokinetics* 37, 163–171.
- Preac-Mursic V, Vilske B, Schierz G, Suss E, Gross B (1989): Comparative antimicrobial activity of the new macrolides against *Borrelia burgdorferi*. *European Journal of Clinical Microbiology and Infectious Diseases* 8, 651–653.
- Sandoz KM, Rockey DD (2010): Antibiotic resistance in *Chlamydiae*. *Future Microbiology* 5, 1427–1442.
- Schulz BS, Hupfauer S, Ammer H, Sauter-Louis C, Hartmann K (2011): Suspected side effects of doxycycline use in dogs – a retrospective study of 386 cases. *Veterinary Record* 169, 229. doi:10.1136/vr.d4344.
- Schulz BS, Zauscher S, Ammer H, Sauter-Louis C, Hartmann K (2013): Side effects suspected to be related to doxycycline treatment. *Veterinary Record* 172, 184. doi:10.1136/vr.101031.
- Steel HC, Theron AJ, Cockeran R, Anderson R, Feldman C (2012): Pathogen- and host-directed anti-inflammatory activities of macrolide antibiotics. *Mediators of Inflammation* 2012, 2012: 58426. doi: 10.1155/2012/584262.
- Stephens RS, Meyers G, Eppinger M, Bavoil PM (2009): Divergence without difference: phylogenetics and taxonomy of *Chlamydia* resolved. *FEMS Immunology and Medical Microbiology* 55, 115–119.
- Sturgess CP, Gruffydd-Jones TJ, Harbour DA, Jones LR (2001): Controlled study of the efficacy of clavulanic acid-potentiated amoxicillin in the treatment of *Chlamydia psittacii* in cats. *Veterinary Record* 149, 73–76.
- Sugiura Y, Ohashi Y, Nakai Y (1997a): Roxithromycin stimulates the mucociliary activity of the Eustachian Tube and modulates neutrophil activity in the healthy guinea pigs. *Acta Oto-Laryngologica* 531 (Suppl.), 34–38.

---

doi: 10.17221/8534-VETMED

Sugiura Y, Ohashi Y, Nakai Y (1997b): Roxithromycin prevents endotoxin-induced otitis media with effusion in guinea pigs. *Acta Oto-Laryngologica* 531 (Suppl.), 39–51.

Sykes JE (2005): Feline Chlamydophilosis. *Clinical Techniques in Small Animal Practice* 20, 129–134.

Tamaoki J, Kadota J, Takizawa H (2004): Clinical implication of the immunomodulatory effects of macrolides. *The American Journal of Medicine* 117 (Suppl. 9A), 5–11. doi: 10.1016/j.amjmed.2004.07.023

Worm AM, Hoff G, Kroon S, Petersen CS, Christensen JJ (1989): Roxithromycin compared with erythromycin

against genitourinary chlamydial infections. *Genitourinary Medicine* 65, 35–38.

Wyrick PB, Knight ST (2004): Pre-exposure of infected human endometrial epithelial cells to penicillin in vitro renders *Chlamydia trachomatis* refractory to azithromycin. *Journal of Antimicrobial Chemotherapy* 54, 79–85.

Received: 2015–01–12

Accepted after corrections: 2015–09–18

---

Corresponding Author:

Zdzisław Kielbowicz, Wrocław University of Environmental and Life Sciences, Faculty of Veterinary Medicine, Department and Clinic of Veterinary Surgery, Plac Grunwaldzki 51, 50-366 Wrocław, Poland

E-mail: [zdzislaw.kielbowicz@up.wroc.pl](mailto:zdzislaw.kielbowicz@up.wroc.pl)

---