Advanced non-melanoma skin cancers of the head and neck: an overview on management

Michael J Veness ■ Head and Neck Cancer Service, Westmead Hospital
Department of Radiation Oncology, University of Sydney, NSW
Email: michael@radonc.wsahs.nsw.gov.au

Abstract

Non-melanoma skin cancers occur at an epidemic rate in Australia and are increasing in incidence worldwide. In most patients local treatment is curative. However, a subset of patients will be diagnosed with an advanced non-melanoma skin cancer, defined as: a subset of patients with cutaneous squamous cell carcinoma considered at increased risk of developing metastases to regional lymph nodes (high-risk squamous cell carcinoma); all patients with proven metatstatic cutaneous squamous cell carcinoma to regional lymph nodes; all patients diagnosed with Merkel cell carcinoma; and a minority of patients with a basal cell carcinoma. Patients with an advanced non-melanoma skin cancer are often candidates for combined modality treatment. Patients with high-risk cutaneous squamous cell carcinoma may be identified based on primary lesion and patient factors, with most lesions arising on the sun exposed head and neck. In patients with proven nodal metastases the parotid and upper cervical nodes are frequent sites for metastases. Patients with operable nodal disease should be recommended surgery and adjuvant radiotherapy. Despite this many patients still experience relapse and die. Research aimed at improving outcomes, such as randomised trial incorporating the addition of chemotherapy (weekly carboplatinum) to adjuvant radiotherapy, is currently in progress in Australia and New Zealand under the auspices of the Trans Tasman Radiation Oncology Group. All patients with Merkel cell carcinoma (primary cutaneous endocrine carcinoma) should be recommended loco-regional adjuvant radiotherapy. Recent evidence from a Trans Tasman Radiation Oncology Group phase II study also suggests combination platinum chemotherapy may be beneficial, although randomised evidence is lacking. The aim of this article is to discuss the management of patients with advanced non-melanoma skin cancers of the head and neck.

Non-melanoma skin cancer (NMSC) is the most common malignancy worldwide and a consequence of chronic sun exposure.[1] Most patients (75-80%) will have a small basal cell carcinoma (BCC) and a minority will have a cutaneous squamous cell carcinoma (cSCC), with the sun exposed head and neck the commonest site (70-80%) for a NMSC. The worldwide incidence of NMSC has markedly increased and continues to rise.[2] Australia has the highest incidence of NMSC[3] and in regions of Northern Australia the annual incidence of cSCC in males exceeds 1300/100,000 population.[4] All patients with cSCC are at risk of developing nodal metastases, although overall only a minority (2-3%)[5,6] ever do so. Despite this, hospital referred patients with cSCC often have a higher incidence (10-20%) of nodal metastases. The development of metastases places patients at risk of significant morbidity and death.[7,8]

Patients developing nodal metastases will usually have a high-risk cSCC[9,10] and the number of patients diagnosed worldwide with cSCC makes this a major public health issue. Many Australians die as a consequence of metastatic cSCC, with one Western Australian study documenting 120 NMSC deaths (89 SCC, 22 Merkel cell carcinoma, nine other) over a five-year period, which accounted for ~1% of all cancer related deaths.[11] The morbidity of treating patients with metastatic cSCC is considerable, with most requiring major surgery followed by six to seven weeks of adjuvant radiotherapy. Although the early literature suggested a very poor outcome with current best practice (surgery and radiotherapy), five-year disease free survival is around 70% to 75%.[12,13] Although most patients with NMSC can be considered at low risk of morbidity or mortality, an increasing number of patients are diagnosed with an advanced NMSC defined as: a subset of patients with cSCC considered at increased risk of developing metastases to regional lymph nodes (high-risk cSCC); all patients with proven metastatic cSCC to regional lymph nodes; all patients diagnosed with Merkel cell carcinoma; and a minority of patients with a BCC.

Patients with an advanced NMSC are often candidates for combined modality treatment. The management of these patients should be within the confines of a multidisciplinary team experienced in the management of these often complex cases.

Squamous cell carcinoma

The current clinical staging system inadequately prognosticates for patients with cSCC.[14] Important tumour features such as lesion thickness/depth of invasion, histological grade, or the presence of perineural invasion or lymphovascular invasion are not considered (Table 1). Patient factors such as immunosuppression are also important (discussed later). Management decisions are infrequently made based on just one unfavourable factor since patients often have multiple clinicopathological high-risk factors (eg. thick cSCC (>4mm), recurrent setting, vicinity of

parotid gland). Clinicians should be aware of patients with high-risk factors so that appropriate management decisions can be applied.[15-22]

Table 1
High-risk primary cutaneous SCC features

Features
Thick or deeply invasive (>4-5mm)
Clark level III or greater
Large size (>2cm)
Recurrent
High-grade
Perineural or lymphovascular invasion
Ear/periauricular or lower lip lesion
Rapid growth

Note: Patients usually have a combination of high-risk features

Management of patients with high-risk cSCC

Patients with high-risk cSCC should be recommended wide local excision to achieve oncological excision margins (4-5mm). However, surgery may be constrained by cosmetic and functional consequences and a non-surgical approach (ie. radiotherapy) may be considered. Advanced and destructive cSCC (eg. T3/T4 lesions) may also require complex (vascularised flap) reconstruction. Moh's micrographic surgery (margin controlled excision) is often considered the 'gold standard' in treating high-risk patients. In a large Australian series of patients treated with Moh's micrographic surgery, many with high-risk tumours, only 4% recurred.[23] These control rates concur favourably with the results of other Moh's series and highlight the importance of margin-controlled excision.

There is a role for both definitive (Table 2) and adjuvant radiotherapy, if indicated.[24] Patients with a 2-3cm cSCC probably have a similar outcome with either definitive radiotherapy or surgery, however excision should be considered as the first option. Larger lesions should be considered for combined treatment, although this approach is not always possible. The role for adjuvant radiotherapy is important in the setting of incomplete excision since up to 50% of patients will recur with an associated increased risk of developing nodal metastases.[25] Re-excision is often not feasible secondary to cosmetic and functional constraints. Other pathological features, such as the presence of perineural invasion, may also warrant a recommendation of radiotherapy.

Patients with an incompletely excised cSCC are at risk of both local recurrence and subsequent nodal metastases. There is no consensus in the definition of an acceptable surgical margin. Published recommendations, in the setting of lip and other cSCC, range from 3–10mm.[26-28] In a study of 150 excised NMSC (25% cSCC) a 4mm surgical margin resulted in clearance in 97% of cases, compared with a 2mm excision margin achieving this in only 78% of cases.[29] Adjuvant radiotherapy is an efficacious option in reducing local relapse in the setting of a close or positive excision margin.[27] Observation and expectant treatment in patients with an inadequately excised cSCC is not recommended in light of the increased risk of metastatic nodal disease in the recurrent setting (Figure 1).

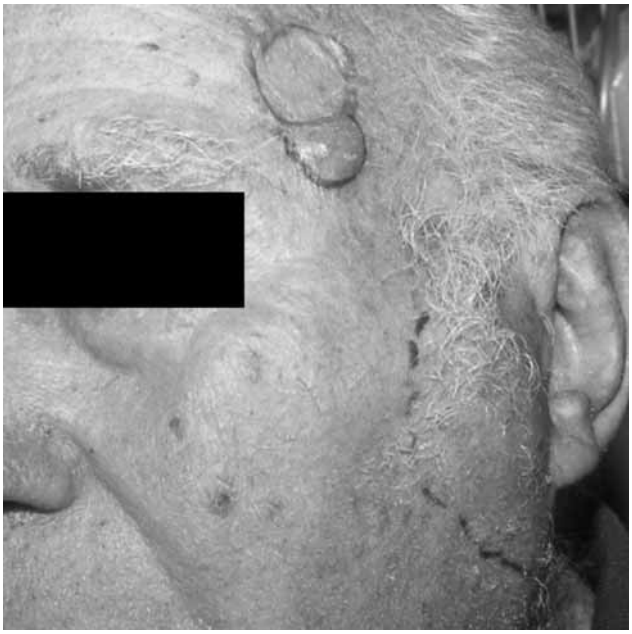

Figure 1
A 65-year-old male with a recurrent left temple SCC occurring at the edge of previous skin graft with concomitant bulky metastatic parotid nodal metastases. The patient underwent major surgery and adjuvant radiotherapy.

Table 2
Patient and tumour factors favouring definitive radiotherapy

Factor	Indication‡
Patient	Older age (>75 years)
	Patient preference (avoidance of surgery)
	Medicated with blood thinning agents (eg. Warfarin)
	Significant medical co-morbidities (risk of perioperative event)
Tumour	Site: Ala nasi, nasal bridge, lower eyelid, lip, inner canthus
	Size: Locally advanced requiring complex surgery

‡ *Many of these factors are relative indications only*

There are emerging data that sentinel node biopsy (SNB) may have a select role in patients with high-risk cSCC.[30,31] In a series of nine patients with high-risk cSCC, four of nine (44%) were positive on SNB, with two subsequently dying of metastatic disease. All node positive patients had SCC >3cm in diameter and >8mm in depth. The five with a negative SNB remained disease free, although the median follow-up of eight months was short.[30] However the role of SNB in patients with high-risk cutaneous head and neck SCC is evolving and still requires further validation and larger studies.

Electively treating nodes to prevent regional relapse may be considered. Radiotherapy[32] or surgery is an option and the recommendation of one over another is based on multiple factors. There are clinical scenarios where first echelon nodes may be treated at the time of primary treatment. For example, surgery to excise a deeply invasive cSCC overlying the parotid gland may require both excision of skin and a superficial parotidectomy. Similarly, adjuvant radiotherapy directed to a high-risk temple cSCC in the setting of incomplete excision may involve a radiotherapy field that also encompasses the parotid nodes.

Perineural invasion (PNI) occurs in ~5-10% of patients, is usually an incidental (microscopic) finding and is reported to be associated with a higher incidence of nodal metastases.[9] Patients presenting with cranial nerve palsies (often trigeminal and facial) have advanced disease and may not be curable. Diagnosis is often delayed for months or years with patients slowly developing progressive signs and symptoms.[33] Although MRI imaging is the investigation of choice (thickened nerves) early disease may not be detectable and an open biopsy may be warranted.[34] Patients with periorbital cSCC with incidental PNI are at risk of orbital spread and further treatment is usually warranted.[35] Adjuvant radiotherapy with the ability to treat widely and encompass neural pathways is often recommended.

Immunosuppression

Immunosuppressed patients are at increased risk of developing a high-risk NMSC, most often cSCC. This is usually in the setting of an organ transplant recipient, although patients with certain haematological malignancies and also HIV patients are also at risk. The management of immunosuppressed patients with NMSC should be in the context of clinicians experienced with managing transplant patients and following accepted management guidelines.[36]

Evidence suggests that many cSCC in organ transplant recipients exhibit histological features considered high-risk. In one study comparing immunocompetent patients and organ transplant recipient, a significantly higher proportion of organ transplant recipient (17 vs 5%; p<0.0001) had thick (>5mm) tumours with early dermal invasion (7 vs 0.3%; p=0.0001) when compared with immunocompetent patients.[37] Of note, immunosuppressed patients that develop metastatic nodal cSCC have a poor outcome. Martinez et al[38] reported the outcome of 60 organ transplant recipients with metastatic skin cancer (85% SCC) and documented a three-year disease specific survival of only 56%.

Patients developing serious and life threatening cutaneous malignancies may be considered candidates for a significant reduction in their level of immunosuppression.[39] Reducing a patient's level of immunosuppression increases the risk of transplant rejection and possibly death. Renal transplant recipients may revert back to dialysis in the case of rejection, however, cardiac and liver recipients do not have this option. There is also ongoing research to identify newer effective immunosuppressants such as sirolimus-based regimens that in turn may be associated with a lower incidence of skin cancer.[40]

Oral retinoids aim to delay or decrease the incidence of NMSC in organ transplant recipient. Although the mechanism of action is unclear there are limited data to suggest a benefit. In a systematic review of the literature only three eligible randomised trials were identified.[41] All trials were small, but two did suggest a benefit in decreasing the incidence of new NMSC in patients taking Acitretin (25-30mg orally daily for six to 12 months) versus placebo. However, tolerability (headaches, mucocutanoeus reactions) with this drug remains a major issue and often necessitates treatment withdrawal.

Metastatic nodal SCC

Most metastatic (60-70%) nodes from head and neck cSCC occur in the parotid gland (+/- cervical nodes). Most patients (70-80%) develop nodal metastases after treatment for a primary cSCC, rather than present with a concomitant primary and nodal disease. A minority (20-30%) will not have an identifiable index lesion and factors not well understood are involved in this subgroup of patients. Median time for the development of nodal metastases following treatment of an index SCC is ~12 months, although late relapse (two to three years) is well documented and justifies ongoing regular follow-up of patients following treatment of a high-risk SCC.[42]

The management of a patient with cutaneous metastatic nodal head and neck SCC has evolved. Most patients that relapse (70-80%) experience loco-regional relapse as the first site of relapse. This finding would suggest that treatment to improve disease control in the head and neck is likely to also impact on survival. Recent publications support best practice in operable patients as surgery and adjuvant radiotherapy.[13,43-45] Patients treated with a combined approach can expect a 20-25% chance of loco-regional relapse and those treated with a single modality (surgery or radiotherapy) can expect a <50% likelihood of achieving freedom from loco-regional relapse. A study from Westmead Hospital, Sydney, confirmed a marked decrease in loco-regional relapse (20 versus 43%) and improved disease free survival (73 versus 54%; p=0.004) with the addition of adjuvant radiotherapy compared to surgery alone. Most recent studies suggest 60 Gy in 2 Gy daily fractions as an acceptable dose of adjuvant radiotherapy to a dissected nodal region and 50 Gy to the undissected at-risk neck.

Ongoing research

Data from a Peter MacCallum Cancer Institute pilot study[46] suggests a possible role for combined treatment in high-risk cSCC patients to improve loco-regional control. A trial testing this hypothesis has been activated under the auspices of the Trans Tasman Radiation Oncology Group (TROG) with the aim to accrue 265 patients randomised to receive adjuvant radiotherapy (60 Gy) or adjuvant radiotherapy and weekly carboplatin (Post-Operative Skin Trial; POST 05.01). Patients with advanced T3/T4 N0 cSCC are also included in this study to test the improvement in local control and where possible to electively treat first echelon nodes.

The TNM staging system currently assigns all patients with metastatic cSCC as stage N1. Using a modified P (Parotid; P0-3) and N (Nodes; N0-2) clinical staging system, O'Brien et al[47] have validated the benefit of proposed new staging system in identifying patients that have a worse prognosis. A recent large collaborative study from six Australian and North American institutions analysed outcome for patients with metastatic cutaneous head and neck SCC using the proposed PN staging system of O'Brien et al.[47] The findings from this study confirm the utility of separate parotid and neck stages in predicting outcome.[48] Patients with pathological involvement of both the parotid and neck did worse compared with those having only parotid disease.

Merkel cell carcinoma

Merkel cell carcinoma (MCC) is a rare and aggressive primary cutaneous neuroendocrine (small cell) skin cancer. Although most patients with a NMSC are cured by local treatment, patients with MCC have a poor outcome characterised by loco-regional (nodal and intransit) and distant relapse.[49,50]

A clinical diagnosis of MCC is difficult to make. Specific histochemical markers are needed to confirm MCC and exclude lymphoma or melanoma. The presence of cytokeratin 20 (CK 20) and neuron specific enolase (NSE), in association with negative markers for melanoma and lymphoma, support a diagnosis of MCC. Lesions often arise as painless dermal nodules on the head and neck in older Caucasian males. Once pathology confirms cutaneous small cell carcinoma, clinicians need to consider the possibility of metastatic small cell lung cancer, especially in smokers. All patients should have chest imaging to exclude lung cancer or the possibility of pulmonary metastases. Patients presenting with clinical nodal metastases should also have CT scans of the abdomen and of the head and neck if the primary is located here.

Treatment

The aggressive nature of MCC is typified by high rates of early (less than 12 months) loco-regional relapse (20-80%) and distant failure (10-60%).[51] Cancer specific death occurs in greater than 25-30% and those with localised disease have the best chance of cure. Surgery remains the initial treatment in patients with operable disease that are fit for an operation and do not have distant metastases. Defining an appropriate surgical margin is controversial, however wide margins of 2-3cm are recommended in light of the risk of subclinical intradermal invasion. Although proponents of excision alone suggest surgery as appropriate treatment in many patients, in a review of 1024 cases the authors identified 11 series (n=441) that documented local relapse rates with, and without, adjuvant radiotherapy. The mean relapse rate reported with the addition of adjuvant radiotherapy was 10 versus 53% without (p=0.00001).[52] Clinicians should therefore attempt to excise lesions with a negative margin. Most patients will be candidates for loco-regional adjuvant radiotherapy and the necessity to obtain wide excision margins at the risk of a poor functional and/or cosmetic outcome should be avoided.[53]

Local excision without treatment to regional nodes does not address the high-risk of subclinical nodal disease (Figure 2). In an Australian study of patients treated with local excision 33% and 50% of patients, respectively, developed regional relapse with lesions 5-10mm and greater than 10mm in size.[54] Therefore, the argument for local excision only, as adequate treatment for a patient with clinically localised MCC, is difficult to defend based on the high rate of regional relapse, which in turn usually portends a poor outcome.

Figure 2
A 75 year-old male with nodal relapse in his left upper neck following local treatment for an 8mm MCC of his upper lip.

Sentinel node biopsy (SNB) may improve the ability to detect subclinical nodal metastases although its exact role is unclear. In a recent meta-analysis (n=122) of patients with MCC undergoing SNB, 32% were found to have micrometatses.[55] The authors reported no significant relapse-free survival benefit (90 versus 70%; p=0.026) to patients undergoing adjuvant radiotherapy in the setting of a negative SNB. Although the authors of this study suggest SNB should be routinely performed in all clinically node negative patients with MCC, further evaluation is required in larger prospective studies.

Patients with nodal disease should have surgery and adjuvant loco-regional radiotherapy. One study demonstrated improved regional control with this multimodality approach, compared with nodal dissection alone (14 versus 43%).[54] Patients with regional relapse are usually incurable either because of untreatable regional disease or the concurrent or subsequent development of distant metastases. In the case of a patient presenting with previously untreated unresectable nodal disease, high-dose radiotherapy (~60 Gy) may 'downstage' the patient so that nodal dissection could follow if disease regression leads to improved operability.

MCC is radiosensitive utilising moderate radiotherapy doses in the range of 45-60 Gy. In some cases patients have been treated with definitive radiotherapy and cured. In a French study nine patients with node negative MCC were treated with radiotherapy alone (median dose 60 Gy) and with a median duration of follow-up of three years none have relapsed, although three have died from unrelated causes.[56] In one series six patients, most with advanced MCC and treated with definitive radiotherapy-obtained tumour control, although most died from subsequent distant relapse.[54] While such anecdotal cases do not add convincing evidence to support a definitive role for radiotherapy in the majority of patients, such cases do highlight the radiosensitivity of MCC to moderate dose radiotherapy even in the setting of macroscopic disease.

With few exceptions most studies report a marked benefit in loco-regional control to the addition of adjuvant radiotherapy. The recent findings of the largest meta-analysis (n=1254)[57] investigating the role of adjuvant radiotherapy in patients with MCC reported patients treated with surgery alone were 3.7 times more likely to develop local recurrence compared with surgery and adjuvant radiotherapy (p<0.001). Similarly, patients treated with surgery alone were 2.9 times more likely to develop regional relapse (p<0.001). A TROG prospective study reported an exceptionally low 17% loco-regional relapse rate in high-risk patients (n=53) treated with radiotherapy and chemotherapy.[58] In a Westmead Hospital study 37% of patients treated with surgery (including seven with nodal dissections for clinical disease) experienced regional relapse compared to 18% treated with surgery and adjuvant radiotherapy (median dose 50 Gy).[54]

The routine use of adjuvant chemotherapy is unclear. In the landmark TROG prospective single arm study, patients needed to have one or more unfavourable features with the authors reporting a three-year overall survival, loco-regional control and distant control rate of 76%, 75% and 76% respectively.[58] These impressive results in patients with poor prognostic features suggests a potential benefit to the addition of combination chemotherapy. A recent Queensland study compared patients treated with the addition of chemotherapy (n=40) with 62 patients treated without chemotherapy.[59] The authors reported no significant overall survival benefit to those patients receiving chemotherapy (p=0.16) and no improvement in distant control (65 versus 70%; p=0.61). While not excluding a possible benefit to chemotherapy these results further add support for a randomised control trial to confirm the hypothesis that chemotherapy is beneficial.

Patients experiencing systemic recurrence are incurable and have a median survival of three to six months. Patients with systemic disease may be candidates for palliative chemotherapy, although many are medically unfit for this treatment. A minority (20-30%) developing only loco-regional recurrence is still potentially curable although the prognosis remains poor. In a study of 46 patients with recurrent MCC, the overall survival was reported as 37%, although almost half (47%) had only local recurrence/persistence followed by distant (40%) and regional failure (13%), respectively.[60] Clinicians should consider fully restaging patients in the setting of loco-regional failure if there is consideration for radical intent retreatment.

Basal cell carcinoma

BCC is rarely life threatening and there is no accepted definition of a high-risk BCC. However, deeply invasive BCC located on the midface, especially if an infiltrative or morpheaform subtype, should be considered high-risk for local morbidity and be treated appropriately, including a recommendation for adjuvant radiotherapy, if indicated. Unlike SCC the risk of nodal and distant metastases is rare and treatment is aimed at securing local control. In most cases local excision obtaining oncological margins is recommended. Radiotherapy is also an option when tumour and patient factors favour this modality.[61]

Further treatment is often recommended in the setting of an incompletely excised BCC. Of concern is a positive deep margin, particularly when a local flap has been used in reconstruction. In such cases deep recurrence can be difficult to detect. The midface and periorbit are sites where undetected deep recurrence may be associated with significant local morbidity. Approximately 20-30% of incompletely excised BCCs recur,[62] with some clinicians advocating immediate re-excision to achieve a negative margin. The aim of adjuvant radiotherapy is to reduce the incidence of local recurrence by eradicating residual microscopic BCC. Though recurrences are rarely associated with serious consequences, extensive salvage surgery may be required. Patients with the more aggressive, but the uncommon subtype of morpheaform BCC, are at a higher risk of local recurrence and are best not left untreated in the setting of inadequate excision. Similarly, recurrent BCC and infiltrative BCC should also be offered treatment if inadequately excised.

Conclusion

Patients with advanced NMSC are best managed within the context of a multidisciplinary head and neck clinic. Many will be candidates for combined treatment incorporating surgery and adjuvant radiotherapy, with emerging evidence in the setting of metastatic nodal disease and MCC that adjuvant radiotherapy significantly improves outcome. Research within Australia is also currently ongoing to investigate the role of chemotherapy to further improve the outcome for these patients. □

References

1. Ramirez CC, Federman DG, Kirsner RS. Skin cancer as an occupational disease: the effect of ultraviolet and other forms of radiation. Int J Dermatol. 2005;44:95-100.
2. de Vries E, de Poll-Franse LV, Louwman WJ, de Gruijl FR, Coebergh JWW. Predictions of skin cancer incidence in the Netherlands up to 2015. Brit J Dermatol. 2005;152:481-488.
3. Staples MP, Elwood M, Burton RC, Williams JL, Marks R, Giles GG. Non-melanoma skin cancer in Australia: the 2002 national survey and trends since 1985. Med J Aust. 2006;184:6-10.
4. Buettner PG, Raasch BA. Incidence rates of skin cancer in Townsville, Australia. Int J Cancer. 1998;78:587-593.
5. Joseph MG, Zulueta WP, Kennedy PJ. Squamous cell carcinoma of the skin. The incidence of metastases and their outcome. ANZ J Surg. 1991;62:697-701.
6. Czarnecki D, Staples M, Mar A, Giles G, Meehan C. Metastases from squamous cell carcinoma of the skin in Southern Australia. Dermatol. 1994;189:52-54.
7. Clayman GL, Lee JJ, Holsinger C, et al. Mortality risk from squamous cell skin cancer. J Clin Oncol. 2005;23:759-765.
8. Nolan RC, Chan MTL, Heenan PJ. A clinicopathologic review of lethal nonmelanoma skin cancers in Western Australia. J Am Acad Dermatol. 2005;52:101-108.
9. Cherpelis BS, Marcusen C, Lang PG. Prognostic factors for metastasis in squamous cell carcinoma of the skin. Dermatol Surg. 2002;28:268-273.
10. Veness MJ. Defining patients with high-risk cutaneous squamous cell carcinoma. Australas J Dermatol. 2006;47:28-33.
11. Nolan RC, Chan MTL, Heenan PJ. A clinicopathologic review of lethal nonmelanoma skin cancers in Western Australia. J Am Acad Dermatol. 2005;52:101-108.
12. Veness MJ, Morgan GJ, Palme C, Gebski V. Cutaneous head and neck squamous cell carcinoma metastatic to cervical lymph nodes: Surgery and adjuvant radiotherapy should be considered best practice. Laryngoscope. 2005;44:870-875.
13. Audet N, Palme CE, Gullane PJ, et al. Cutaneous metastatic squamous cell carcinoma to the parotid gland: analysis and outcome. Head Neck. 2004;26:727-732.
14. LH Sobin. TNM classification of malignant tumours. 6th ed. New York: Wiley and Sons; 2002.
15. Rodolico V, Barresi E, Di Lorenzo R et al. Lymph node metastasis in lower lip squamous cell carcinoma in relation to tumour size, histologic variables and p27kip1 protein expression. Oral Oncol. 2004;40:92-98.
16. Breuninger H, Schaumburg-Lever G, Holzschuh J, Horny HP. Desmoplastic squamous cell carcinoma of skin and vermilion surface. Cancer. 1997;79:915-919.
17. Rowe DE, Carroll RJ, Day CD. Prognostic factors for local recurrence, metastasis, and survival rates in squamous cell carcinoma of the skin, ear and lip. J Am Acad Dermatol. 1992;26:976-990.
18. Veness MJ, Palme C, Morgan GJ. Metastatic cutaneous squamous cell carcinoma of the head and neck: Results of 266 patients with metastatic SCC. Cancer. 2006; 106: 2389-2396.
19. Grover R, Douglas RG, Shaw HFS. Carcinoma of the lip in Auckland, New Zealand, 1969 – 1987. Head Neck. 1989;11:264-268.
20. Brueuninger H, Black B, Rassner G. Brief scientific statement: Microstaging of squamous cell carcinomas. Am J Clin Path. 1990;94:624-627.
21. Petter G, Haustein UF. Histologic subtyping and malignancy assessment of cutaneous squamous cell carcinoma. Dermatol Surg. 2000;26:521-530.
22. Moore BA, Weber RS, Prieto V, El-Naggar A, Holsinger FC, Zhou X, Lee JJ, Lippman S, Clayman GL. Lymph node metastases from cutaneous squamous cell carcinoma of the head and neck. Laryngoscope. 2005;115;1561-1567.
23. Leibovitch I, Huilgol SC, Selva D, Hill D, Richards S, Paver R. Cutaneous squamous cell carcinoma treated with Mohs micrographic surgery in Australia I. Experience over 10 years. J Am Acad Dermatol. 2005;53:253-260.
24. Veness MJ. Treatment recommendations for patients diagnosed with high-risk cutaneous SCC. Australas Radiol. 2005;49:365-376.
25. Huang CC, Boyce SM. Surgical margins of excision for basal cell carcinoma and squamous cell carcinoma. Sem Cutan Med Surg. 2004;23:163-173.
26. de Visscher JG, Gooris PJJ, Vermey A, Roodenburg JLN. Surgical margins for resection of squamous cell carcinoma of the lower lip. Int J Oral Maxillofac Surg. 2002;31:154-157.
27. Babington S, Veness MJ, Cakir B, Gebski VJ, Morgan GJ. Squamous cell carcinoma of the lip: Is there a role for adjuvant radiotherapy in improving local control following incomplete or inadequate excision? ANZ J Surg. 2003;73:621-625.
28. Brodland DG, Zitelli JA. Surgical margins for excision of primary cutaneous squamous cell carcinoma. J Am Acad Dermatol. 1992;27:241-248.
29. Thomas DJ, King AR, Peat BG. Excision margins for nonmelanotic skin cancer. Plast Reconstr Surg. 2003;112:57-63.
30. Reschly MJ, Messina JL, Zaulyanov LL, Cruse W, Fenske NA. Utility of sentinel lymphadenectomy in the management of patients with high-risk cutaneous squamous cell carcinoma. Dermatol Surg. 2003;29:135-140.
31. Wagner JD, Evdokimow DZ, Weisberger E et al. Sentinel node biopsy for high-risk nonmelanoma cutaneous malignancy. Arch Dermatol. 2004;140:75-79.
32. Kwan W, Wilson D, Moravan M. Radiotherapy for locally advanced basal cell and squamous cell carcinoma of the skin. Int J Radiation Oncology Biol Phys. 2004;60:406-411.
33. Warner GC, Gandhi M, Panizza B. Slowly progressive cranial nerve palsies. Med J Aust. 2006;184:641-643.
34. Esmaeli B, Ahmadi MA, Gillenwater AM, Faustina MM, Amato M. The role of supraorbital nerve biopsy in cutaneous malignancies of the periocular region. Ophthal Plast Reconstr Surg. 2003;19:282-286.
35. Veness MJ, Biankin S. Perineural spread leading to orbital invasion from skin cancer. Australas Radiol. 2000;44:296-302.
36. Stasko T, Brown MD, Carucci JA, et al. Guidelines for the management of squamous cell carcinoma in organ transplant recipients. Dermatol Surg. 2004;30:642-650.
37. Smith KJ, Hamza S, Skelton H. Histological features in primary cutaneous squamous cell carcinomas in immunocompromised patients focusing on organ transplant patients. Dermatol Surg. 2004;30:634-641.
38. Martinez JC, Clark CO, Stasko T, Euvard S, Brown C, Schanbacher CF, Weaver AL. Defining the clinical course of metatstatic skin cancer in organ transplant recipients. Arch Dermatol. 2003;139:301-306.
39. Otley CC, Berg D, Ulrich C, et al. Reduction of immunosuppression for transplant-associated skin cancer: expert consensus survey. Br J Dermatol. 2006;124:395-400.
40. Kauffman HM, Cherikh WS, Cheng Y, et al. Maintenance immunosuppression with mTOR inhibitors is associated with a reduced incidence of de novo malignancies. Transplantation. 2005;80:883-889.
41. Chen K, Craig JC, Shumack S. Oral retinoids for the prevention of skin cancers in solid organ transplant recipients: a systematic review of randomized controlled trials. Br J Dermatol. 2005;152:518-523.
42. Talmi YP, Horowitz Z, Wolf M, Kronenberg J. Delayed metastases in skin cancer of the head and neck: The case of the "known primary". Ann Plast Surg. 1999;42:289-292.
43. Dona E, Veness MJ, Cakir B, Morgan GJ. Metastatic cutaneous squamous cell carcinoma to the parotid: The role of surgery and adjuvant radiotherapy to achieve best outcome. ANZ J Surg. 2003;73:692-696.
44. Veness MJ, Palme CE, Smith M, Cakir B, Morgan GJ, Kalnins I. Cutaneous head and neck squamous cell carcinoma metastatic to cervical lymph nodes (nonparotid): a better outcome with surgery and adjuvant radiotherapy. Laryngoscope. 2003;113:1827-1833.
45. Jol JAD, van Velthuysen MLF, Hilgers FJM, Keus RB, Neering H, Balm AJM. Treatment results of regional metastasis from cutaneous head and Neck squamous cell carcinoma. EJSO. 2002;29:81-86.

46. Campbell B, Rischin D, Corry J, et al. Post-operative chemo-therapy for high-risk head and neck squamous cell carcinoma (HNSCC). 12th International Congress of Radiation Research, Brisbane, Australia 2003 (Abstract) PP07/0267 p97.
47. O'Brien CJ, McNeil EB, McMahon JD, Pathak I, Lauer CS, Jackson MA. Significance of clinical stage, extent of surgery and pathological findings in metastatic cutaneous squamous carcinoma of the parotid gland. Head Neck. 2002;24:417-422.
48. Andruchow JL, Veness MJ, Morgan GJ, et al. Implications for clinical staging of metastatic cutaneous SCC of the head and neck based on a multicentre study of treatment outcomes. Cancer. 2006;106:1078-1083.
49. Goessling W, McKee PH, Mayer RJ. Merkel cell carcinoma. J Clin Oncol. 2002;20:588-598.
50. Tai PT, Yu E, Winquist E, Hammond A, Stitt L, Tonita J, Gilchrist J. Chemotherapy in neuro-endocrine/Merkel cell carcinoma of the skin: Case series and review of 204 cases. J Clin Oncol. 2000;18:2493-9.
51 Poulsen M. Merkel-cell carcinoma of the skin. Lancet Oncol. 2005;5:593-599.
52. Medina-Franco H, Urist MM, Fiveash J, Heslin MJ, Bland KI, Beenken SW. Multimodality treatment of Merkel cell carcinoma: Case series and literature review of 1024 cases. Ann Surg Oncol. 2001;8:204-208.
53. Poulsen M, Harvey J. Is there a diminishing role for surgery for Merkel cell carcinoma of the skin? A review of current management. ANZ J Surg. 2002;72:142-146.
54. Veness MJ, Perera L, McCourt J, Shannon J, Hughes M, Morgan GJ, Gebski V. Merkel cell carcinoma: Improved regional control and survival with adjuvant radiotherapy. ANZ J Surg. 2005;75:275-281.
55. Gupta SG, Wang LC, Penas PF, Gellenthin M, Lee SJ, Nghiem P. Sentinel lymph node biopsy for evaluation and treatment of patients with Merkel cell carcinoma. Arch Dermatol. 2006;142:685-690.
56. Mortier L, Mirabel X, Fournier C, Piette F, Lartigau. Radiotherapy alone for primary Merkel cell carcinoma. Arch. Dermatol. 2003;139:1587-1590.
57. Lewis KG, Weinstock MA, Weaver AL, Otley CC. Adjuvant local irradiation for Merkel cell carcinoma. Arch Dermatol. 2006;142:693-700.
58. Poulsen M, Rischin D, Walpole E, Harvey J, Mackintosh J, Ainslie J, Hamilton C, Keller J, Tripcony L. High risk Merkel cell carcinoma of the skin treated with synchronous carboplatin/etoposide and radiation: A Trans-Tasman Radiation Oncology Group study – TROG 96:07. J Clin Oncol. 2003;21:4371-4376.
59. Poulsen MG, Rischin D, Porter I, Walpole E, Harvey J, Hamilton C, Keller J, Tripcony L. Does chemotherapy improve survival in high-risk stage I and II merkel cell carcinoma of the skin? Int J Radiat Oncol Biol Phys. 2006;64:114-119.
60. Eng TY, Naguib M, Fuller CD, Jones WE, Herman TS. Treatment of recurrent Merkel cell carcinoma: An analysis of 46 cases. Am J Clin Oncol. 2004;24:576-583.
61. Veness MJ, Richards S. Role of modern radiotherapy in treating skin cancer. Australas J Dermatol. 2003;44:159-168.
62. Wilson AW, Howsam G, Santhanam V, Macpherson D, Grant J, CA, Townend JV. Surgical management of incompletely excised basal cell carcinomas of the head and neck. Br J Oral Maxillofacial Surg. 2004;42:311-314.