

Infection in a female Komodo dragon (*Varanus komodoensis*) caused by *Mycobacterium intracellulare*: a case report

M. SKORIC¹, V. MRLIK², J. SVOBODOVA³, V. BERAN², M. SLANY², P. FICTUM¹, J. POKORNY⁴, I. PAVLIK²

¹University of Veterinary and Pharmaceutical Sciences, Brno, Czech Republic

²Veterinary Research Institute, Brno, Czech Republic

³Regional Institute of Public Health, Brno, Czech Republic

⁴Veterinary Office StarVet, Stary Plzenec, Czech Republic

ABSTRACT: In early 2002, a bean-like whitish nodule 2 × 1 × 1 cm in size was diagnosed on the tongue of a female Komodo dragon (*Varanus komodoensis*) kept in a zoological garden in the Czech Republic. The nodule was removed at surgery and histopathological examination revealed a specific granulomatous inflammation. The granuloma contained a necrotic mass surrounded by a variable layer of palisading epithelioid macrophages and multinucleated giant cells with a variable admixture of lymphocytes and plasma cells. Signs of mineralisation within the granuloma were not observed. Using Ziehl-Neelsen (ZN) staining the presence of acid-fast rods (AFR) was determined and the presence of mycobacteria was confirmed by PCR. Four years later, this female died after multiple injuries caused by a male during mating. Necropsy and histopathological examinations revealed granulomatous pneumonia and myocarditis with ZN-positive AFR within granulomas. Mycobacteria were cultured from 13 of 19 tissue samples: *Mycobacterium intracellulare* was confirmed by sequencing of isolates from multiple affected organs including the respiratory tract, tail muscle, inguinal lymph nodes and blood; *Mycobacterium* sp. were also isolated from the tongue. In addition, mycobacteria were detected in 15 (46.9%) of 32 environmental samples examined in both years. *M. intracellulare* was detected in water sediment from the female's terrarium in 2002, and in faeces and peat from the terrarium and in water sediment from the male terrarium in 2006. Except for *M. intracellulare* ($n = 4$), *M. smegmatis* ($n = 1$), *M. a. hominissuis* ($n = 3$), *M. fortuitum* ($n = 2$), *M. interjectum* ($n = 1$), *M. peregrinum/alvei/septicum* ($n = 1$) and *Mycobacterium* sp. ($n = 2$) were also isolated from different environmental samples.

Keywords: granuloma; reptile; *Mycobacterium avium* complex; potentially pathogenic mycobacteria; zoonosis

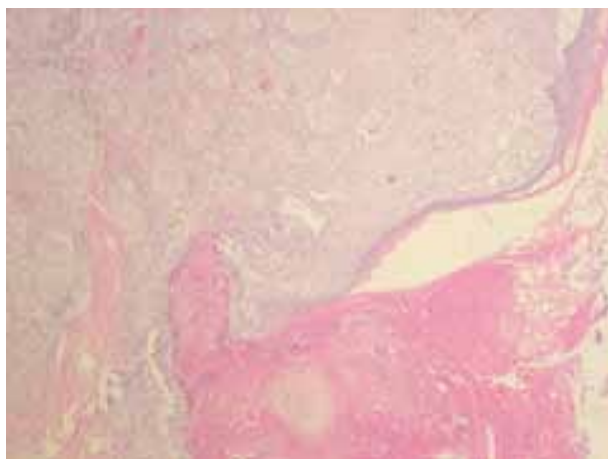Potentially pathogenic mycobacteria (PPM) including *Mycobacterium avium* complex (MAC) members comprise a heterogeneous group of ubiquitous mycobacteria that can cause various diseases in humans and animals including poikilothermic vertebrates. Environmental sources include soil, water, dust, feed etc. (Pavlik and Falkinham 2009). PPM predominate as the etiological agents of sporadic infections in captured reptiles. A commensal relationship between

mycobacteria and host organisms probably exists with actively infected animals being predisposed to disease (Jacobson 2007). Primary causative pathogens in reptiles are very few and mycobacteria belong to this group of pathogens together with *Chlamydia*, *Salmonella* and *Mycoplasma* (Pasmans et al. 2008). The present report details a case of mycobacterial infection in a captured Komodo dragon (*Varanus komodoensis*) caused by *M. intracellulare*.

Supported by the Ministry of Agriculture of the Czech Republic (Grants No. MZE 0002716202 and QH 91240) and the Ministry of Education, Youth and Sports of the Czech Republic (AdmireVet No. CZ.1.05/2.1.00/01.0006-ED 0006/01/01).

Case description

Female and male Komodo dragons were kept separately in two terrariums in a zoological garden in the Czech Republic since 1997. The animals were fed mostly with laboratory rats. In 2002, a bean-like whitish nodular lesion $2 \times 1 \times 1$ cm in size was found on the tongue of a female during preventive clinical examination. There were no other macroscopic pathological lesions observed nor had any deterioration been noted in the patient's condition. The nodule on the tongue was removed at surgery and a biopsy specimen was collected for histopathological examination. The sample was fixed in buffered 10% neutral formalin, dehydrated, embedded in paraffin wax, sectioned on a microtome at a thickness of $4 \mu\text{m}$, and stained with haematoxylin and eosin (H&E) and Ziehl-Neelsen (ZN) for the detection of acid-fast rods (AFR) in the tissue. Histopathological examination revealed a specific granulomatous inflammation. The granuloma contained an irregular necrotic mass surrounded by a variable layer of palisading epithelioid macrophages and multinucleated giant cells with a variable admixture of lymphocytes and plasma cells with the occasional presence of heterophils on the periphery of the granuloma (Figure 1). Signs of mineralization within the granuloma were not observed. Using ZN staining the presence of AFR was demonstrated in tissue of the tongue affected by granulomatous inflammation (Figures 2 and 3). The formalin-fixed paraffin-embedded tongue tissue section was then further analysed; the section was deparaffinised in xylene and subjected to DNA isolation according to a procedure described previously (Slana et al. 2010). The presence of mycobacterial DNA in the tongue tissue was proven by two independent conventional PCR methods



described previously (Mokaddas and Ahmad 2007; Moravkova et al. 2008). From six samples from the terrarium where the female was kept mycobacteria including two members of the MAC (*M. a. hominissuis* and *M. intracellulare*) and *M. smegmatis* were isolated. From the male terrarium, where the female was placed for a few weeks during the mating season, *M. a. hominissuis* was isolated from two out of six environmental samples (Table 1). In 2006 a female Komodo dragon died before intended transportation abroad (Figure 4). During the necropsy no pathological findings were found on external examination of the body. Multifocal gouty infiltrates were found in the subcutis between the fascia of the muscles and on the serosal surface of the pericardium. The walls of both heart atriums were hypertrophic with the presence of several irregular foci of necrosis. The lungs were massively hyperaemic with numerous miliary whitish nodules randomly localized in the parenchyma. The liver was enlarged with rounded edges and was yellow to brown in colour. The kidneys were slightly enlarged and gout pattern was evident on the surface and on the cut surface through the parenchyma. The spleen was slightly enlarged. There were no pathological lesions observed in the gastrointestinal tract, while the stomach contained the remnants of a partially digested rodent. One watery egg yolk was found in the cloaca. The body cavity contained about one litre of partially clotted blood originating from a ruptured follicle on the left ovary. In the neighbourhood of the ruptured follicle another follicle 3×3 cm in size, filled with blood was found, along with several smaller follicles. The right ovary contained several larger follicles up to 2 cm in size. The oviducts were empty and the mucosal surface was covered with mucous exudate. No other gross lesions were observed. Subsequently, tissue

Figure 1. Tongue; Komodo dragon (*Varanus komodoensis*). Granuloma formed predominantly by epithelioid macrophages and lymphocytes with necrotic eosinophilic tissue on the surface, haematoxylin and eosin, $40\times$ (Photo M. Skoric)

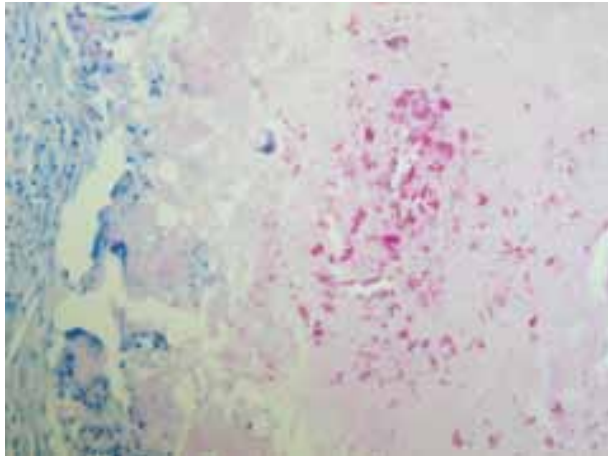


Figure 2. Tongue; Komodo dragon (*Varanus komodoensis*). Multifocal presence of mycobacteria in the granuloma, Ziehl-Neelsen, 400× (Photo M. Skoric)

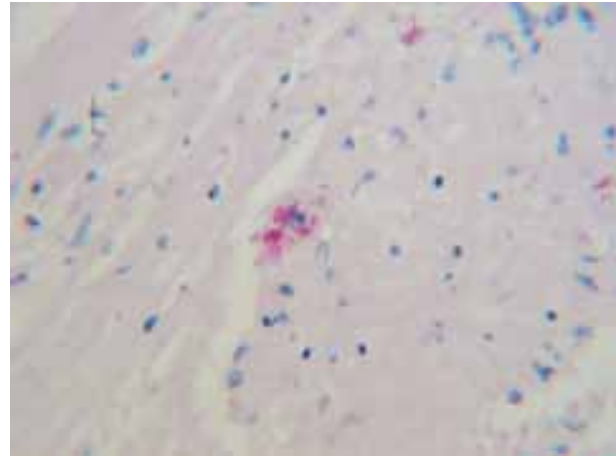


Figure 3. Tongue; Komodo dragon (*Varanus komodoensis*). Mycobacteria in the necrotic tissue of the granuloma, Ziehl-Neelsen, 1000× (Photo M. Skoric)

samples from affected organs were collected for histopathological examination. Samples were fixed in buffered 10% neutral formalin, dehydrated, embedded in paraffin wax, sectioned on a microtome at a thickness of 4 μm , and stained with H&E and ZN for the detection of AFR in tissues. The tissue samples were taken for culture and PCR examinations. Histopathological examination revealed a diffuse to nodular granulomatous inflammatory reaction in the myocardium and epicardium of the atriums containing numerous ZN-positive AFR localised free in the necrotic tissue and phagocytised within macrophages. Besides gouty granulomas, hyperaemia and alveolar oedema, a similar specific granulomatous reaction as in the heart muscle, with the presence of epithelioid macrophages and lymphocytes was observed in the lungs, again with ZN-positive AFR. There were no signs of mineralisation

in the granulomas. Diffuse glomerulonephritis with urate granulomas in the cortex and medulla were found in the kidneys. Diffuse non-specific granulomatous splenitis with occasional urate granulomas was observed. In the liver dystrophic vacuolar changes with hepatocytes containing large lipid droplets (fatty liver degeneration) were seen. ZN staining was negative in the case of the kidneys, spleen and liver. Microscopically, no other organs exhibited pathological lesions (except for the hyperaemia of organs) and ZN staining was negative in all these tissue sections. The formalin-fixed paraffin-embedded tongue tissue section was then further analysed. The tissue section was deparaffinised in xylene and subjected to DNA isolation according to a procedure described previously (Slana et al. 2010). The presence of mycobacterial DNA in the tongue tissue was proven by two independent conventional

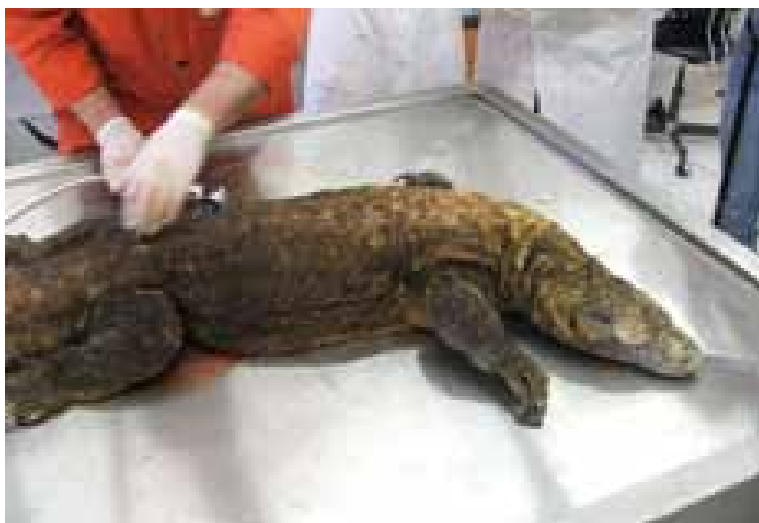

Figure 4. Female Komodo dragon (*Varanus komodoensis*) before necropsy (Photo J. Pokorny)

Table 1. Detection of mycobacteria in female tissues and in the female and male terrariums in samples collected in 2002 and 2006

Year	Tissue/ terrarium	Sample origin	Female			Male		
			No.	pos.	species	No.	pos.	species
2002	tissue	tongue-granuloma	1	1	<i>M. sp.*</i>	nt		
	terrarium	faeces	1	1	<i>M. smegmatis</i>	1	1	<i>M. a. hominissuis</i>
		water sediment-basin	1	1	<i>M. intracellulare</i>	1	0	
		sand-grit	1	0		1	0	
		wood shavings-corridor	3	1	<i>M. a. hominissuis</i>	3	1	<i>M. a. hominissuis</i>
2006	tissue	haemolysed fluid from the body cavity	8	3	<i>M. intracellulare</i>	nt		
		lungs (lobus sn. and dx.)	2	0		nt		
		Inn. tracheobronchialis sn. and dx.	2	2	<i>M. intracellulare</i>	nt		
		Tongue	2	1	<i>M. sp.</i>	nt		
	terrarium	Inn. inqualis sn. and dx.	2	1	<i>M. intracellulare</i>	nt		
		muscle of tail	1	1	<i>M. intracellulare</i>	nt		
		fatty tissue of tail	1	0		nt		
		cloacal mucus	1	1	<i>M. terrae</i>	nt		
		faeces	1	1	<i>M. intracellulare</i>	1	0	
		water sediment-basin	3	3	<i>M. fortuitum</i> <i>M. interjectum</i> <i>M. a. hominissuis</i>	3	2	<i>M. intracellulare</i> <i>M. sp.</i>
		sand-grit	2	1	<i>M. peregrinum/</i> <i>alvei/septicum</i>	2	1	<i>M. sp.</i>
peat	1	1	<i>M. intracellulare</i>	1	1	<i>M. fortuitum</i>		
leaves of decorative plants	3	0		3	0			
Total tissue			20	13	(65.0%)**	nt		
Total terrarium			16	9	(56.3%)	16	6	(37.5%)

sn. = sinister, dx. = dexter, Inn. = lymph nodes, *M.* = *Mycobacterium*, *M. a. hominissuis* = *Mycobacterium avium* subsp. *hominissuis*

*mycobacterial DNA was detected in formalin-fixed paraffin-embedded tongue tissue section with granuloma; analysis was carried out using two independent conventional PCR methods described previously (Mokaddas and Ahmad 2007; Moravkova et al. 2008)

**culture examination was only carried out in the 19 tissue samples collected in 2006

PCR methods described previously (Mokaddas and Ahmad 2007; Moravkova et al. 2008). Culture examination of 32 samples from the environment of both terrariums was also performed. PPM were isolated from nine (56.3%) of 16 samples from the terrarium where the dead female was kept and from six (37.5%) of 16 samples from the external environment of the male terrarium. From 20 tissue samples collected AFR were observed by microscopy in only three tissue impressions: in the lungs, visceral fat tissue and

tongue. Mycobacteria were detected by culture in 13 samples (65.0%). Mycobacteria were also isolated from three of eight samples of the haemolysed fluid from the body cavity (Table 1).

DISCUSSION AND CONCLUSIONS

Mycobacteriosis is a sporadic disease in captured reptiles. With respect to the published data, the

low prevalence of the infection and the ubiquitous presence of mycobacteria in the environment are suggestive of natural resistance to these opportunistic pathogens (Brownstein 1984; Jacobson 2007). Mycobacterial infection in reptiles manifests morphologically as a granulomatous inflammatory reaction with systemic spreading of the pathogen resulting in necrosis (Soldati et al. 2004). The disease may be present in a variety of clinical forms with most organ systems being affected. In our case, tuberculous lesions were found focally only in the tissue of the tongue (Figure 1), and apparently, during a time period of four years, dissemination of the disease progressed to systemic infection with marked alteration of the lungs and heart muscle, which was accompanied by the formation of tuberculous granulomas. There is no precise explanation for why the infection caused by mycobacteria was manifested only in the female, although these were present in the environment of both the animals (Table 1). We did not identify any other underlying diseases in the female acting as possible immunosuppressive factors leading to mycobacterial infection except for repeated injuries caused by the male during the mating season. Clinical diagnosis in reptiles can be difficult due to the non-specific clinical signs of the disease and treatment is often unsuccessful. According to various authors, mycobacterial infections in reptiles have been reported in various species including crocodiles, caimans, turtles, snakes and lizards with the involvement of different organ systems (Olson and Woodard 1974; Rhodin and Anver 1977; Quesenberry et al. 1986; Hernandez-Divers and Shearer 2002; Girling and Fraser 2007; Roh et al. 2010; Slany et al. 2010). The most common mycobacterial isolates from reptiles include *M. marinum*, *M. chelonae*, *M. thamnophaeos*, followed by cases of *M. haemophilum*, *M. kansasii*, *M. agri*, *M. confluentis*, *M. hiberniae*, *M. neoaurum* and *M. nonchromogenicum* (Jacobson 2007). These mycobacterial species were not isolated from the female tissue or from the environment (Table 1). A report on the isolation of mycobacteria belonging to MAC, described as *M. avium*, was made in Pacific green turtles with granulomatous lesions in the liver, spleen and kidneys (Brock et al. 1976). There is only one report in the literature documenting *M. intracellulare* infection in a member of the family Varanidae; this study concerned a water monitor (*Varanus salvator*; Friend and Russell 1979). In our case, the repeated isolation from *M. intracellulare* from different parts of the environment including water sediment from the basin in 2002 and from peat from the female ter-

rarium (Table 1) documented the infection pressure that the reptiles were under. Wounds caused by the male during the mating season were probably infected by these PPM. The excretion of *M. intracellulare* in female faeces could be explained by the isolation of the same mycobacterial species from the environment or this excretion may have been caused by the passage of infected sputum through the gastrointestinal tract. *M. interjectum* was isolated from one brown caiman (*Caiman crocodilus fuscus*) reared in captivity in the Czech Republic (Slany et al. 2010). The isolation of the same pathogen from the water sediment in the basin in the female terrarium demonstrates the threat, which can be posed by the contaminated terrarium environment for injured and non-treated animals. At temperatures higher than 20 °C and especially in conditions of high humidity PPM can grow in organic polluted matrices (Pavlik and Falkinham 2009). Such conditions are present in all terrariums with reptiles. The decorative material (peat, wooden shavings saw, dust, bark etc.) and water environment are often contaminated by members of the MAC including *M. a. hominissuis* and *M. intracellulare* (Pavlik et al. 2000; Krizova et al. 2010; Novotny et al. 2010; Kaevska et al. 2011). The occurrence of mycobacteriosis in zoological gardens may represent a potential threat to other animal species and a risk to the public health, especially to immunocompromised individuals, such as those with HIV/AIDS (Johnson-Delaney 2006). Gross necropsy findings and histopathological examination of the affected organs, along with culture and PCR examinations of specimens reliably confirm the diagnosis post mortem.

Acknowledgement

The authors thank MVDr. Frantisek Cada (Analytical Laboratories Plzen, Czech Republic) for kindly providing information which facilitated the carrying out of this study.

REFERENCES

- Brock JA, Nakamura RM, Miyahara AY, Chang EML (1976): Tuberculosis in Pacific green turtles, *Chelonia mydas*. Transactions of the American Fisheries Society 105, 564–566.
- Brownstein DG (1984): Mycobacterial disease. In: Hoff GL, Frye FF, Jacobson ER (eds.): Diseases of Amphibians and Reptiles. Plenum, New York. 1–23.

- Friend SCE, Russell EG (1979): *Mycobacterium intracellulare* infection in a water monitor. *Journal of Wildlife Diseases* 15, 229–233.
- Girling SJ, Fraser MA (2007): Systemic mycobacteriosis in an inland bearded dragon (*Pogona vitticeps*). *Veterinary Record* 160, 526–528.
- Hernandez-Divers SJ, Shearer D (2002): Pulmonary mycobacteriosis caused by *Mycobacterium haemophilum* and *M. marinum* in a royal python. *Journal of the American Veterinary Medical Association* 220, 1661–1663.
- Jacobson ER (2007): Bacterial diseases of reptiles. In: Jacobson ER (ed.): *Infectious Diseases and Pathology of Reptiles*. CRC Press, Gainesville, Florida. 461–526.
- Johnson-Delaney CA (2006): Reptile zoonoses and threats to public health. In: Mader DR (ed.): *Reptile Medicine and Surgery*. 3rd ed. Saunders-Elsevier, St. Louis. 1017–1030.
- Kaevska M, Slana I, Kralik P, Reischl U, Orosova J, Holcikova A, Pavlik I (2011): *Mycobacterium avium* subsp. *hominissuis* in neck lymph nodes of children and the tracing of infection in the environment by culture and triplex quantitative real time PCR. *Journal of Clinical Microbiology* 49, 167–172.
- Krizova K, Matlova L, Horvathova A, Moravkova M, Beran V, Boisselet T, Babak V, Slana I, Pavlik I (2010): Mycobacteria in the environment of pig farms in the Czech Republic between 2003 and 2007. *Veterinarni Medicina* 55, 55–69. <http://www.vri.cz/docs/vetmed/55-2-55.pdf>
- Mokaddas E, Ahmad S (2007): Development and evaluation of a multiplex PCR for rapid detection and differentiation of *Mycobacterium tuberculosis* complex members from non-tuberculous mycobacteria. *Japanese Journal of Infectious Diseases* 60, 140–144.
- Moravkova M, Hlozek P, Beran V, Pavlik I, Preziuso S, Cuteri V, Bartos M (2008): Strategy for the detection and differentiation of *Mycobacterium avium* species in isolates and heavily infected tissues. *Research in Veterinary Science* 85, 257–264.
- Novotny L, Halouzka R, Matlova L, Vavra O, Bartosova L, Slany M, Pavlik I (2010): Morphology and distribution of granulomatous inflammation in freshwater ornamental fish infected with mycobacteria. *Journal of Fish Diseases* 33, 947–955.
- Olson GA, Woodard JC (1974): Miliary tuberculosis in a reticulated python. *Journal of the American Veterinary Medical Association* 164, 733–735.
- Pasmans F, Blahak S, Martel A, Pantchev N (2008): Introducing reptiles into a captive collection: The role of the veterinarian. *Veterinary Journal* 175, 53–68.
- Pavlik I, Falkinham III JO (2009): The occurrence of pathogenic and potentially pathogenic mycobacteria in animals and the role of the environment in the spread of infection, 199–282. In: Kazda J, Pavlik I, Falkinham III JO, Hruska K (eds.) (2009): *The Ecology of Mycobacteria: Impact on Animal's and Human's Health*. 1st ed. Springer. XVIII, 522 pp.
- Pavlik I, Svastova P, Bartl J, Dvorska L, Rychlik I (2000): Relationship between IS901 in the *Mycobacterium avium* complex strains isolated from birds, animals, humans and the environment and virulence for poultry. *Clinical and Diagnostic Laboratory Immunology* 7, 212–217.
- Quesenberry KE, Jacobson ER, Allen JL, Cooley AJ (1986): Ulcerative stomatitis and subcutaneous granulomas caused by *Mycobacterium chelonae* in a *Boa constrictor*. *Journal of the American Veterinary Medical Association* 189, 1131–1132.
- Rhodin AGJ, Anver MR (1977): Mycobacteriosis in turtles: cutaneous and hepatosplenic involvement in a *Phrynops hilari*. *Journal of Wildlife Diseases* 13, 180–183.
- Roh YS, Park H, Cho A, Islam MR, Chekarova I, Ejaz SE, Lim CW, Kim B (2010): Granulomatous pneumonia in a captive freshwater crocodile (*Crocodylus johnstoni*) caused by *Mycobacterium szulgai*. *Journal of Zoo and Wildlife Medicine* 41, 550–554.
- Slana I, Kaevska M, Kralik P, Horvathova A, Pavlik I (2010): Distribution of *Mycobacterium avium* subsp. *avium* and *M. a. hominissuis* in artificially infected pigs studied by culture and IS901 and IS1245 quantitative real time PCR. *Veterinary Microbiology* 144, 437–443.
- Slany M, Knotek Z, Skoric M, Knotkova Z, Svobodova J, Mrlik V, Moravkova M, Pavlik I (2010): Systemic mixed infection in a brown caiman (*Caiman crocodylus fuscus*) caused by *Mycobacterium szulgai* and *M. chelonae*: a case report. *Veterinarni Medicina* 55, 91–96. <http://www.vri.cz/docs/vetmed/55-2-91.pdf>
- Soldati G, Lu ZH, Vaughan L, Polkinghorne A, Zimmermann DR, Huder JB, Pospischil A (2004): Detection of mycobacteria and chlamydiae in granulomatous inflammation of reptiles: A retrospective study. *Veterinary Pathology* 41, 388–397.

Received: 2011–12–14

Accepted after corrections: 2012–03–24

Corresponding Author:

MVDr. Misa Skoric, Ph.D., University of Veterinary and Pharmaceutical Sciences, Faculty of Veterinary Medicine, Palackeho 1–3, 612 42 Brno, Czech Republic
Tel. +420 541 562 252, +420 606 812 621, E-mail: skoricm@vfu.cz