

Treatment of mange caused by *Caparinia tripilis* in native Korean wild hedgehogs (*Erinaceus amurensis*): a case report

K.Y. EO¹, D. KWAK², O.D. KWON²

¹Seoul Zoo, Gwacheon, Gyeonggi, Republic of Korea

²College of Veterinary Medicine, Kyungpook National University, Daegu, Republic of Korea

ABSTRACT: Infestation of the *Caparinia tripilis* mite in native Korean wild hedgehogs (*Erinaceus amurensis*) is described in this report. Five hedgehogs, including two adult males and three adult females, were rescued from the wild and referred to the Animal Health Centre of the Seoul Zoo, Korea. They were exhibited after completing quarantine. After one year and two months of exhibition, all hedgehogs began scratching, developed powdery deposits around the ears, eyes, and cheeks, and showed loose spines, scurf, and scales on the dorsal lesions. One had pruritic dermatitis on the outer ears and upper chest that resulted from severe scratching using its hind leg claws. The motile powdery deposits around the ears and eyes were visible to the naked eye. Skin was scraped from the lesions and examined by microscopy to diagnose the causative agent. Numerous mites (300–400 µm body length) were observed with three long setae on the third pair of legs, short and unjointed pedicels, and bell-shaped tarsal caruncles. Based on these morphological features, the mites were identified as the non-burrowing *C. tripilis* mite. Treatment was successful after initial administration of 0.4 mg/kg ivermectin *s.c.* and subsequent 0.5 mg/kg *p.o.*, repeated 14 and 28 days after injection. This is the first description of a caparinirosis case in the native Korean wild hedgehog *E. amurensis*.

Keywords: caparinirosis; mange; *Erinaceus amurensis*; native Korean wild hedgehogs; treatment

Caparinirosis in wild hedgehogs caused by *Caparinia* spp. is a common ectoparasitic skin disease in European countries and New Zealand (Sweetman 1962; Brockie 1974; Bexton and Robinson 2003; Stocker 2005). The genus *Caparinia* has the characteristic feature of three long setae at the end of the third or fourth pairs of legs (Kim et al. 2012a). Some cases of hedgehog caparinirosis have been reported at a zoo (Letcher 1988). Caparinirosis in African pygmy hedgehog (*Atelerix albiventris*) exotic pets was reported in Korea and Costa Rica (Kim et al. 2012a; Moreira et al. 2013). Caparinirosis has also been reported in New Mexico and California, USA (Letcher 1988; Staley et al. 1994). However, no previous reports have been published on caparinirosis caused by *Caparinia* spp. in native Korean wild hedgehogs. Only one species of wild hedgehog is native to the Korean peninsula: *Erinaceus amurensis*, which belongs to the genus *Erinaceus*, family Erinaceidae, and order

Erinaceomorpha (Woon 1967; Nowak 1999). Its common English names are Amur hedgehog and Manchurian hedgehog. It is widely distributed in China and the Korean peninsula in forests, grasslands, cultivated areas, or wherever they can find adequate forage (Nowak 1999; Tsytsulina 2008). However, it is not an endangered mammal and is categorised as a least concerned species by the IUCN Red List Threatened Species (Tsytsulina 2008). Hedgehogs have been protected by law in Korea to prevent poaching.

Case description

Five native Korean wild hedgehogs (*E. amurensis*), including two adult males (1450 g and 1400 g) and three adult females (800 g, 850 g, and 950 g), were referred from a local wild animal rescue centre in Gangwon Province, Korea, to the Animal

Health Centre of the Seoul Zoo. After quarantine, they were placed on exhibition in a 78 × 160 × 35 cm double-decked booth at the children's zoo for one year and two months. They were fed once per day with mealworms (*Tenebrio molitor* larvae), apples, carrots, sweet potatoes, and dried pellets (Premium Ferret Diet, ZuPreem, Shawnee Mission, KS, USA). One male hedgehog underwent a health examination because it showed abnormali-

ties including itching, poor appetite, and lethargy. It was examined under anaesthesia using an *i.m.* injection of 0.1 mg/kg medetomidine and 5 mg/kg ketamine. The skin lesions consisted of scurf and scales with loose spines on the entire dorsal surface (Figure 1A). Skin abrasions on the upper chest due to scratching using the hind leg claws and purulent dermatitis on the outer ear canal were observed (Figure 1B–D). When the lesions were examined

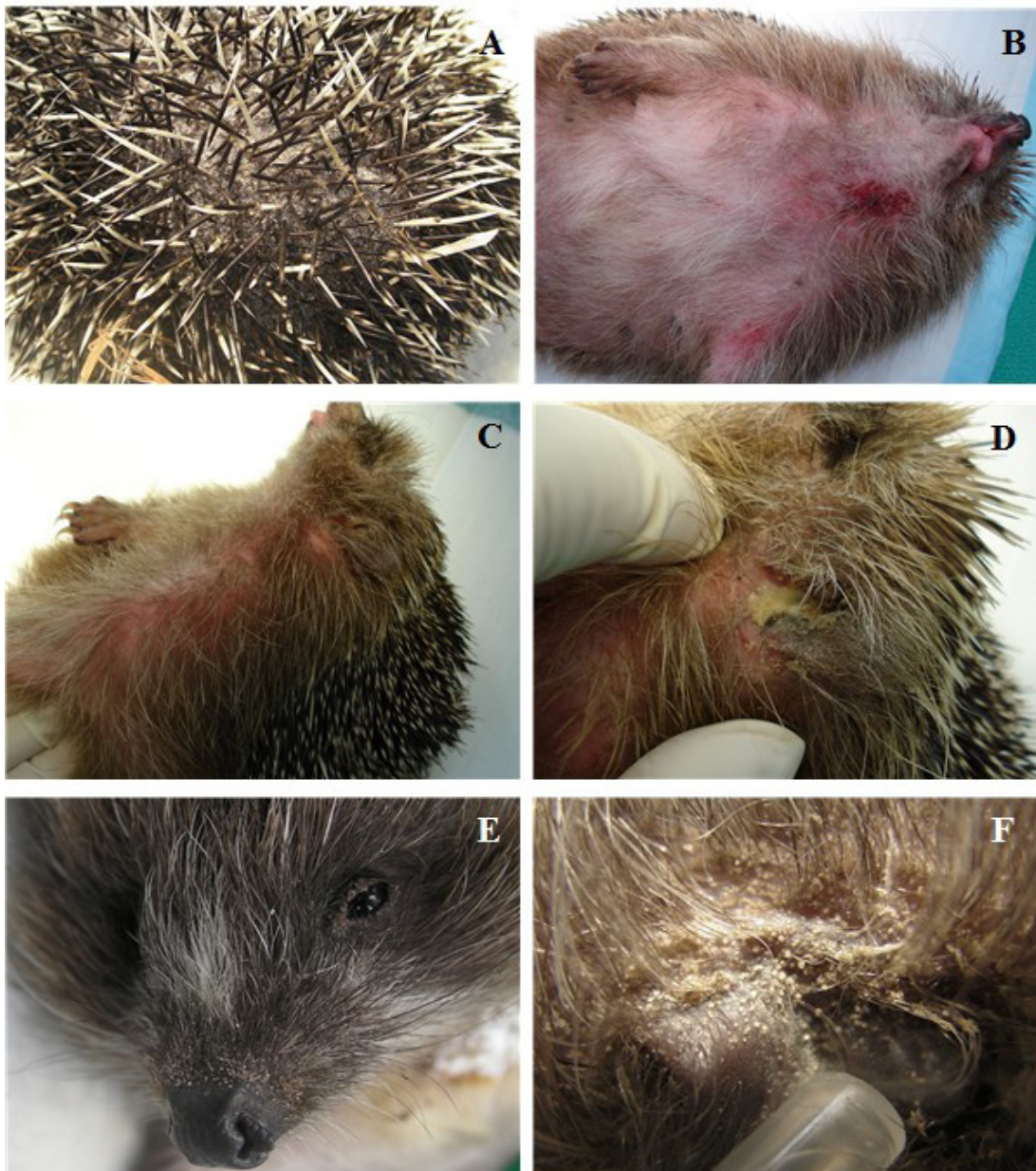


Figure 1. Five native Korean wild hedgehogs (*Erinaceus amurensis*) with various skin lesions. (A) Loose spines, scurf, and scales on the lesions; (B) Self-inflicted traumatic abrasions due to hind leg claw scratching; (C) Skin scratching erythema lesions due to pruritus; (D) Purulent dermatitis on the outer ear canal due to a secondary infection; (E) Motile powdery deposits visible to the naked eye around the ears, cheeks, and eyes; (F) Heavy infestation of ectoparasites behind the ears

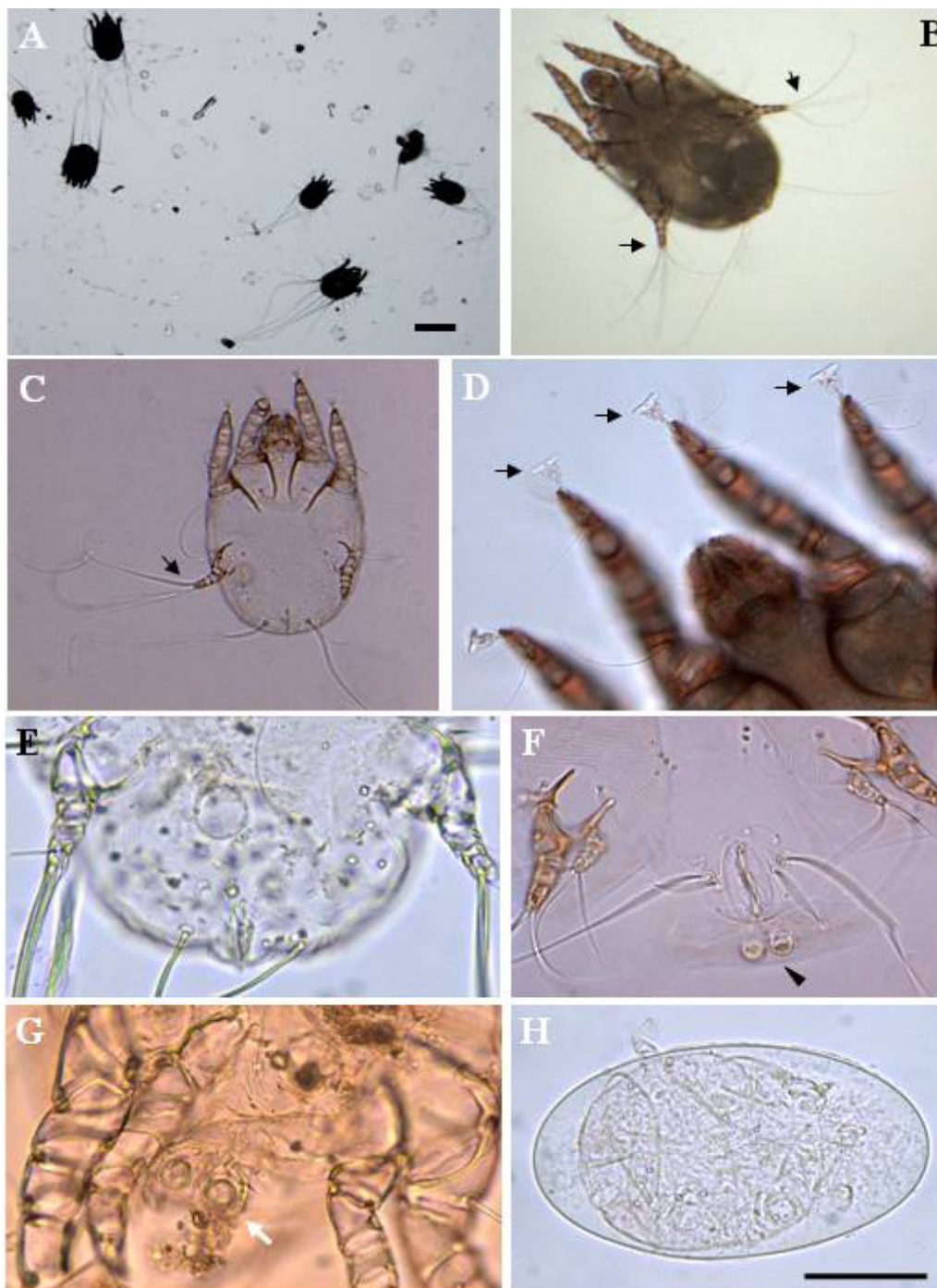


Figure 2. Microscopic examination of the causative non-burrowing mite *Caparinia tripilis*. (A) Numerous mites (300–400 μm body length) (× 4), bar = 200 μm; (B, C) Three long setae (arrows) on the third pair of legs (× 20); (D) A mite with short and unjointed pedicels and bell-shaped tarsal caruncles (arrows, × 40); (E) Ventral view at the posterior end of an adult female; (F) Ventral view of a pubescent female with a couple of copulatory tubercles at the posterior end of the body (arrow head); (G) Ventral view of an adult male with tubercles (white arrow); (H) An embryonated egg, bar = 50 μm

closely, motile powdery deposits were visible to the naked eye around the ears, cheeks, and eyes (Figure 1E, F). The remaining animals were referred to the health center and examined in the same man-

ner. All hedgehogs showed motile powdery deposits on their faces. Skin scrapings were taken from the lesions and examined microscopically for the presence of ectoparasites. Morphological identi-

fication keys for the family Psoroptidae and genus *Caparinia* were used to identify the causative species (Kim et al. 2012a). Numerous mites (300–400 µm body length) (Figure 2A) with three long setae on the third pair of legs (Figure 2B, C), short and unjointed pedicels, and bell-shaped tarsal caruncles, were observed (Figure 2D). In addition, adult male and female mites at different developmental stages, and embryonated eggs were identified (Figure 2E–H). Based on these morphological features, the mite was identified as *C. tripilis*. Recovery was successful after an initial *s.c.* injection of 0.4 mg/kg ivermectin (Baymec, Bayer Korea Co., Seoul, Korea) and subsequent 0.5 mg/kg ivermectin (Heartguard, Estien Co., Seoul, Korea) *p.o.*, repeated 14 and 28 days after the injection. Tardomyocel 10 000 IU/kg + procaine penicillin G 2,500 IU/kg + dihydrostreptomycin sulphate 12 500 IU/kg (Tardomyocel Comp. III, Bayer Korea) and chlorpheniramine maleate (Peniramin inj, Yuhan Co., Seoul, Korea) at 2 mg/kg were administered *s.c.* to a male hedgehog with purulent dermatitis on the outer ear due to a secondary infection and skin abrasions on the upper chest. All bedding, furnishings, and other materials were removed to eradicate the mites in the exhibition booth. The substrate and furnishings were changed twice per week during treatment.

DISCUSSION AND CONCLUSIONS

Hedgehog capariniosis caused by the *C. tripilis* mite has been reported in England and New Zealand (Michael 1889; Brockie 1974). It is characterised by skin lesions, spine loss, hyperkeratosis, seborrhea, and dried scurf at the base of the spines. Other signs include lethargy, decreased appetite, and weight loss. Many cases of capariniosis are subclinical, but seborrhea, crusting, and flaking of the skin, as well as loss of spines are associated with severe cases (Meredith and Johnson-Delaney 2010). Capariniosis is often of little clinical significance; however, severe infestations combined with other problems, including secondary infections, are life-threatening. It often occurs synergistically with dermatophytosis and, on occasion, is more generalised over the entire body (Bexton and Robinson 2003). The clinical findings in the present case were scurf and scales with spine loss on the dorsal surface, and motile powdery deposits were observed around the ears and face upon close inspection.

Purulent dermatitis on the outer ear and erythema and abrasions on the upper chest, which were self-induced, were also observed.

Capariniosis is diagnosed according to the clinical appearance of the skin and detection of the non-burrowing mites, based on microscopic characteristics (Bexton and Robinson 2003). The genus *Caparinia* has the characteristic feature of three long setae at the end of the third or fourth pairs of legs (Kim et al. 2012a). Among five known species of the genus *Caparinia*, only two species, *C. tripilis* and *C. erinacei*, are known to infest hedgehogs. *C. tripilis* can burrow into the skin of hedgehogs, form clusters on its hosts, and shows higher pathogenicity in conjunction with a secondary infection.

The hedgehogs were treated with ivermectin, initially by *s.c.* injection but at the second and third administration orally, to relieve stress due to restraint and injection of the animals. To lessen the inflammation and itching in one male hedgehog, antibiotics together with an antihistamine were administered. Treatment options can include ivermectin, selamectin, and fipronil spray (Meredith and Johnson-Delaney 2010). A combination of 10% imidacloprid and 1% moxidectin spot-on for cats was useful for the control of *C. tripilis* in the African pygmy hedgehog (Kim et al. 2012b). Two rinses with 0.03% amitraz (Mitaban, Upjohn Co., Kalamazoo, MI, USA) at one-week intervals is also effective (Letcher 1988).

Mite infestations with *Caparinia* spp. or *Chorioptes* spp. are very common in hedgehogs (Brockie 1974; Bexton and Robinson 2003; Meredith and Johnson-Delaney 2010). However, no study has been conducted on mite infestation of wild hedgehogs in Korea. The source of the *C. tripilis* in the present case was uncertain. This is the first description of a mite infestation in native Korean wild hedgehogs, and therefore, further surveys are necessary to assess infestations of capariniosis in hedgehogs in Korea.

REFERENCES

- Bexton S, Robinson I (2003): Hedgehogs. In: Mullineaux E, Best D, Cooper JE (eds.): BSAVA Manual of Wildlife Casualties. 2nd ed. 49–65.
- Brockie RE (1974): The hedgehog mange mite, *Caparinia tripilis*, in New Zealand. New Zealand Veterinary Journal 22, 243–247.
- Kim DH, Oh DS, Ahn KS, Shin SS (2012a): An outbreak of *Caparinia tripilis* in a colony of African pygmy

doi: 10.17221/7927-VETMED

- hedgehogs (*Atelerix albiventris*) from Korea. Korean Journal of Parasitology 50, 151–156.
- Kim KR, Ahn KS, Oh DS, Shin SS (2012b): Efficacy of a combination of 10% imidacloprid and 1% moxidectin against *Caparinia tripilis* in African pygmy hedgehog (*Atelerix albiventris*). Parasites and Vectors 5, 1–8.
- Letcher JD (1988): Amitraz as a treatment for acariasis in African hedgehogs (*Atelerix albiventris*). Journal of Zoo Animal Medicine 19, 24–29.
- Meredith A, Johnson-Delaney C (2010): African pygmy hedgehogs. In: BSAVA Manual of Exotic Pets. 5th ed. 139–147.
- Michael AD (1889): On some unrecorded Parasitic Acari found in Great Britain. Journal of the Linnean Society of London, Zoology 20, 400–406.
- Moreira A, Troyo A, Calderon-Arguedas O (2013): First report of acariasis by *Caparinia tripilis* in African hedgehogs, (*Atelerix albiventris*), in Costa Rica. Revista Brasileira De Parasitologia Veterinaria 22, 155–158.
- Nowak RM (1999): Walker's Mammals of the World. 6th ed. The Johns Hopkins University Press, Baltimore. 174–179.
- Staley EC, Staley EE, Behr MJ (1994): Use of permethrin as a miticide in the African hedgehog (*Atelerix albiventris*). Veterinary and Human Toxicology 36, 138.
- Stocker L (2005): Hedgehogs. In: Practical Wildlife Care. 2nd ed. Blackwell Publishing, Oxford. 200–215.
- Sweatman GK (1962): Parasitic mites of non-domesticated animals in New Zealand. New Zealand Entomologist 3, 15–23.
- Tsytulina K (2008): *Erinaceus amurensis*. The IUCN Red List of Threatened Species. Version 2014.1. Downloaded on 08 July 2014.
- Woon PH (1967): Family Erinaceidae. In: Illustrated Encyclopedia of Fauna and Flora of Korea. Vol 7. Mammals. Ministry of Education, Seoul. 261–266.

Received: 2014–08–11

Accepted after corrections: 2014–11–14

Corresponding Author:

Oh-Deog Kwon, Kyungpook National University, College of Veterinary Medicine, Buk-gu, Daegu 702-701, Republic of Korea; E-mail: odkwon@knu.ac.kr
