



Case Report:

Subdural Hematoma in Grave's Disease Induced Thrombocytopenia.

Authors

Sunil Kumar, Associate Professor, Department of Medicine,
Sanjay Diwan, Professor, Department of Medicine,
Shailee Chandek, Resident, Department of Medicine,
Pratik Nitey, Resident, Department of Medicine,
Anand Kakani, Professor, Department of Neurosurgery,
Jawahar Lal Nehru Medical College, DMIMSU, Sawangi, Wardha, India.

Address for Correspondence

Dr. Sunil Kumar,
Associate Professor,
Department of Medicine,
DMIMS, Sawangi,
Wardha, India.
E-mail: sunilkumarmed@gmail.com

Citation

Kumar S, Diwan S, Chandek S, Nitey PO, Kakani A. Subdural Hematoma in Grave's Disease Induced Thrombocytopenia. *Online J Health Allied Scs.*2012;11(4):17. Available at URL: <http://www.ojhas.org/issue44/2012-4-17.html>

Open Access Archives

<http://cogprints.org/view/subjects/OJHAS.html>
<http://openmed.nic.in/view/subjects/ojhas.html>

Submitted: Nov 3, 2012; Accepted: Jan 6, 2013; Published: Jan 25, 2013

Abstract: Subdural hematoma (SDH) usually occurs secondary to trauma, in bleeding disorders it may occur spontaneously. It is a rare complication of immune thrombocytopenia. Here we report a case of 45 years female presenting with complaints of headache, palpitation and menorrhagia and later diagnosed to be a case of Grave's disease with thrombocytopenia with sub dural hematoma. No such case reports are available in literature.

Key Words: Subdural hematoma; Thrombocytopenia; Hyperthyroidism; Graves disease.

Introduction

Subdural hematoma (SDH) usually occurs secondary to trauma, in bleeding disorders it may occur spontaneously. It is a rare complication of immune thrombocytopenia.¹ Mild thrombocytopenia is frequently observed in patients with Graves' disease.² It is estimated that there is Graves disease in 8-14% of the patients with idiopathic thrombocytopenic purpura and 43% of the untreated hyperthyroid cases have platelet count below 150.000/cumm.³ Here we report a case of 45 years female presenting with complaints of headache, palpitation and oligomenorrhoea and later diagnosed to be a case of graves disease with thrombocytopenia with sub dural hematoma. No such case reports are available in literature.

Case Report

A 45 years old female presented in medicine out patient department of this hospital with complaints of headache since 3 months, palpitation since 2 months and irregular menstruation since 4 cycles. Headache was intermittent, right sided, throbbing type associated with episodes of vomiting. She also had significant weight loss since 5-6 months. On history, patient also complains of diplopia since 15 days. There was no history of hypertension, diabetes mellitus, and pulmonary tuberculosis. On examination her pulse was 130bpm regular and blood pressure of 126/70mm Hg. She had diffuse swelling in neck region. Her investigation revealed hemoglobin 7.6gm/dL, with peripheral smear

suggestive of normocytic normochromic red blood cells and absolute platelet count of 29000/cumm. Her thyroid profile was free T3 517ng/dL, free T4 >13µg/dL and TSH 0.13µiu/ml. Fine needle aspiration cytology from thyroid was suggestive of nodular goitre. Her thyroid peroxidase antibody (TPO) was > 600, suggestive of Grave's disease. Her fundus examination revealed early papilloedema. Her MRI brain revealed subdural bleed extending from high parietal to occipital region in different stages more on right side with mild cerebral edema (Figure 1). Patient was taken for right fronto-parietal burr hole and about 50cc of altered coloured liquefied blood drained from sub dural space. She was given Mannitol and injection Dexamethasone. She was put on Carbimazole 40mg once a day and Propranolol 40mg once a day. Patient responded to treatment and the platelet count increased to 2.8lacs/cumm. The final diagnosis was Grave's disease with anaemia and autoimmune thrombocytopenia. She responded well to treatment and doing well on follow up.

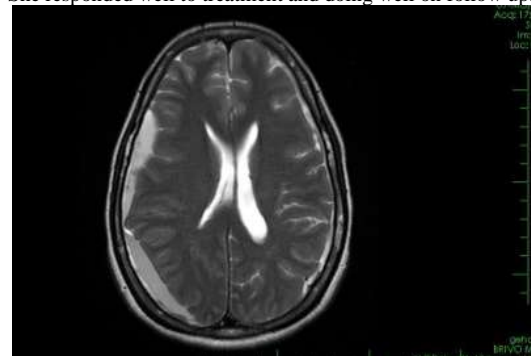


Figure 1: MRI brain showing subdural bleed extending from high parietal to occipital region with mild cerebral edema

Discussion

Association between hyperthyroidism particularly autoimmune thyroid disorder like grave's disease and thrombocytopenia is uncommon but well known entity.² Several mechanisms have been described to explain thrombocytopenia in hyperthyroidism. There may be shorter life span and increased platelet turnover during the hypermetabolic state due to increased splenic clearance and reticuloendothelial phagocytic activity.^{4,5} An immunologic phenomenon is another mechanism to explain thrombocytopenia in hyperthyroidism, particularly in autoimmune thyroid disease. Platelet autoantibodies or anti-platelet immunoglobulin G was observed in 83% of thrombocytopenic patients who also had Graves' and Hashimoto's thyroiditis. Among those with autoimmune thyroid disease without thrombocytopenia, platelet antibodies were seen in 10%. The autoantibodies demonstrated included platelet-associated immunoglobulin G (PAIg) and platelet autoantibodies IgG directed against glycoprotein Ib and glycoprotein IIb/IIIa located on the platelet surface.⁶ In our case, a high level of TPO suggested the diagnosis of Grave's disease and thrombocytopenia was probably immunological, as it responded with carbimazole. Platelet-specific immunoglobulin was not measured due to non affordability. Its value in diagnosis is, however, limited due to the low sensitivity and specificity of the tests.⁷ If the platelet count decreases to less than 20,000/ μ l, Intracerebral haematoma or subarachnoid haemorrhage is more frequently reported. Subdural haematoma usually occurs as an extension of a parenchymal bleed. Isolated subdural haematoma is an extremely rare entity in immune thrombocytopenia. So far, only very few cases have been reported in the literature.^{1,8,9} The basic pathology in thrombocytopenia is proposed to be capillary leak and this may become confluent in severe cases, leading to frank intracerebral haematoma. Because of the absence of associated parenchymal injury, the outcome may be better in non-traumatic subdural haematoma. For the same size of subdural haematoma, chances of complications like brain oedema and herniation may be less in non-traumatic SDH. However in this case there was papilloedema which may be due to brain edema and increased intracranial pressure thus necessitating neurosurgical intervention.

Conclusion

An association between thrombocytopenia and hyperthyroidism/Grave's disease exists. Platelet abnormalities can be a direct effect of a hypermetabolic state or due to an autoimmune process similar to autoimmune thyroid disease. Resolution of thrombocytopenia occurs with normalization of thyroid functions. Subdural hematoma may be the cause of headache in some cases of Grave's disease.

References

1. Sreedharan PS, Rakesh S, Sajeev S, Pavithran K, Thomas M. Subdural haematoma with spontaneous resolution—rare manifestation of idiopathic thrombocytopenic purpura. *J Assoc Physicians India* 2000;48:432-434.
2. Brent GA. Graves' disease. *N Engl J Med* 2008;358:2594-2605.
3. Liechty RD. The thyrotoxicosis-thrombocytopenia connection. *Surgery* 1983;94:966-968.
4. Cheung E, Liebman HA. Thyroid disease in patients with immune thrombocytopenia. *Hematol Oncol Clin N Am* 2009;23:1251-1260.
5. Gill H, Hwang YY, Tse E. Primary immune thrombocytopenia responding to antithyroid treatment in a patient with Graves' disease. *Ann Hematol* 2011;90:223-224.
6. Cordiano I, Betterle C, Spadaccino CA, Soini B, Girolami A, Fabris F. Autoimmune thrombocytopenia (AITP) and thyroid autoimmune disease (TAD): overlapping syndromes? *Clinical and Experimental Immunology* 1998;113:373-378.
7. Konkle BA. Disorders of the platelets and vessel wall. In: Longo DL, Fauci AS, Kasper DL, Hauser SL, Jameson JL ed. *Harrison's principles of internal medicine*, 18th edn. New York: McGraw-Hill Inc, 2012. p. 968.
8. Seçkin H, Kazanci A, Yigitkanli K, Simsek S, Kars HZ. Chronic subdural haematoma in patients with idiopathic thrombocytopenic purpura: A case report and review of the literature. *Surg Neurol*. 2006;66:411-414.
9. Chatterjee S, Karmakar PS, Ghosh P, Ghosh A. Subdural hematoma associated with immune thrombocytopenic purpura in two different clinical settings. *J Assoc Physicians India*. 2010 Aug; 58:504-506.