



Case Report:

Sebaceous Carcinoma of the Eyelid

Authors

Ajay Kamath R, Manjunath Kamath M, Gurudutt Kamath M, Madhurima Nayak A,
Department of Ophthalmology, Kasturba Medical College, Mangalore.

Address for Correspondence

Dr. Ajay R Kamath,

1402, Westwind Apartments,

Collector's Gate, Balmatta,

Mangalore - 575002,

Karnataka, India.

E-mail: ajayrkamath@yahoo.com

Citation

Kamath AR, Kamath MM, Kamath GM, Nayak MA. Sebaceous Carcinoma of the Eyelid. *Online J Health Allied Scs.*2013;12(2):16.
Available at URL: <http://www.ojhas.org/issue46/2013-2-16.html>

Open Access Archives

<http://cogprints.org/view/subjects/OJHAS.html>

<http://openmed.nic.in/view/subjects/ojhas.html>

Submitted: May 27, 2013; Accepted: Jul 5, 2013; Published: Aug 25, 2013

Abstract: Sebaceous gland carcinoma of the eyelid is a very rare, slow growing tumor arising from the meibomian glands. In contrast to squamous cell carcinoma and basal cell carcinoma which arise frequently from the lower lid, sebaceous carcinoma arises from the upper lid where meibomian glands are more numerous. We present a case of sebaceous carcinoma in an elderly lady who presented with a slow growing tumor in the lateral third of the lower lid, without any lymph node metastasis. The tumor was treated by wide excision and the eyelid was reconstructed by Tenzel semilunar flap.

Key Words: Sebaceous carcinoma; Lower lid malignancy; Reconstruction of lid; Tenzel semilunar flap

Introduction

Carcinoma of Sebaceous glands is a highly malignant and potentially lethal tumor that arises from the meibomian glands of the tarsal plate, from glands of Zeiss or sebaceous glands of caruncle, periocular skin and eyebrow. It forms 1-5.5% of eyelid malignancies.⁽¹⁾ It usually presents in elderly women, with a predilection for the upper lid as there are more number of meibomian glands than in the lower lid.⁽¹⁾ The clinical suspicion of Sebaceous gland carcinoma (SGC) is quite difficult as it may simulate a benign tumor or blepharconjunctivitis. Its ability to cause skip lesions and intraepithelial spread gives the tumor a special place among other lid tumors.

Case report:

A 52 years old woman presented with a slow growing mass in the left lower lid, which had gradually progressed over the last six months. Ocular examination revealed an ulcerative growth over the outer third of the left lower eye lid margin, measuring 1.5cm involving marginal conjunctiva. It showed yellowish discoloration over the ulcerated surface and lashes were absent [Fig 1]. There was no corneal or conjunctival involvement. There was no local lymphadenopathy. She underwent a wide excision of the tumor under local

infiltration. A full thickness excision with 5mm of clinically normal tissue was performed. A semilunar flap was raised temporal with concavity inferiorly and edges were sutured. The excised tissue was sent for histopathological examination. Sections showed tumor arising from the epidermis and infiltrating dermis in nests of folliculocentric pattern. The cells had vacuolated cytoplasm and moderately pleomorphic hyperchromatic nuclei suggestive of sebaceous carcinoma [Fig 2]. She was followed up. One month later, the flap was taken up well and there was no recurrence.

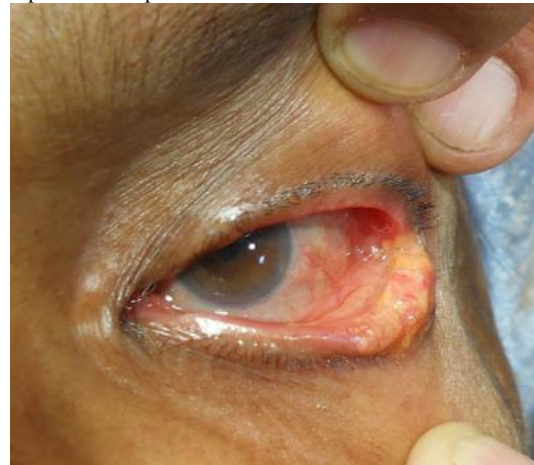

Fig 1: Left lower eye lid mass lesion

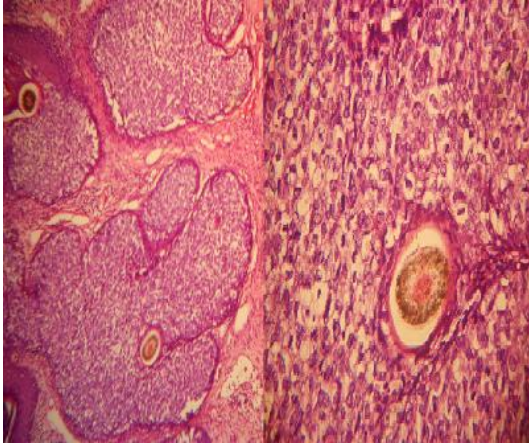


Fig 2: Vacuolated cytoplasm and moderately pleomorphic hyperchromatic nuclei suggestive of sebaceous carcinoma

Discussion:

Meibomian glands are modified sebaceous glands embedded within Tarsal plates. They are about 25 in number in the upper lid and 20 in the lower lid. Sebaceous carcinomas are second most common malignancies of the eyelid⁽²⁾ and arise from meibomian glands. These tumors often masquerade as benign eyelid diseases like chalazia, chronic blepharitis, basal cell or squamous cell carcinoma, ocular cicatricial pemphigoid or superior limbic keratoconjunctivitis. It causes effacement of the meibomian gland orifices with destruction of follicles of cilia and loss of lashes.

In general, there are two pathological presentations of sebaceous carcinoma- nodular and spreading. More than 50% cases may present as a pseudochalazion or chronic blepharoconjunctivitis.⁽³⁻⁵⁾ The nodular variant is usually a hard, immobile nodule in the upper tarsal plate. Any chalazion which recurs more than three times after incision and curettage should be biopsied to rule out sebaceous carcinoma.⁽⁶⁾ The tumor can also present as a spreading variety with diffuse infiltration of the skin.⁽⁷⁾ Pagetoid spread refers to extension of tumor into the epithelium which may simulate an inflammatory condition. Map biopsies are helpful in detecting such variants.

Treatment of sebaceous carcinoma is primarily surgical. It may range from excision to exenteration. They have a 30% chance of recurring after excision.⁽⁸⁾ Wide excision is mandatory for adequate treatment. Good outcome has been reported with 4mm surgical margins.⁽⁹⁾ Mohs micrographic surgery is a common and effective method of treatment. Reconstruction depends on the amount of tissue to be excised. Small defects can be reconstructed by direct closure. Larger tumors require lid reconstructions using tissue flaps like Tenzel semilunar flap and Muster demucocutaneous flap. Other modalities of treatment are Mitomycin C, Cryotherapy and Radiotherapy.⁽⁶⁾ Lymph node metastasis requires radical neck dissection.

References:

1. Ni C, Kou PK. Meibomian gland carcinoma: A clinicopathological study of 156 cases with long-period follow up of 100 cases. *Jpn J Ophthalmol.* 1979;23:388–401
2. McLean IW, Jakobiec FA, Zimmerman LE, Burnier MM. Tumours of the Eye and Ocular Adnexa, Vol 3. Maryland Armed Forces Institute of Pathology: Washington, 1993. pp 28–35
3. Foster CS, Allansmith MR. Chronic unilateral blepharoconjunctivitis caused by sebaceous carcinoma. *Am J Ophthalmol.* 1978;86:218–220.

4. Sweebe EC, Cogan DG. Adenocarcinoma of the meibomian gland; a pseudochalazion entity. *Arch Ophthalmol* 1959;61:282–290.
5. Condon GP, Brownstein S, Codère F. Sebaceous carcinoma of the eyelid masquerading as superior limbic keratoconjunctivitis. *Arch Ophthalmol.* 1985;103:1525–1529.
6. Wali UK, Mujaini A. Sebaceous gland carcinoma of the eyelid. *Oman J Ophthalmol.* 2010 Sep-Dec;3(3):117–121
7. Zurcher M, Hinstchich CR, Garner A, Bunce C, Collin JR. Sebaceous carcinoma of the eyelid: A clinicopathological study. *Br J Ophthalmol.* 1998;82:1049–1055.
8. Epstein GA, Putterman AM. Sebaceous adenocarcinoma of the eyelid. *Ophthalmic Surg.* 1983;14:935–940
9. Muqit MMK, Roberts F, LeeWR, Kemp E. Improved survival rates in sebaceous carcinoma of the eyelid. *Eye.* 2004;18:49–53.