



Case Report:

Perineal Aggressive Angiomyxoma: A Rare Presentation.

Authors

Ravi N Patil, Nivedita Reshme, Rajshekar Kundargi,
Bangalore Baptist Hospital, Hebbal, Bangalore-560094, India.

Address for Correspondence

Dr. Ravi N Patil,
Bangalore Baptist Hospital,
Hebbal, Bangalore-560024, India.
E-mail: ravi2varsha@yahoo.co.in

Citation

Patil RN, Reshme N, Kundargi R. Perineal Aggressive Angiomyxoma: A Rare Presentation. *Online J Health Allied Scs.* 2013;12(1):11. Available at URL:<http://www.ojhas.org/issue45/2013-1-11.html>

Open Access Archives

<http://cogprints.org/view/subjects/OJHAS.html>
<http://openmed.nic.in/view/subjects/ojhas.html>

Submitted: Mar 24, 2013; Accepted: Apr 4, 2013; Published: Apr 15, 2013

Abstract: Aggressive angiomyxoma(AA) is defined as benign neoplasm but has infiltrative potential into skeletal muscle and fat. Aggressive angiomyxoma is a rare neoplasm with about 150 reported cases so far. It is most often found in women in reproductive age with a peak incidence in the fourth decade of life. Aggressive angiomyxoma is most often found in or in proximity to the lower pelvis, more specifically perineum, vulva, vagina or inguinal regions. Most AA are big, often more than 10 cm in largest diameter. Radical surgery with wide margins is the treatment of choice. The prognosis is very good here. Because of its rarity and unique presentation we are reporting a case of a huge perineal AA in a 42 years female which presented as a tumour coming out of the breach in skin. She underwent surgery, wide local excision and after 7 months follow-up is free of tumor.

Key Words: Aggressive angiomyxoma; Vulva; Benign; Surgery

Introduction:

Aggressive Angiomyxoma (AA) is a soft tissue neoplasm. The term AA was not coined until 1983 but similar tumours were described as early as in the 1860ies. It is defined as benign but has infiltrative potential into skeletal muscle and fat. Only 2 cases with metastatic disease have been published. AA is a rare neoplasm with about 150 reported cases. It is most often found in women in reproductive age with a peak incidence in the fourth decade of life.(1) The female: male ratio is 6:1.(1) The median age of presentation is 36 years.

AA is most often found in or in proximity to the lower pelvis, more specifically perineum, vulva, vagina or inguinal regions. The majority of patients present with a slow-growing mass which is otherwise asymptomatic and this is frequently the only symptom/sign. Observed accompanying symptoms and signs are regional pain, a feeling of local pressure, or dyspareunia. Tumor size is often underestimated by physical examination.(1,2)

Most AA are big, often more than 10 cm in largest diameter and can reach up to 40cms.(1-3) These tumors are

macroscopically lobulated and may adhere to surrounding soft tissue. Microscopically, cells with a spindle or stellate morphology are seen, embedded in a loose matrix consisting of wavy collagen and edema. Cellularity is generally low to moderate. Infiltration into fat, muscle, and nerves is seen. The hallmark of AA is vessels of varying calibre haphazardly scattered throughout the tumour parenchyma, whereas mitotic figures are scarce. Immunohistochemically, most AA are positive for desmin, smooth muscle actin, muscle-specific actin, vimentin, oestrogen receptor, and progesterone receptor. Some tumours are positive for CD34, whereas S100 is invariably negative. Chromosomal translocation of the 12q13-15 band involving the HMGA2 gene has been described.(1,2)

Case Report:

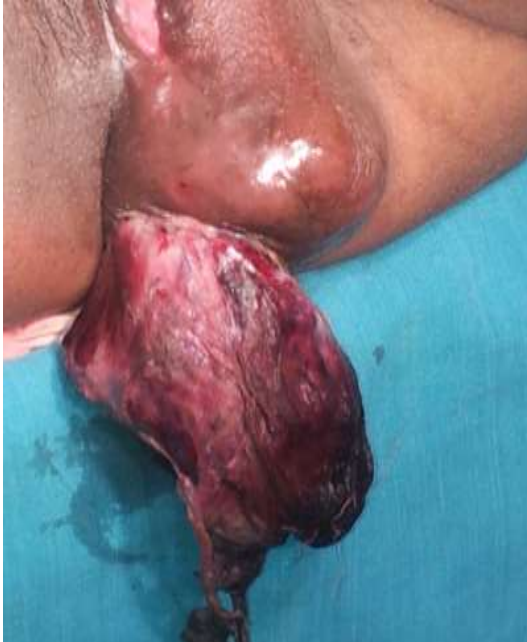A 42 years old married lady came with history of swelling in the perineal region from past 2 years gradually increasing in size. It was a small marble in size in the beginning, and slowly increasing in size and presently reached the size of an orange. From past few months it has been rapidly growing. From past 2 days there has been a small wound over the swelling and minimal bleeding. No history of urinary disturbances or bowel disturbances. From past one month she has got localized pain over the swelling and on sitting.

On examination she had a firm to hard nodular swelling involving left labia majora, minor, and lower perianal area on left side measuring about 14/8/5 cms with a breach in the skin near lower part around 1.5/1.5 cms. A small part of tumor was protruding out of the breeched skin. Surface was smooth, lobulated and non tender. Tumor was gelatinous and fleshy but surprisingly no bleeding on biopsy. Within 3 days after this she came with same tumor totally coming out the breeched skin. The swelling over the labia had reduced. Surface was irregular and rugged as shown in picture (Picture1) with pain. Emergency investigations were done and she was posted for emergency surgery. There were no enlarged groin lymph nodes.

Tumor was excised with wide free margin. It was seen as if arising from fascia covering perianal muscles. Post surgery picture is as shown in Picture2. Postoperative period was uneventful with little infection and superficial wound gaping. It healed well with secondary intention.

Biopsy report was initially benign fibro epithelial tissue with many vessels. Review of slides at Kidwai Memorial Institute of Oncology showed it to be AA. The microscopic pictures are as shown in the pictures (Pictures 3,4,5).

8 months follow up has been done without any events. Lady is comfortable and doing well without any local recurrence.



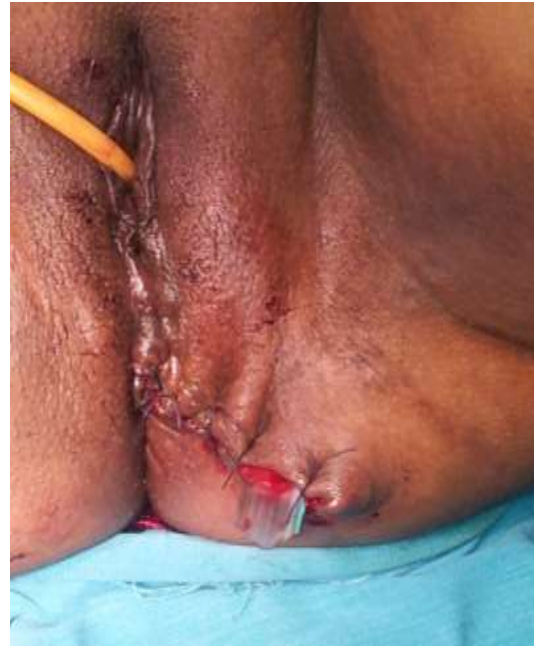Picture 1: Pre operative lesion

Discussion:

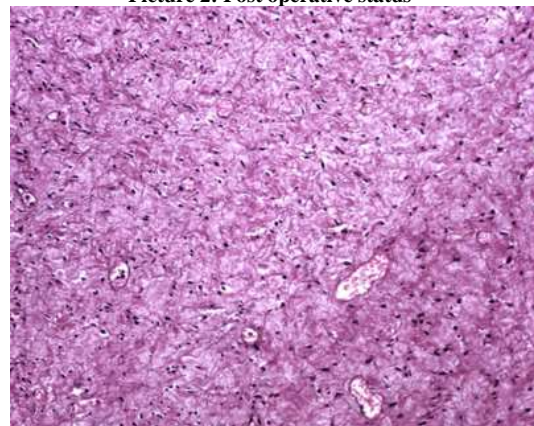
AA is a rare benign and locally infiltrative tumor. Local resection with wide margins is the main stay of treatment in all cases. Local radiotherapy is usually used for recurrent cases or margin positive cases. Radiotherapy and hormonal therapy is not fully established.

Copolla et al has reported a series of 14 cases in their institution, 8 primary and 6 recurrent cases.(3) Extensive visceral resections were done to remove the tumor as they had deep infiltration and 7 received radiotherapy. All were disease free at the end of 69 months of follow-up. Size of the tumors ranged from 3-44cms.

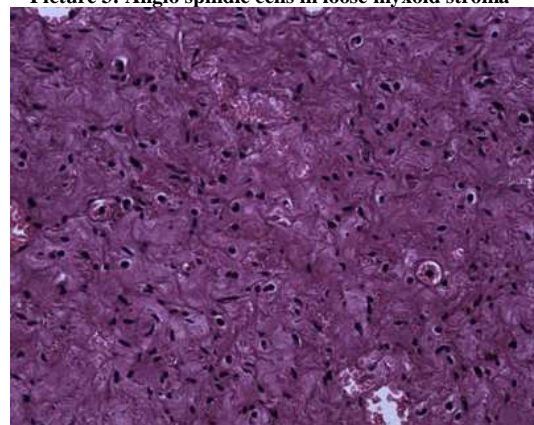
Behranwala KA et al reported seven cases of AA and proved the importance of wide local margin excision. Without free margin, recurrence was common and 4 out of 7 patients with margin positivity developed recurrence in the range of 6 and 97 months.(4)



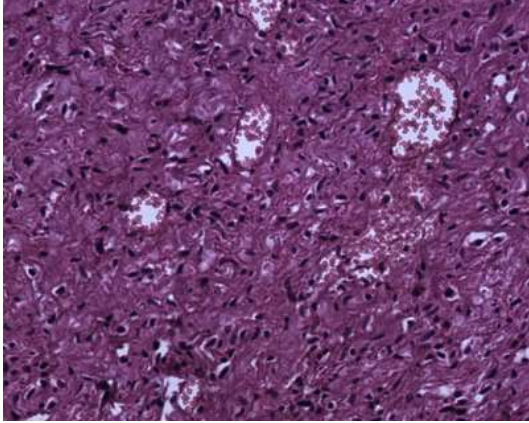
Picture 2: Post operative status



Picture 3: Angio spindle cells in loose myxoid stroma



Picture 4: Angio Spindle cells, no pleomorphism or mitosis



Picture 5: Angio vascular stroma with extravasated RBC.

Mehrzaad Sadaghiani M et al has reported a similar case with a red fleshy mass coming out of left labia majora.(5)

Steeper TA et al reported a series of 9 cases, of which 4 cases had recurrence. No one had radiotherapy(6).

Here in our case, the tumor presented as a tumor coming out of the breach in skin and was seen to be arising from the fascia covering peri-anal muscles. Local wide excision with tumor free margin was done. She is free of tumor after 8 months of follow up.

So in conclusion, AA is a benign aggressive tumor which can reach upto 44cms in size. The treatment is mainly wide local excision. Radiotherapy and hormonal therapy are not fully established.

References:

1. Micci F, Brandal P . Soft Tissue Tumors: Aggressive angiomyxoma. *Atlas Genet Cytogenet Oncol Haematol*. April 2007;11(4):340-343. Available at <http://documents.irevues.inist.fr/bitstream/handle/2042/16967/04-2007-AggresAngiomyxomaID5203.pdf>.
2. Kempson RL, Teixeira MR, Hendrickson MR. Tumors of the Vulva - Mesenchymal tumours. In: Travasolli F A, Devilee P. (Eds). World Health Organization Classification of Tumors - Pathology and Genetics of Tumours of the Breast and Female Genital Organs. IARC Press; Lyon. 2003. pages 328-329. Available at <http://www.iarc.fr/en/publications/pdfs-online/pathogen/bb4/bb4-chap7.pdf>.
3. Coppola S, Desai A, Tzania D et al. Conservative En Bloc Surgery for Aggressive Angiomyxoma Achieves Good Local Control: Analysis of 14 Patients From a Single Institution. *Int Journ of Gynecol Cancer*. 2013;23:540-545.
4. Behranwala KA, Thomas JM. 'Aggressive' angiomyxoma: a distinct clinical entity. *Eur J Surg Oncol*. 2003;29(7):559-563.
5. Sadaghiani MM, Nazari F, Atashkoei S. Aggressive Angiomyxoma of the Vulva: a Case Report. *Shiraz E-Medical Journal*. 2009;10(4):231-235.
6. Steeper TA, Rosai J. Aggressive angiomyxoma of the pelvis and perineum: report of nine cases of a distinctive type of gynaecologic soft tissue neoplasm. *Am J Clin Pathol*. 1983;7:463-475.