



### **Case Report:**

## **Metastatic Leiomyosarcoma of Small Intestine**

### **Authors**

**Rajshekar SK**, Department of Gynaec-Oncology,  
**Guruprasad B**, Post Graduate Trainee, Department of Medical Oncology,  
**Sandip Ganguly**, Post Graduate Trainee, Department of Medical Oncology,  
**Praveen Rathod**, Asst Professor, Department of Gynaec-Oncology,  
**Bafna UD**, Professor and Head, Department of Gynaec-Oncology,  
**Kidwai Memorial Institute of Oncology, Bangalre, India.**

### **Address for Correspondence**

#### **Dr Guruprasad B**

PG Hostel Room No 108,  
Kidwai Memorial Institute of Oncology,  
Dr MH Marigowda Road,  
Bangalore - 560029,  
India.

**E-mail:** guru02doc@yahoo.co.in

### **Citation**

Rajshekar S, Guruprasad B, Ganguly S, Rathod P, Bafna UD. Metastatic Leiomyosarcoma of Small Intestine. *Online J Health Allied Scs.* 2013;12(2):18 Available at URL: <http://www.ojhas.org/issue46/2013-2-18.html>

### **Open Access Archives**

<http://cogprints.org/view/subjects/OJHAS.html>

<http://openmed.nic.in/view/subjects/ojhas.html>

Submitted: Jan 4, 2013; Accepted: Jun 2, 2013; Published: Aug 25, 2013

**Abstract:** This is the report of a case of primary leiomyosarcoma of the small intestine, an uncommon primary malignancy of the small intestine.

**Key Words:** Leiomyosarcoma; Gastro intestinal stromal tumor

### **Introduction**

Small intestine represents 75% of total length of the gastrointestinal tract, yet rarely does this region develop malignant tumors. Approximately 2% of malignancies in the gastrointestinal tract arise from small intestine. (1) Prior to the days of immunohistochemistry, leiomyosarcomas used to be diagnosed abundantly. However with the advent of immunohistochemistry, many leiomyosarcomas are now being diagnosed as Gastro intestinal stromal tumor (GIST). At present leiomyosarcomas are uncommon and comprise only 3% of all primary malignancies in the small intestine. (2)

### **Case Report**

A 53 years old multiparous woman presented in the hospital with dull aching lower abdominal pain of one week duration. The pain was intermittent without any specific aggravating or relieving factors. She had undergone total abdominal hysterectomy (TAH) one year back in view of dysmenorrhoea. Histopathological examination revealed multiple leiomyomas of fibroid with chronic endocervicitis. She didn't have any comorbid illness and her family history was insignificant.

On examination, her performance status was 1 (ECOG scale). General physical examination was unremarkable. Per abdominal examination revealed no obvious mass. Pelvic examination however revealed a mass measuring about 10x10x15 cm in right adnexa with extension into the recto sigmoid region. Bilateral parametrium were free. Rest of the systemic examinations were within normal limits.

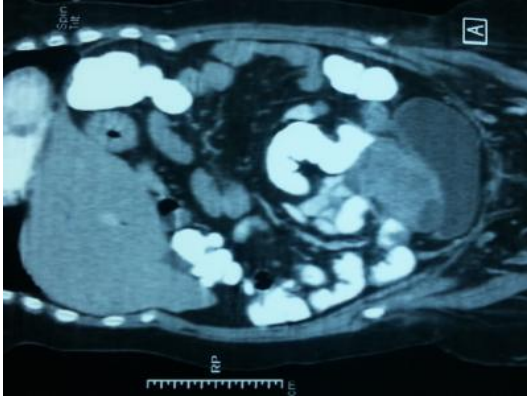
Labs reveal a mildly elevated CA-125 level of 63 IU/ml, while CEA was within normal limits. Rest of the blood parameters were normal. Computed tomography (CT) scan revealed a large solid mass (Figure 1) is seen in pelvis more on right side and posterior to urinary bladder. Mass measured 9.5x9.2 cm with one of the ileal loop is seen adherent to the mass. The mass showed heterogenous enhancement and small cystic components. There was a small separate nodule just superior to the mass on the left side measuring 3.2x3.5 cm adherent to the bladder.

A provisional diagnosis of ovarian neoplasm was made and she underwent laparotomy. Intra operative findings revealed 12x10x10 cm solid vascular mass arising from the serosal surface of terminal ileum with multiple peritoneal deposits. There were tumor deposits in right ovary with rest of the ovary being normal. Rest of the findings were essentially being normal. The mass was resected following which ileal anastomosis was made. She also underwent bilateral oophorectomy.

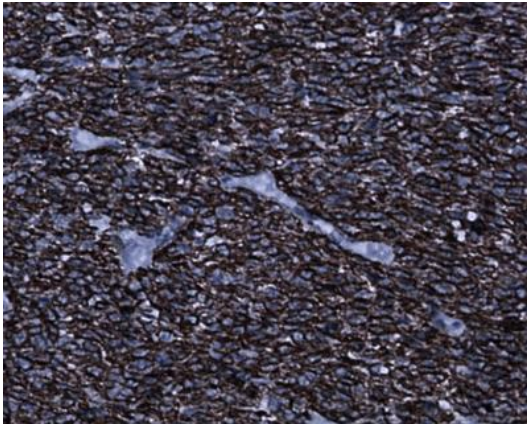
Histopathological examination revealed high grade spindle cell neoplasia with foci of haemorrhage, necrosis and high mitotic activity (>10/hpf) and infiltrating into the ileal mucosa. Foci of pleomorphic cells were also noted. The tumor margin was free of tumor. Right ovary shows tumor deposits and fallopian tube was normal. In view of spindle cells, immunohistochemistry was advised.

Immunohistochemistry studies revealed the neoplastic cells were positive for desmin, caldesmin and smooth muscle antigen (Figure 2). However the tumor cells were negative for CD 117 (Figure 3), DOG 1, S100, CD 34 and calretinin. Ki-67 showed high positivity of 80%. Features were consistent with leiomyosarcoma of the wall of the ileum.

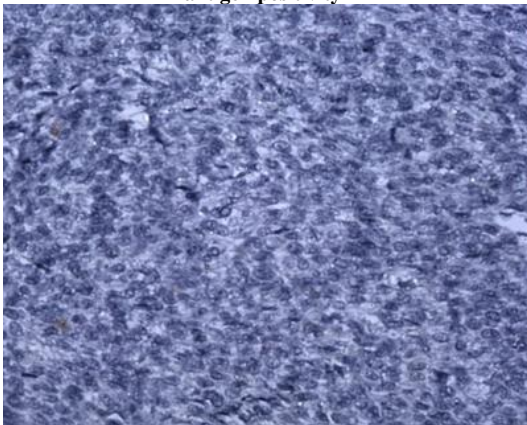
She was treated with adjuvant chemotherapy (Docetaxel 80mg/m<sup>2</sup> and gemcitabine 1 gm/m<sup>2</sup>). She received 5 cycles of chemotherapy till date and at present is asymptomatic.



**Figure 1: CT scan showing tumor arising from small intestine**



**Figure 2: Immunohistochemistry showing smooth muscle antigen positivity**



**Figure 3: CD117 Negative Tumor**

### Discussion

Leiomyosarcoma are rare tumors of small intestine which arise from the muscularis mucosa or muscularis propria. The common presentations include abdominal mass, abdominal pain or overt gastrointestinal bleeding. (3) The most common site of LMS in the small intestine is jejunum followed by ileum and then duodenum. They are mainly seen in 6th decade of life with slight male preponderance. (4-5) Preoperative diagnosis of small intestinal tumors is difficult, especially differentiating between benign and malignant tumors. For LMS in small intestine, recent review of literature revealed that CT- and MRI-enterography and enteroclysis are good options.(6) Cases of superficial lesion which can be missed by both CT and MRI, can however be

detected by water capsule endoscopy with a detection rate of around 80%.(7)

Histologically LMS resembles like GIST, however they are CD117 and CD34 negative by immunohistochemistry and positive for smooth muscle antigen (SMA) and desmin.(8) When these tumors are more than 5 cm they commonly spread hematogenously to liver (65%), other GI organs (15%), lung(4%). It also has the capability to spread via lymphatics (13%) or via peritoneal route (18%). (9)

The only effective treatment for small intestine LMS is surgery. The primary tumor should be excised radically, including a wide resection of the mesentery. Response to chemotherapy is doubtful, and there is no role for radiotherapy. Therefore, metastasectomy, if possible, should be considered. Large phase II and III studies combining docetaxel and gemcitabine yielded impressive response rates in LMSs (mostly of uterine origin). However, others were not able to confirm the efficacy of this combination. Recently, trabectedin showed response rates up to 56% in LMSs, and it appeared to be especially useful in far-advanced and metastatic LMSs after failure of the combination of anthracyclines and ifosfamide. (10)

Prognosis of non metastatic small bowel LMS depends upon its mitotic grade, with low grade tumors having a 5 yr survival of 55% while high grade variants have a 5 yr survival of 5-20%. Outcome of metastatic small bowel LMS is mostly poor. The present case highlights the need for high index of suspicion for diagnosis of this rare disease and need of adequate surgery even when metastatic at presentation for better management of these patients

### Acknowledgements:

We sincerely thank Dr K C Lakshmaiah, Head of Medical Oncology department, Dr Clementina Rama Rao, Professor of Pathology and Dr Shakuntala PN, Department of Gynaec-Oncology, Kidwai memorial Institute of Oncology, Bangalore, for their kind help in preparing this manuscript.

### References

1. Jemal A, Siegel R, Ward E, et al. Cancer statistics, 2009. *CA Cancer J Clin* 2009;59:225-249.
2. Brophy C, Cahow CE. Primary small bowel malignant tumours. Unrecognized until emergent laparotomy. *Am Surg.* 1989;55:408-412.
3. Chou FF, Eng HL, Sheen-Chen SM. Smooth muscle tumors of the gastrointestinal tract: analysis of prognostic factors. *Surgery.* 1996;119:171-177.
4. Akwari OE, Dozois RR, Weiland LH, Beahrs OH. Leiomyosarcoma of the small and large bowel. *Cancer.* 1978; 42:1375-1384.
5. Evans HL. Smooth muscle tumors of the gastrointestinal tract: a study of 56 cases followed for a minimum of 10 years. *Cancer.* 1985;56:2242-2250.
6. Ohnishi T, Yoshioka H, Ishida O. MR imaging of gastrointestinal leiomyosarcoma. *Radiat Med.*1991;9:114-117.
7. Fadi I JABR, Nedaa Skeik. A Leiomyosarcoma of the small bowels causing obscure gastrointestinal bleeding diagnosed by capsule endoscopy. *Lebanese Medical Journal*2010;58(4):238-240.
8. Miettinen M, Sarlomo-Rikala M, Sobin LH, Lasota J. Gastrointestinal stromal tumors and leiomyosarcomas in the colon : a clinicopathologic, immunohistochemical, and molecular genetic study of 44 cases. *Am J Surg Pathol* 2000;24:1339-1352.
9. Skandalakis JE, Gray SW, Skandalakis LJ. Metastasis of malignant smooth muscle tumors of the gastrointestinal tract: pattern and process. *J Med Assoc Ga*1991;80:701-709.
10. Demetri GD, Chawla SP, von Mehren M, et al. Efficacy and safety of trabectedin in patients with advanced or metastatic liposarcoma or leiomyosarcoma after failure of prior anthracyclines and ifosfamide: results of a randomized phase II study of two different schedules. *J Clin Oncol.* 2009;27:4188-4196.