



### **Case Report:**

## **Intracardiac Calcification - An Interesting Chest X-ray Report.**

### **Authors**

**Vishnu Sharma M**, Professor and Head, Department of Pulmonary Medicine, AJ Institute of Medical Sciences, Mangalore,  
**Anupama N**, Associate Professor in Physiology, Kasturba Medical College, Mangalore,  
**Narayana Pradeepa**, Consultant Pulmonologist, Carewell Hospital, Kasaragod,  
**Harsha DS, Rahul Antony Simon, Basavaraj S**, Postgraduate Students, Department of Pulmonary Medicine, AJ Institute of Medical Sciences, Mangalore.

### **Address for Correspondence**

**Dr. Anupama N**,  
Associate Professor,  
Department of Physiology,  
Kasturba Medical College,  
Mangalore. **E-mail:** anupamavsharma@yahoo.com

### **Citation**

Sharma VM, Anupama N, Pradeepa N, Harsha DS, Simon RA, Basavaraj S. Intracardiac Calcification - An Interesting Chest X-ray Report. *Online J Health Allied Scs.* 2012;11(4):19. Available at URL: <http://www.ojhas.org/issue44/2012-4-19.html>

### **Open Access Archives**

<http://cogprints.org/view/subjects/OJHAS.html>  
<http://openmed.nic.in/view/subjects/ojhas.html>

Submitted: Nov 14, 2012; Accepted: Jan 6, 2013; Published: Jan 25, 2013

**Abstract:** We report a case of chest X-ray finding of mitral annular calcification. Mitral annular calcification is a degenerative process involving the fibrous annulus of the mitral valve. It is generally an incidental finding associated with aging and atherosclerosis. It may lead to significant mitral regurgitation and can rarely cause symptomatic mitral stenosis. In addition, mitral annulus calcification may be associated with atrial fibrillation and cardiac arrhythmia. Calcification of mitral annulus in the chest X-ray generally follows the C-shape of the mitral annulus. Confirmation is by echocardiography. Symptomatic cases require repair by surgery.

**Key Words:** Mitral annulus; Intra cardiac calcification.

### **Case report**

We report an interesting finding in a routine pre operative chest X-ray in a 62 years old patient who had to undergo surgery for carcinoma of the stomach. The patient did not have any cardiac or respiratory symptoms. There was no past history of pulmonary tuberculosis or other significant lung disease. Clinical examination of cardio respiratory system was normal. There were no cardiac murmurs.

Chest x ray showed a calcified structure in left lower zone, well localized in lateral view, suggestive of mitral annular calcification.(Fig. 1)

### **Discussion:**

Radiologic detection of calcifications within the heart is quite common. Calcification can occur in the pericardium, thrombus in a vessel, coronary artery, mitral annulus and cardiac valves.

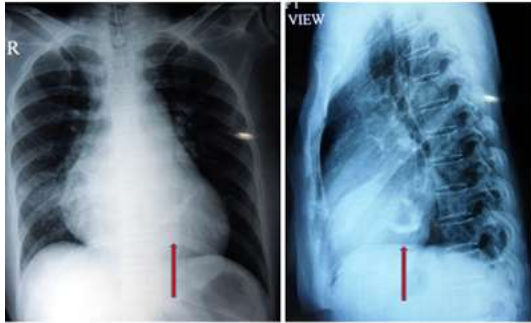
Mitral annular calcification is a degenerative process involving the fibrous annulus of the mitral valve.(1) It is generally an incidental finding associated with aging. It may lead to significant mitral regurgitation and can rarely cause symptomatic mitral stenosis. In addition, mitral annulus calcification may be associated with atrial fibrillation and

cardiac arrhythmia due to extension of calcification into the conduction system of heart.(1)

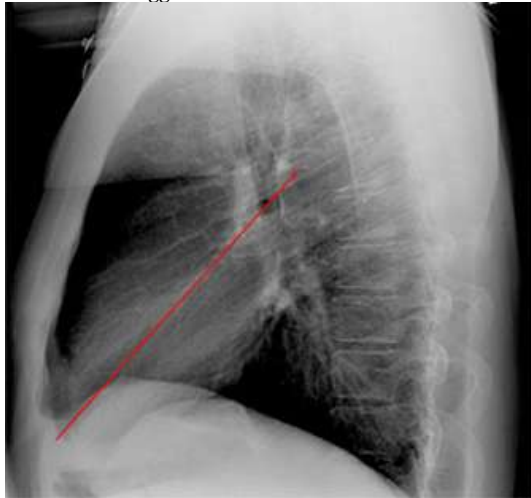The mitral valve annulus is the C-shaped segment of the fibrous skeleton at the base of the left ventricle at its junction with the left atrium. Mitral annular calcification develops from progressive calcium deposition along and beneath the mitral valve annulus.(2) It generally follows the C-shape of the mitral annulus Base of the anterior mitral leaflet is generally spared.(3)

Cause for mitral annular calcification (MAC) is unknown but it is more common in patients with atherosclerosis and in elderly. MAC and atherosclerosis share similar risk factors MAC may reflect the intensity and duration of exposure to these risk factors over time.(4) MAC has been proposed as a barometer of the burden of atherosclerotic disease.(5) Studies have suggested that the presence of MAC is independently associated with a higher incidence of cardiovascular disease (CVD) and cardiovascular death.(6)

Symptoms of Mitral annular calcification depend on the degree of calcification. Mild Mitral annular calcification may not cause symptom. Severe Mitral annular calcification may leads to symptoms due to mitral regurgitation or stenosis. Some of these patients develop sinus node disease and conduction system degeneration leading to sinus bradycardia, atrioventricular block, and slow atrial fibrillation. Some patients may develop thrombo-embolic disease due stagnation of blood flow in cardiac chambers as a result of cardiac arrhythmia.



**Fig. 1: Chest x ray showing calcified structure in left lower zone suggestive of mitral annular calcification.**



**Fig 2: Alignment of cardiac valves on lateral chest X ray**  
Diagnosis for Mitral annular calcification can be done by chest X-ray and echocardiography. Chest X-ray (CXR) can detect mitral annular calcification. Calcification of mitral annulus in the chest X-ray generally follows the C-shape of the mitral annulus.(3) Location of cardiac valves is best determined on the lateral CXR. Draw an imaginary line from the apex of the heart to the hilum. The pulmonary & aortic valves generally are above this line and the tricuspid & mitral valves are below this line (Fig-2).

Mitral annular calcification is most commonly identified by echocardiography as an echo dense shelf-like structure involving the mitral valve annulus with associated acoustic shadowing. The calcification frequently has an irregular, lumpy appearance.(2,3) Although mitral valve leaflets and chordae tendinae are generally not involved, calcification may progressively accumulate in the subvalvular region beneath the posterior leaflet with encroachment on the leaflet. Sparing of the leaflet commissures and anterior leaflet distinguishes mitral annular calcification from rheumatic mitral involvement.(2)

#### **Treatment for Mitral annular calcification:**

The presence of asymptomatic MAC does not require specific medical therapy. Because of the associations between MAC and atherosclerosis, valvular disease, stroke, and other vascular diseases, appropriate medical management of concomitant cardiovascular risk factors is recommended.(7) The potential regression of MAC with medical therapy has not been studied, but studies done with aortic valve calcification, a disease with similar pathophysiology, have shown no regression despite treatment with angiotensin-converting enzyme inhibitors and statins.(7) MAC has also been associated with chronic kidney disease. Its presence on echocardiography should alert the physician

to the possible presence of decreased renal function.(8) No endocarditis prophylaxis is indicated in patients with isolated MAC.(9)

According to the American College of Chest Physicians guidelines for valvular and structural heart disease, antithrombotic therapy with aspirin is recommended in patients with MAC but without atrial fibrillation who have experienced systemic embolism, ischemic stroke, or transient ischemic attack.(10)

For recurrent events despite aspirin, anticoagulation with vitamin K antagonists is suggested. In patients with MAC who have a single embolus documented to be calcific, data are not sufficient to recommend either for or against antithrombotic therapy.(10)

Patients with isolated MAC are at increased risk for major cardiovascular events (example- stroke, myocardial infarction) that may require inpatient care.

Given the strong association with atherosclerosis, cardiovascular risk factor modification (example- hypertension, hyperlipidemia) and appropriate follow-up is important.(10)

#### **Surgical Care for MAC**

No surgical treatment is indicated for MAC, unless correction of concomitant mitral regurgitation or mitral stenosis is needed. In fact, severe MAC makes valve surgery more difficult. Risk and benefits of surgery must be carefully assessed in patients with significant MAC, as increased surgical mortality has been observed in these patients. For those patients with documented calcific emboli or repeated thromboembolism despite anticoagulation, valve replacement may be considered.(13) Calcified plaque must be removed carefully to prevent ventricular rupture, especially in the depths of the calcified plaque wall.

#### **References:**

1. Bonninger M. (a) Bluttransfusion bei perniziöser anämie: (b) Zwei Fälle von Herzblock. *Dtsch Med Wochenschr.* 1908;34:2292-2294.
2. Fulkerson PK, Beaver BM, Auseon JC, Graber HL. Calcification of the mitral annulus:etiology, clinical associations, complication and therapy. *Am J Med* 1979;66:967-977.
3. Roberts WC, Waller BF. Mitral valve "annula" calcium forming a complete circle "O" configuration: Clinical and necropsy observations. *Am heart J* 1981;101:619-621.
4. Adler Y, Fink N, Spector D, Wisner I, Sagie A. Mitral annulus calcification—a window to diffuse atherosclerosis of the vascular system. *Atherosclerosis.* Mar 2001;155(1):1-8.
5. Pressman GS, Crudu V, Parameswaran-Chandrika A, Romero-Corral A, Purushottam B, Figueredo VM. Can total cardiac calcium predict the coronary calcium score?. *Int J Cardiol.* 2011;146(2):202-206.
6. Fox CS, Vasan RS, Parise H, Levy D, O'Donnell CJ, D'Agostino RB. Mitral annular calcification predicts cardiovascular morbidity and mortality: the Framingham Heart Study. *Circulation.* Mar 25 2003;107(11):1492-1496.
7. Salem DN, O'Gara PT, Madias C, Pauker SG,. Valvular and structural heart disease: American College of Chest Physicians Evidence-Based Clinical Practice Guidelines (8th Edition). *Chest.* Jun 2008;133(6 Suppl):593S-629S.
8. Wang AY, Wang M, Woo J, Lam CW, Li PK, Lui SF. Cardiac valve calcification as an important predictor for all-cause mortality and cardiovascular mortality in long-term peritoneal dialysis patients: a prospective study. *J Am Soc Nephrol.* Jan 2003;14(1):159-168.
9. Foley RN, Parfrey PS, Sarnak MJ. Clinical epidemiology of cardiovascular disease in chronic renal disease. *Am J Kidney Dis.* Nov 1998;32(5 Suppl 3):S112-119.
10. Pressman GS, Agarwal A, Braitman LE, Muddasir SM. Mitral annular calcium causing mitral stenosis. *Am J Cardiol.* Feb 1 2010;105(3):389-391.