



Short Review:

The Application of Airtraq (fiberoptic intubation device) to Otolaryngology

Dulani Mendis, ENT SpR, West Midlands Deanery, Dept. of ENT Surgery, Birmingham Children’s Hospital NHS Foundation Trust, Steelhouse Lane, Birmingham B4 6NH,

John Oates, Consultant Otolaryngologist, Dept. ENT Surgery, Queen’s Hospital, Belvedere Road, Burton-on-Trent, DE13 0RB.

Address for Correspondence:

Dulani Mendis,

ENT SpR, West Midlands Deanery,

Dept. of ENT Surgery,

Birmingham Children’s Hospital NHS Foundation Trust,

Steelhouse Lane,

Birmingham B4 6NH.

E-mail: dulanimendis@yahoo.com

Citation: Mendis D, Oates J. The Application of Airtraq (fiberoptic intubation device) to Otolaryngology. Online J Health Allied Scs. 2011;10(2):16

URL: http://www.ojhas.org/issue38/2011-2-16.htm

Open Access Archives: http://cogprints.org/view/subjects/OJHAS.html and http://openmed.nic.in/view/subjects/ojhas.html

Submitted: Jun 24, 2011; Accepted: Jul 16, 2011; Published: Jul 30, 2011

**Abstract:** The anaesthetic laryngoscope Airtraq is designed for the difficult airway. This disposable laryngoscope requires minimal cervical manipulation and unlike other common anaesthetic laryngoscopes contains a channel for the guidance of an endotracheal tube. This could also be used for diagnosis and biopsy under a general anaesthetic or potentially under a local anaesthetic in an outpatient setting for biopsies or the removal of hypopharyngeal foreign bodies via flexible biopsy forceps obviating the need for a general anaesthetic. Thus Airtraq could be included in the armoury of pre-existing direct laryngoscopes because of its virtue of minimal airway manipulation.

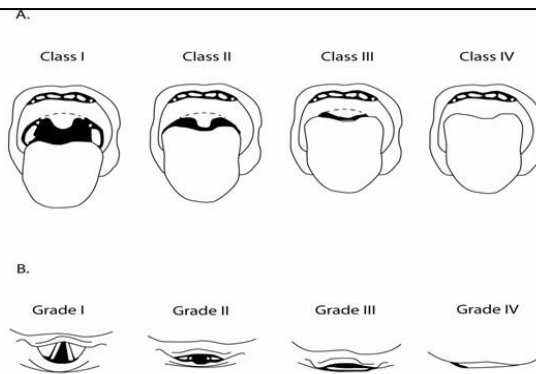
**Key Words:** Difficult intubation; Laryngoscopy

**Introduction:**

Difficult endotracheal intubation is often associated with a difficult direct laryngoscopy for the Otolaryngologist and subsequent poor visualisation of the larynx. A difficult intubation is defined as “more than three attempts to intubate in 10 minutes of time”<sup>1</sup>, or whereby “it is not possible to visualise any portion of the vocal cords with conventional laryngoscopy” or “intubation requires more than one attempt, a change in blade, an adjunct to direct laryngoscopy or use of alternative devices”.<sup>2</sup> The difficult airway is usually assessed as being Cormack and Lehane Grade 3 and 4 or Mallampati Class 3 and 4 (Figure 1).

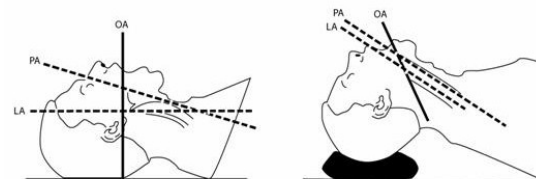
Other contributory patient factors may be morbid obesity and cervical spine pathology e.g. trauma and/or degenerative disease causing instability (Rheumatoid Arthritis). Successful tracheal intubation achieved by obtaining a good glottic view, requires alignment of three optical axes corresponding to the oral, pharyngeal and laryngeal planes (Figure 2).

During routine laryngoscopy, a degree of manipulation of the neck is required to align these axes. Excessive manipulation due to an unexpected difficult airway can result in delayed intubation (hypoxia), cervical injury, soft tissue injury and increased risk of dental trauma. In patients with cervical spine trauma the concomitant manual in-line axial stabilisation prevents head extension and neck flexion further limiting optimal visualisation of the glottis.



**Figure 1: (A) Mallampati classification: Class 1 – visualisation of the soft palate, Class 2 – complete visualisation of the uvula, Class 3 – visualisation of the base of the uvula, Class 4 – soft palate is not visible at all.**

**(B) Laryngoscopy according to the Cormack and Lehane classification: Grade I – most of the glottis visible, Grade II – only the posterior extremity of the glottis visible, Grade III – only the epiglottis visible (none of the glottis seen), Grade IV- neither epiglottis or glottis visible.**



**Figure 2: Diagram illustrating the oral, pharyngeal and laryngeal axes, in-order to to obtain an optimal view prior to intubation a degree of cervical manipulation is required for the alignment of these axes.**

Alternative methods for intubating difficult cases include awake-fiberoptic intubation, with the gold standard being a fiberoptic bronchoscope. This is a skilled technique with a steep learning curve. The procedure can take some time and the

view may be compromised by blood and secretions. The instrument is weighty and expensive, it requires a separate light source or video stack and the instrument can present as a source of infection if not properly sterilised. Awake intubation, is performed in a controlled manner with an expected difficult intubation. In the case of a crash intubation the Otolaryngologist may be called upon to intubate with a side splitting Negus-type laryngoscope or as a last resort perform an emergency surgical airway (cricothyroidotomy or tracheostomy).

Other anaesthetic laryngoscopes for difficult intubations in the anaesthetised patient are the McCoy levering laryngoscope blade (Penlon Ltd, Abingdon, UK), Bullard laryngoscope (Circon ACMI, Stamford, CT), the LMA C-Trach (LMA North America, San Diego, CA) and the Glidescope (Saturn Biomedical, Burnaby, British Columbia, Canada). These are essentially anaesthetic laryngoscopes, which provide an improved view for intubation but not necessarily the equivalent view obtained with a direct laryngoscope (Negus, Kleinsessor, Lindholm) required in Otolaryngology for biopsy purposes or removal of laryngeal/hypopharyngeal foreign bodies.

The Airtraq laryngoscope, (Inventor: Pedro Acha, Gandarias, produced by Prodol Meditec, Spain) is a new device which has recently become commercially available in the United Kingdom. It is a disposable device with an anatomically shaped blade. This contains a series of lenses, prisms and mirrors that transfer the image from the illuminated blade tip to the proximal viewfinder. The blade incorporates a endotracheal tube (ETT) channel on the right side to guide the ETT and any type of ETT can be used (standard, reinforced etc.)

The light is battery powered and the battery box is located in the main body of the Airtraq device. There are two sizes selected depending on patient weight and size of ETT to be used; regular size - maximum blade thickness of 17.5 mm (ETT 7.0-8.5) and small – maximum blade thickness of 15.5mm (ETT 6.0-7.5), (Figure 3A, 3B). Two further Airtraq versions now exist for nasotracheal and double lumen endobronchial intubations.



Figure 3: (A) Photo of the disposable Airtraq device.



Figure 3: (B) Photo demonstrating the detachable view finder and battery pack.

There is an anti-fog system and an available clip-on video system to allow viewing on to a monitor with a recording facility.

The device requires 30-60 seconds to reach its maximal light and it can be passed, and the patient intubated with the neck in a neutral position (no manipulation of the neck is required) and so a good view of the glottis is obtained without the need for aligning the three axes due to the inherent prism system.

Airtraq has been used in patients with cervical spine trauma<sup>3</sup>, morbidly obese patients<sup>4</sup>, patients requiring rapid sequence induction<sup>5</sup>, intubation in the upright position<sup>6</sup>, awake intubations<sup>7</sup> and intubations without muscle relaxants. Maharaj, et al (2006)<sup>8</sup> compared the ease of learning intubation with the Airtraq device with a Mackintosh laryngoscope. The study concluded that the Airtraq laryngoscope required less operator skill to use. It had a shorter learning curve, was able to provide a good view of the larynx with minimal airway manipulation, reduced intubation time and was associated with less dental trauma.

#### Discussion: Application to Laryngology

The use of the Airtraq device in Laryngology maybe relevant for the difficult to intubate patient as the hypopharyngeal/laryngeal view is similar to that obtained with a direct laryngoscope with the additional advantage of less airway manipulation whilst primarily being used as an intubating tool. To expose the glottis the device can either be located at the vallecular or under the epiglottis. Biopsies of relevant areas could also be taken, which is more feasible with shorter versions of flexible biopsy forceps (e.g those used for bronchoscopy), in order to follow the exaggerated curvature of the laryngoscope (Figure 4). There does not appear to be a suitably curved rigid instrument at present.



Figure 4: Photo demonstrating the Airtraq device with the use of a flexible biopsy forcep guided through the intubation channel for the proposed purpose of foreign body removal and biopsies

The device has been described for use in awake patients; this could be applied in the outpatient setting for laryngeal biopsies and the effective removal of hypopharyngeal foreign bodies with adequate local anaesthesia using flexible forceps and an appropriate flexible suction catheter. Mackintosh laryngoscopes have anecdotally been used previously for foreign body removal in an awake patient but this is usually a difficult, uncomfortable and unsuccessful procedure. This could prevent the need for a general anaesthetic (especially relevant to patients with multiple co-morbidities, American Society of Anesthesiology grade 3 and upwards) and the cost of a hospital admission.

The Airtraq is single use; the plastic viewfinder and battery box are detached from the blade, which is disposable. Disposable items although initially expensive when introduced to the market are desirable in terms of reducing the risk of transmission of prion proteins (Creutzfeldt Jacob disease).

Financially, the four Airtraq variants are costed at £35 excluding VAT (Fannin UK Limited, Reading). The video system is an optional add-on consisting of a clip-on camera and wireless receiver. In terms of the curved instruments standard flexible bronchoscopy biopsy forceps are costed at £10 each excluding VAT in boxes of ten (Diagmed Healthcare, Yorkshire, UK) a shorter version of these (currently 110cm in length) would be the most appropriate.

**Conclusion:**

Our review comments on the application of a new intubating device currently used by Anaesthetists for the difficult airway, to Otolaryngology for diagnostic purposes in such cases and on its potential use for the removal of hypopharyngeal foreign bodies in an outpatient scenario, obviating the need for a general anaesthetic.

We propose the importance of including this device in the armory of pre-existing direct laryngoscopes because of its virtue of minimal airway manipulation.

**References:**

1. American Society of Anesthesiologists. Practice guidelines for management of the difficult airway. A report by the American Society of Anesthesiologists Task Force on Management of the Difficult Airway. *Anesthesiology*. 1993;78(3):597-602.
2. American Society of Anesthesiologists. Practice Guidelines for Management of the Difficult Airway. An Updated Report by the American Society of Anesthesiologists Task Force on Management of the Difficult Airway. *Anesthesiology*. 2003;98(5):1269-1277.
3. Maharaj CH, Buckley E, Harte BH, Laffey JG. Endotracheal Intubation in Patients with Cervical Spine Immobilization. A Comparison of Mackintosh and Airtraq Laryngoscopes. *Anesthesiology*. 2007;107(1):53-59.
4. Dhonneur G, Ndoko SK, Amathieu R, Housseini LE, Polliand C, Tual L. A comparison of two techniques for inserting the Airtraq laryngoscope in morbidly obese patients. *Anaesthesia*. 2007;62:774-777.
5. Dhonneur G, Ndoko SK, Amathieu R, Housseini LE, Poncelet C, Tual L. Tracheal Intubation Using the Airtraq in Morbid Obese Patients Undergoing Emergency Cesarean Delivery. *Anesthesiology*. 2007;106(3):629-630.
6. Ndoko SK, Amathieu R, Tual L, Polliand C, Kamoun W, Housseini LE, Champault G, Dhonneur G. Tracheal intubation of morbidly obese patients: a randomised trial comparing performance of Macintosh and Airtraq laryngoscopes. *British Journal of Anaesthesia*. 2008;100(2):263-268.
7. Suzuki A, Toyama Y, Iwasaki H. Correspondence: Airtraq for awake tracheal intubation. *Anaesthesia*. 2007;62:744-755.
8. Maharaj CH, Costello JF, Higgins BD, Harte BH, Laffey JG. Learning and performance of tracheal intubation by novice personnel: a comparison of the Airtraq and Mackintosh laryngoscope. *Anaesthesia*. 2006;61:671-677.