



Case Report:

Amoeboma- An Interesting Case Report With an Unusual Presentation

Vijayshankar S, Assistant Professor, Department of Pathology,
Usha Ramachandra, Professor and Head, Department of Pathology,
Vastala Rao, Professor, Department of Pathology,
Sujatha Siddappa, Assistant Professor, Department of Pathology,
Adichunchanagiri Institute of Medical Sciences, BG Nagara, Bellur cross, Mandya district, Karnataka, India.

Address For Correspondence:

Dr. Vijayshankar S,
No 45, Ananda shylam, 3rd cross,
1st main K N extension, Yeswanthpur,
Bangalore - 560022,
Karnataka
E-mail: vijayshankarpatho@gmail.com

Citation: Vijayshankar S, Usha R, Rao V, Siddappa S. Amoeboma- An Interesting Case Report With an Unusual Presentation. *Online J Health Allied Scs.* 2010;9(3):22

URL: <http://www.ojhas.org/issue35/2010-3-22.htm>

Open Access Archives: <http://cogprints.org/view/subjects/OJHAS.html> and <http://openmed.nic.in/view/subjects/ojhas.html>

Submitted: Aug 8, 2010; Accepted: Sep 20, 2010; Published: Oct 15, 2010

Abstract:

Amebiasis is an infectious disease caused by *Entamoeba Histolytica* is more common in developing countries, with various clinical manifestations and sequelae. Amoeboma, is an unusual sequelae which manifests as a tumor like mass within the colon. We present an unusual case of 5 year old child with signs of acute abdomen. A mass was found on exploratory laparotomy attached to the small intestine. Histopathological examination of the mass revealed numerous amoebic trophozoites and the diagnosis of amoeboma was made. Our case is unusual because amoebomas presenting as an extraluminal mass attached to small intestine is extremely uncommon.

Key Words: Amoeboma; Small intestine; Extraluminal mass

Introduction:

Amoeboma is a tumour like mass involving the whole thickness of the bowel wall and may extend into the surrounding part and other structures. It is one of the manifestation of amoebiasis, but it is rare. The common sites are cecum, rectosigmoid junction and rectum. Small intestinal involvement is rare. Lesion presenting as an extraluminal inflammatory mass is very uncommon. The final diagnosis depends on demonstration of Amoebic trophozoites in sections by H & E and special stains.

Case Report:

Five year-old male child presented with acute abdominal pain. On examination the patient had developed signs of peritonitis. Emergency exploratory laparotomy revealed a nodular mass in the right iliac fossa about 15 cm proximal to ileocecal junction. Resection of the mass along with the portion of small intestine was done.

Pathologic findings: The specimen was a segment of small bowel with 30 cm in length, with a mass measuring 10X8 cm seen adherent to the intestinal wall on mesenteric side.(Figure 1) The whole of the intestine was covered with exudates with areas of patchy necrosis. Cut section of small intestine showed patchy areas of necrosis of the mucosa and ulceration. Cut section of the mass showed extensive area of necrosis along with grey white areas.(Figure 1)

Microscopy: Multiple sections from the small intestine showed the ulceration of mucosa, necrotic area with extensive infiltration by acute and chronic inflammatory cells. Many trophozoites were seen in the margins of necrotic areas.

Multiple sections from the mass showed extensive areas of necrosis, sheets of mixed inflammatory cells and many multinucleated giant cells. Amidst these are seen numerous trophozoites.(Figure2) These trophozoites resembled large histiocytes with granular cytoplasm and inconspicuous nuclei. These were confirmed by PAS stain and iron hemotoxylin and eosin stains.(Figure3)

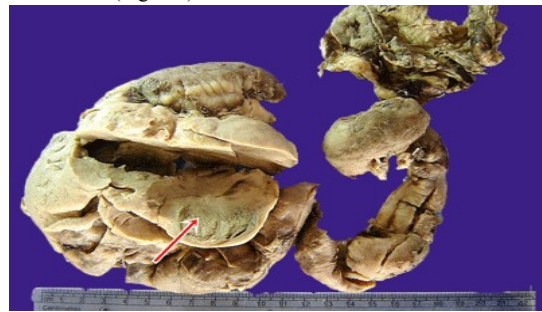

Figure 1: Photograph showing segment of small intestine with an adjacent greywhite mass

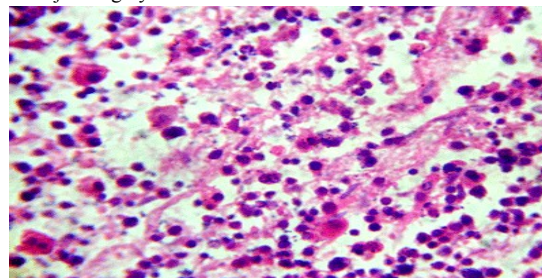


Figure 2: Photomicrograph showing many trophozoites in the background of inflammatory cells and necrotic debris (hematoxylin & eosin x 400)

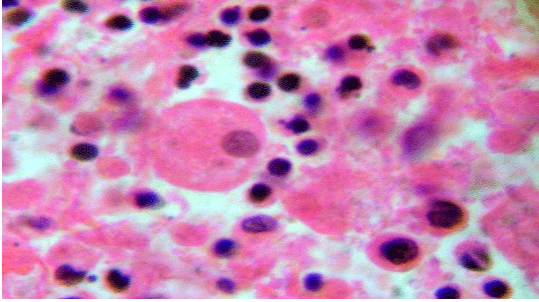


Figure 3: Photomicrograph showing trophozoite (Iron hematoxylin & Eosin x 1000)

Discussion:

Amebomas or amoebic granulomas are unusual sequelae of amebiasis. It is rare with an incidence of 1.5% of patients with intestinal amebiasis.¹ Amoebomas can occur in any age groups but are usually common in the age 20 to 60 years. There are a greater proportion of men than women who are affected by all forms of invasive amebiasis.

Ochsner and De Bakey coined the term "ameboma" to describe a cicatricial inflammatory lesion that develops following acute amebic dysentery.² Where as "amebic granuloma" describes the microscopic pathologic finding seen in chronic amebiasis. These lesions may vary in size from mucosal excrescences to large tumor masses; the term "ameboma" is best reserved for those large amoebic granulomas.

Amebomas are found in descending order of frequency in the cecum, the appendix, rectum, transverse colon, sigmoid colon and rarely hepatic and splenic flexure.³ They can occur in single or at multiple sites.⁴ Extension of the granuloma into the ileum may occasionally be seen.

The appearance of ameboma is function of balance between inflammation and fibrosis.² If there is abundance of inflammatory cells, an intraluminal polypoidal lesion may be mimicked. If there is marked fibrosis with few inflammatory cells, intramural shortening and constriction of the bowel wall may be seen.

Clinically amebomas cause a variety of symptoms including alternating diarrhea and constipation, weight loss and low-grade fever. Very rarely they can present without any gastrointestinal symptoms.⁵ Most often ameboma occurs in the course of proven amoebic colitis, and a combination of tumor and colitis justifies a presumptive diagnosis. Clinically if there is a mass lesion it can mimic malignancy. Since amoebomas are a rare entity, it is usually discovered at laparotomy. However in the absence of clinical picture or proven amoebic colitis, the diagnosis may be a great challenge even at laparotomy, as was in our case. The symptoms may be so insidious that the patient is unaware until a major complication occurs.

The right diagnosis is by histopathological demonstration of trophozoites in the inflammatory mass or the bowel wall. The trophozoites resemble large histiocytes have granular and bluish gray cytoplasm and may contain ingested RBC's the nucleus is inconspicuous central or eccentric, with a single central karyosome which is difficult to see in H & E stain. The cytoplasm is PAS positive. Iron hematoxylin stain can also be used to demonstrate trophozoites in the sections.

The primary treatment is oral metronidazole therapy for 5 to 10 days. Longer intervals of treatment is necessary in cases with ameboma formation. Surgical intervention is indicated if there is bowel perforation, acute necrotizing colitis or if the patient does not respond to anti amoebic therapy.⁵

Conclusion:

Our case is an unusual presentation of ameboma, as an extraluminal mass adjacent to the small bowel. We haven't come across such a presentation, in spite of thorough search in the literature. Hence it is advisable to keep "ameboma" as one of the differential diagnosis in the evaluation of abdominal masses in children. A high index of suspicion is required for appropriate diagnosis and management.

Acknowledgements:

We thank Dr Indira CS, Faculty, all other teaching and non teaching staff, dept of pathology AIMS, Bellur and our institution, for providing help during execution of this work.

References:

1. Misra SP, Misra V, Dwivedi M. Ileocecal masses in patients with amoebic liver abscess: etiology and management. *World J Gastroenterol.* 2006 Mar 28;12(12):1933-1936.
2. Levine SM, Stover JF, Warren JG et al. Ameboma, the forgotten granuloma. *JAMA.* March 1971;215(9):1461-1464.
3. Fernandes H, D'Souza CR, Swethadri GK, Naik CN. Ameboma of the colon with amoebic liver abscess mimicking metastatic colon cancer. *Indian J Pathol Microbiol.* 2009 Apr-Jun;52(2):228-230.
4. Haque R, Huston CD, Hughes M, Houpt E, Petri WA Jr. Amebiasis. *N Engl J Med.* 2003 Apr 17;348(16):1565-1573.
5. Hardin RE, Ferzli GS, Zenilman ME, Gadangi PK, Bowne WB. Invasive amebiasis and ameboma formation presenting as a rectal mass: An uncommon case of malignant masquerade at a western medical center. *World J Gastroenterol.* 2007 Nov 14;13(42):5659-5661.