



Case Report:

Multiple Choriangiomas of Placenta

Vijay Shankar S, Associate Professor,
Swarna Shivakumar, Professor and Head,
Nalini Krishnan, Associate Professor,
Thejaswini MU, Assistant Professor,
Abhishek MG, Assistant Professor,
Department of Pathology, Adichunchangiri Institute of Medical Sciences, BG Nagara, Nagamangala taluk, Mandya district, Karnataka, India.

Address For Correspondence:

Dr. Vijay Shankar S,

No 45, Ananda shylam,

3rd cross, 1st main ,

KN extension, Yeswanthpur,

Bangalore - 560022,

Karnataka, India.

E-mail: vijayshankarpatho@gmail.com

Citation: Vijay Shankar S, Shivakumar S, Thejaswini MU, Abhishek MG. Multiple Choriangiomas of Placenta. *Online J Health Allied Scs.* 2010;9(4):27

URL: <http://www.ojhas.org/issue36/2010-4-27.htm>

Open Access Archives: <http://cogprints.org/view/subjects/OJHAS.html> and <http://openmed.nic.in/view/subjects/ojhas.html>

Submitted: Dec 6, 2010; Accepted: Dec 28, 2010; Published: Jan 20, 2011

Abstract:

Placental choriangiomas, not an uncommon condition is often small and hence usually goes unnoticed . However the incidence of complications is high when the choriangioma is large. We hereby present an unusual case of large and multiple choriangiomas with secondary changes and associated congenital anomalies with hydrops fetalis.

Key Words: Choriangiomas; Hydrops; Degenerative changes

Introduction:

Choriangioma of the placenta was originally described by Clarke in 1798.¹ It is the most common benign vascular tumor ranging widely in size and approximately 1% of all pregnancies.² It is most likely a hamartoma of primitive chorionic mesenchyme composed of capillary sized and cavernous vascular spaces embedded in a fibrotic /myxoid stroma.²

It most often goes unnoticed. However it is accompanied by maternal and fetal complications.

Case Report:

A 25-year-old female with 7 months of amenorrhea presented for a regular antenatal check up. Her marriage was consanguinous and had a 2-year-old healthy female child which was delivered by full-term normal delivery. There was no history of spontaneous or induced abortions in the past. During this pregnancy, she had an uneventful first and second trimester. Ultrasound examination revealed multiple congenital anomalies with features of hydrops and hence labour was induced to terminate the pregnancy.

Patient delivered an anomalous male baby weighing 1.25 kg, with low set ears, web neck along with features of hydrops. Along with the placenta, multiple large grey brown soft tissue masses were also delivered. Placenta along with the soft tissue masses were sent for histopathological examination.

Pathological Examination:

Gross examination of the placenta showed a fleshy area on the fetal surface . Along with this, multiple grey brown soft , well circumscribed, irregular masses were present; largest measuring 8x5x4 cm. Placenta weighed 900g and the masses weighed 450 gms. Cut section of all the masses were soft, hemorrhagic, with focal grey white areas (Figure 1).

Microscopic examination of the masses showed a well delineated tumor, predominantly composed of capillary sized blood vessels lined by plump endothelial cells, along with few cavernous spaces filled with blood (Figure 2). The vascular spaces are separated by fibrous stroma. The stroma also showed extensive areas of ischemic necrosis and myxoid degeneration. These features were diagnostic of choriangioma of placenta with secondary degenerative changes and infarction.

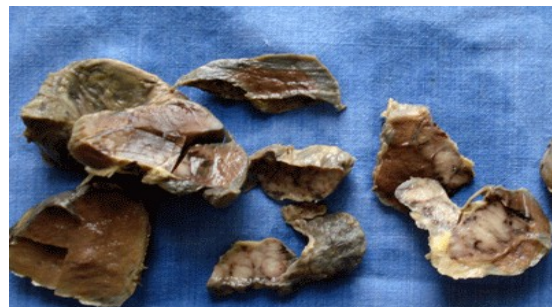

Figure 1: Cut section of the masses revealing hemorrhagic and grey white areas.

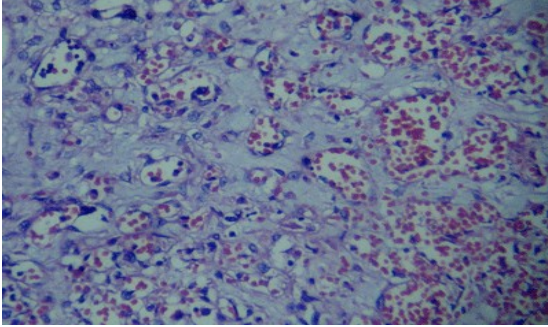


Figure 2: Tumor composed of capillary and cavernous sized blood vessels (100x)

Discussion:

Choriangiomas of the placenta are benign, primary, non-trophoblastic placental vascular tumors. The incidence is approximately 1% of all the placentas and are analogous to hemangiomas at other sites.¹ It is found that choriangiomas are more frequent in first or twin pregnancies and also when the fetus is female.³ In our case the choriangioma is found in second pregnancy and the fetus is male. These are expansile nodular lesions composed entirely of vascular channels with intervening stroma and surrounded by trophoblastic tissue.

Choriangiomas can be intraplacental or extraplacental where it is attached as a bulging mass on the fetal surface of the placenta. In one of the study it is found that choriangiomas are most frequently found in areas where it is poorly perfused as in marginal and subchorionic regions. They are least frequently found in areas of best perfusion like in centrobasal region of the placenta.⁴ Most cases of choriangiomas are diagnosed following delivery. The macroscopic size of the choriangioma varies from few millimetres to several centimetres. Choriangiomas are considered as large when the size is more than 4 centimeters. They are fleshy, dark and often congested.¹ In our case the choriangioma was extraplacental large and multiple which were soft and hemorrhagic with focal grey white areas. It was diagnosed following the termination of pregnancy.

Microscopically various patterns have been described. They are capillary, cavernous, endotheliomatous, fibrosing and fibromatous forms.² Alternatively they are also classified as angiomatous (capillary), cellular and degenerative.² some authors believe that, such precision is unwarranted as the clinical outcome is always the same, and it depends on the size of the mass(es) than the composition of the tumor(s).¹ The angiomatous pattern, is the most common among these and is composed of numerous small endothelial lined capillaries, with blood vessels and surrounded by trophoblastic tissue. The intervening perivascular stroma is composed of fibroblasts, macrophages and collagen. These tumors often have degenerative changes, calcification, infarcts and thrombosis which may leave hemosiderin behind.¹ In our case the tumor was capillary and cavernous type with extensive areas of necrosis and myxoid degeneration.

A vast majority of the choriangiomas are small and have no clinical significance. Complications are usually seen when the choriangiomas are multiple and are large.⁵ The complications affect the mother as well as the fetus. The maternal complications include hydramnios, prematurity, abruption of placenta and post partum hemorrhage.

Fetal complications include non-immune hydrops fetalis, cardiomegaly, congestive cardiac failure, anemia, prematurity and sudden death. Few cases of thrombocytopenic purpura is also noted. Hydrops fetalis in choriangioma of the placenta may be due to the compression of the umbilical vessels by the tumor, increased secretion of fetal metabolites through the tumor or may be due to transudation of the fluid from the tumor.⁵

It is intriguing to note that, inspite of large and multiple choriangiomas, this patient did not have any maternal complications. However the fetus had congenital anomalies with features of hydrops.

References:

1. Bashiri A, Maymon E, Wiznitzer A, Maor E, Mazor M. Choriangioma of the placenta in association with early severe polyhydramnios and elevated maternal serum HCG: a case report. *Eur J Obstet Gynecol Reprod Biol* 1998;79:103–105.
2. Flores GJ, Malagon VG, Malagon VJ. Giant choriangioma of the placenta. *Intl J Gynecol Obstet* 2005;89:280-281.
3. Ogino S, Redline RW. Villous capillary lesions of the placenta: Distinction between choriangioma, choriangiomatosis, and choriangiosis. *Human Pathology* 2000;31:945–954.
4. Beirschke K, Kaufmann P, Baergen R. Benign tumors and choriangiosis. In: Beirschke K, Kaufmann P, Baergen R, editors. *Pathology of human placenta*. 5th edn. New York: Springer; 2006. p. 863-76.
5. Jashnani DK, Doshi BJ, Rege DJ. Placental Choriangioma – A Cause Of Hydrops Fetalis And Intrauterine Fetal Death. *Bombay Hosp Journal*. April 2000;42(2)411. Available http://www.bhj.org/journal/2000_4202_apr00/case_411.htm