



Case Report:

Intramuscular (infiltrating) Lipoma

P Sridhar Reddy, Department of Oral & Maxillofacial Surgery,
Ananth Naag, Department of Oral & Maxillofacial Surgery,
Bina Kashyap, Department of Oral Pathology,
St. Joseph Dental College & Hospital, Duggirala, Eluru, Andhra Pradesh, India.

Address For Correspondence:

Dr. P. Sridhar Reddy,
Flat no. 202, Sai Balaji Estates,
Gurukrupa Road, Satavahana Nagar,
Eluru, West Godavari District,
Andhra Pradesh, India.
E-mail: padalarsi@yahoo.co.in

Citation: Reddy PS, Naag A, Kashyap B. Intramuscular (infiltrating) Lipoma. *Online J Health Allied Scs.* 2010;9(4):23

URL: <http://www.ojhas.org/issue36/2010-4-23.htm>

Open Access Archives: <http://cogprints.org/view/subjects/OJHAS.html> and <http://openmed.nic.in/view/subjects/ojhas.html>

Submitted: Oct 26, 2010; Accepted Nov 10, 2010; Published: Jan 20, 2011

Abstract:

Intraoral lipomas are benign and relatively rare tumors, although they occur with higher frequencies in other areas, most especially the back, abdomen and shoulders of adults. They have no gender predilection and predominantly affect the buccal mucosa. This paper describes a case of intramuscular (infiltrating) lipoma on the buccal mucosa of a 60-year old male which is relatively rare when compared to simple lipoma of buccal mucosa, and review pertinent literature.

Key Words: Lipoma; Benign; Intramuscular; Infiltrating

Introduction:

Lipomas are benign mesenchymal neoplasms composed of mature adipocytes, usually surrounded by thin fibrous capsule.(1) They are the most common soft tissue tumors and about 15 – 20% of cases occur in head and neck region. However, its occurrence in the oral cavity is rare, it accounts only 1–4% of all lipomas affecting predominantly the buccal mucosa, floor of the mouth and tongue. The unusual intraoral sites include the lips, gingiva and palate.(2)

Generally oral lipomas have been reported to occur in all ages but are frequently seen after 40 years of age with peak occurrence in the fifth or sixth decades of life.(3) The exact etiology remains unknown, although trauma, infection and other factors have been proposed as etiological agents for lipomas. They usually present as painless, well circumscribed, slow growing pedunculated or sessile, submucosal or superficial lesions. Most of the diagnoses were made clinically as they rarely give a radiographic impression but imaging can be useful in the diagnosis and delimitation of oral lipomas.

Microscopically, it is not possible to distinguish these lipomas from normal adipose tissue, despite their different metabolism, probably due to high lipoprotein lipase activity in neoplastic lipoma cells.(4) The most common lesions were simple lipomas and fibrolipomas and rarer variants included angioliipoma, intramuscular (infiltrating) lipoma, pleomorphic lipoma, spindle cell lipoma, salivary gland lipoma (sialoliipomas), myxoid lipoma and atypical lipomas.(5,6) We report a patient with an intramuscular/ infiltrating lipoma in the buccal mucosa which are relatively rare and also review the international literature

concerning about the clinical presentation, microscopical characteristics, differential diagnosis and treatment.

Case Report:

A 60 – year old male complained of a left – sided swelling in the buccal mucosa. The lesion had appeared 10 years previously, growing very slowly and without any accompanying symptoms of oral intake or speech. Oral examination revealed non – tender, large, well demarcated, smooth, sessile with soft to firm mass of size 3 X 3 cm protruding from the left buccal mucosa. The overlying mucosa appeared normal (Figure 1). There was no palpable cervical lymphadenopathy. Medical history of the patient was non contributory. Routine hemogram, ECG and X-ray chest were all within normal limits.

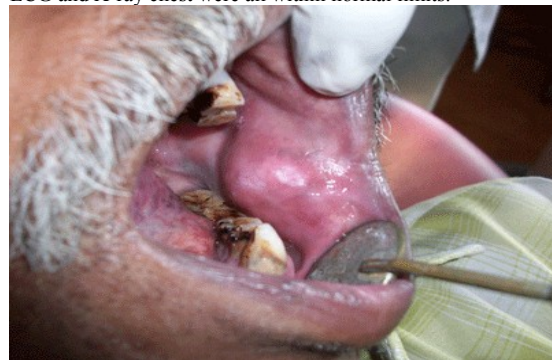

Figure 1: Preoperative showing large mass on the buccal mucosa

Excisional biopsy of the mass was performed under local anesthesia (Figure 2). At gross examination, specimen was polypoid to round in shape and measure 3 X 3 cm. Upon formalin fixation and paraffin embedding, sections were treated with haematoxylin – eosin. Microscopic examination showed an intact stratified squamous epithelium covering the surface. The submucosa revealed mature adipocytes extending to the epithelial level and which lie down through the irregular bundles of skeletal muscle fibers, along with few areas of vascularization. No cellular atypia, necrosis, mitotic activity and lipoblastic proliferation was observed (Figure 3). The patient had no perioperative problems and is without evidence of recurrence.

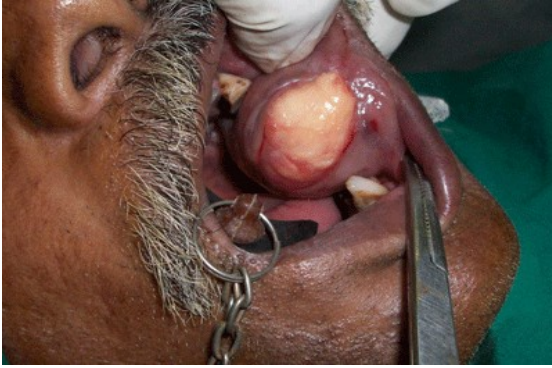

Figure 2: Intraoperative.

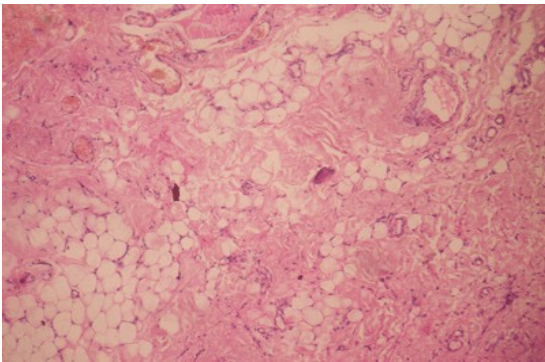


Figure 3: Photomicrograph of H& E section showing infiltration of adipocytes into the muscles under 10X.

Discussion:

Lipomas are common, benign tumors located in any part of the body in which fat is normally present. They are relatively uncommon in the oral cavity, representing about 0.5% to 5% of all benign oral tumors. Generally, their prevalence does not differ with gender, although a predilection for men has been reported.(7)

Lipomas generally grow slowly because pain is not a feature in many cases, many years elapse before patients consult their dentist or physician.(8) It bears variable sizes from small 10mm masses to few large case series of 2–5 cm that have been published in the English language literature. The present case reports the relatively rare large size of the lesion.

Clinical diagnosis of oral lipomas is not always easy. Where the overlying mucosa is thin and the yellow color of the tumor appears through it, the diagnosis is easily made. However, in the deep seated cases, the diagnosis is seldom made clinically and the tumors often attain appreciable size before they cause symptoms and their presence recognized.(9,10) In such situations, other possibilities such as cyst, an encapsulated abscess or other benign tumors have to be considered. The case reported here shows the difficulty that can be encountered in diagnosing deeply embedded lipoma. The deep position of this lesion suggested other possibilities such as neurofibroma, fibroma, salivary gland tumor and lipoma.

The occurrence of multiple lipomas is associated with Cowden's syndrome or multiple hamartoma syndrome. This condition is either familial or sporadic and is associated with the predominantly post pubertal development of a variety of cutaneous, stromal and visceral neoplasms, resulting from mutation of the phosphatase and tensin homolog (PTEN) gene.(11) It can involve various organs, such as the skin, oral mucous membrane, thyroid, breast, ovaries and central nervous system. No such abnormality was observed in the present case.

Histologically, lipomas can be classified as simple lipomas or its variants namely fibrolipomas, angiolipoma, intramuscular (infiltrating) lipoma, pleomorphic lipoma, spindle cell lipoma, salivary gland lipoma (sialolipomas), myxoid lipoma and atypical lipomas.(9) Although the clinical appearance of color and tissue consistency may vary with the combination of histologic features, such combinations are not of prognostic significance. (12)

Intramuscular lipomas are of primary importance because of their differential diagnosis with liposarcomas due to its large size, deep location and their ability to infiltrate adjacent muscles and recur locally. Therefore, detailed histological examination is essential in all intramuscular lipomas, which can be commonly misdiagnosed as liposarcoma. Differential diagnostic criteria were summarized in Table 1. The intramuscular lipoma is usually well demarcated, but has no capsule and infiltrates into the adjacent muscle. Our case had no areas of lipoblastic proliferation, nuclear atypia and mitosis. Although intramuscular or infiltrative lipomas are recognized as a histologic subtype there is speculation that they are simply lipomas with entrapped muscle fibers.(9)

The treatment of oral lipomas, including all the histologic variants, is simple surgical excision. No recurrence is observed except intramuscular lipomas. The recurrence rate for infiltrating lipomas has been reported to be 3 to 6.5%.(13,14) They have propensity to recur without adequate surgery. Long term follow up was recommended and so far, after 1 year our patient is free of disease.

Summary:

Lipomas are the most common neoplasms of the soft tissue. They are only presenting 0.5 to 5% of all the benign neoplasms of the oral cavity. The most common histologic subtype is the simple lipoma which predominantly affects the buccal mucosa. Intramuscular (infiltrating) lipoma of the buccal mucosa is a rare variant of lipoma and a few cases have been reported, with same histologic and clinical appearance, well differentiated liposarcoma must be excluded and surgical excision should be carefully done.

References:

1. Carter TG, Egbert M. Traumatic proplase of the buccal fat pad (Traumatic Pseudolipoma): A case report and literature review. *J Oral Maxillofac Surg* 2005;1029–1032.
2. Akbulut M, Aksoy A, Bir F. Intramuscular lipoma of the tongue: A case report and review of the literature. *Aegean Pathology Society* 2005;2:146–149.
3. Morais HH, Vajgel A, Rocha NS et al. Congenital lipoma of the lip: a case report. *Journal of oral sciences* 2009;51(3):489–491.
4. Bandeca MC, Padua JM, Nadalin MR et al. Oral soft tissue lipomas: A case series. *JCDA* June 2007;73(5):431–434.
5. Gnepp DR. (Editor) Diagnostic surgical pathology of the head and neck. WB Saunders; Philadelphia. 2001.
6. Weiss SW, Goldblum JR. (Editors) Benign lipomatous tumors. In: Enzinger and Weiss's soft tissue tumors. 4th ed. Mosby; St. Louis. 2001. pp 571–639.
7. Furlong Ma, Fanburg-smith JC, Childers EL. Lipoma of the oral and maxillofacial region: site and subclassification of 125 cases. *Oral Surg Oral Med Oral Pathol Oral Radiol Endod* 2004;98(4):441–450.
8. Spencer J, Daniels M. Lipoma of tongue. *Saudi dental journal* 2006;18(1):1–6.
9. Fregnani ER, Pires FR, Falzoni R, Lopes Ma, Vargas PA. Lipomas of the oral cavity: clinical findings, histological classification and proliferative

- activity of 46 cases. *Int J Oral Maxillofac Surg* 2003;32(1):49–53.
10. Akyol Mu, Odzzek A, Sokmensuer C. Lipoma of the tongue. *Otolaryngol Head Neck Surg* 2000;122:461–462.
 11. Woodhouse JB, Delahunt B, English SF, Fraser HH, Ferguson MM. Testicular lipomatosis in cowden's syndrome. *Mod Pathol* 2005;18(9):1151–1156.
 12. Gier Re. Yellow conditions of the oral cavity. In: Wood NK, Goaz Pw, editors. *Differential diagnosis of oral and maxillofacial lesions*, 5th edition. St. Louis: Mosby year book Inc., 1997. p. 225–231.
 13. Garavaglia J, Gnepp DR. Intramuscular (infiltrating) lipoma of the tongue. *Oral Surg Oral Med Oral Pathol* 1987;63(3):348–350.
 14. Shirasuma K, Saka M, WAtatani K, Kogo M, Mat-tuya T. Infiltrating lipoma of the tongue. *Int J Oral Maxillofac Surg* 1989;18(2):68–69.