



**Case Report:**

**Epithelioid Cell Histiocytoma – An Unusual Variant of Dermatofibroma at an Uncommon Site**

**Shulbha VS**, Assistant Professor, Department of Pathology,  
**Amita K** Assistant Professor, Department of Pathology,  
**Nischal KC**, Assistant Professor, Department of Dermatology,  
**Adichunchanagiri Institute of Medical Sciences, B.G Nagar, Bellur, Mandya Dist, Karnataka, India.**

**Address For Correspondence:**

**Dr. Shulbha V Sejkan,**

Assistant Professor,  
Department of Pathology,  
Adichunchanagiri Institute of Medical Sciences,  
B.G Nagar, Bellur,  
Mandya Dist, Karnataka, India.  
**E-mail:** drshulbha@rediffmail.com

**Citation:** Shulbha VS, Amita K, Nischal KC. Epithelioid Cell Histiocytoma – An Unusual Variant of Dermatofibroma at an Uncommon Site. *Online J Health Allied Scs.* 2011;10(1):16

**URL:** <http://www.ojhas.org/issue37/2011-1-16.htm>

**Open Access Archives:** <http://cogprints.org/view/subjects/OJHAS.html> and <http://openmed.nic.in/view/subjects/ojhas.html>

Submitted: Mar 2, 2011; Accepted: March 31, 2011; Published: April 15, 2011

**Abstract:**

Epithelioid cell histiocytoma (ECH) is a rare variant of cutaneous fibrous histiocytoma involving primarily trunk and the extremities. It can delude the pathologist in considering other benign non neoplastic and neoplastic lesions. Awareness of this new entity can avert unnecessary treatment. We report a case of epithelioid cell histiocytoma in a 40 yr old male who presented with a painless nodular swelling over the dorsum of nose. The case is presented here for its rarity and an uncommon site of involvement.

**Key Words:** Epithelioid cell histiocytoma; Nose

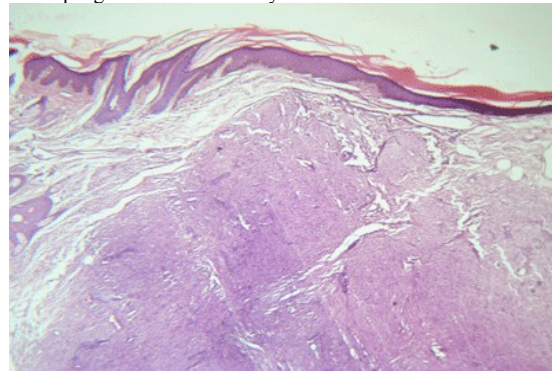
**Introduction:**

Epithelioid cell histiocytoma (ECH) is a benign tumor of the dermis which can closely resemble other benign and malignant tumors showing epithelioid features.<sup>1</sup> ECH is an unusual and still poorly recognized variant of benign fibrous histiocytoma. Epithelioid cell histiocytoma differs from most benign fibrous histiocytomas in the following ways - the predominance of epithelioid cells, relative lack of secondary elements (such as giant cells, foamy, or hemosiderin-laden macrophages), relative sharp circumscription, prominent vascularity, and centering in the papillary dermis in most cases.<sup>2</sup> The lesion is characterised by its occurrence as a solitary elevated nodule often with a vascular appearance. The histologic aspect resembles the intradermal form of Spitz nevus. Most of the characteristic angulated epithelioid cells that form the tumor are factor XIIIa positive and therefore categorise the variant as fibrous histiocytoma.<sup>3</sup> Here we present a case of epithelioid cell histiocytoma in a 40 years old male who presented with a painless nodular swelling over the dorsum of nose.

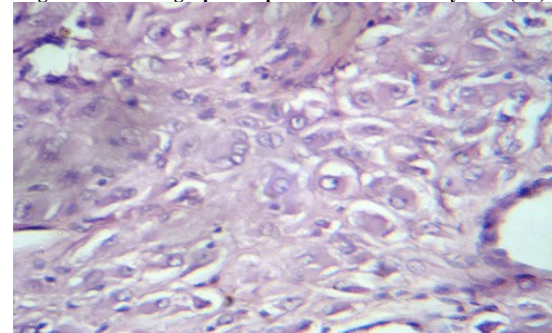
**Case Report:**

A 40 years old male presented with a painless nodular swelling over the dorsum of nose slowly progressing to the present size for duration of 7 months. No history of trauma or presence of such swellings elsewhere in the body was elicited. Clinical examination revealed a pale, skin colored nodule measuring 1x0.5 cm. External surface was smooth with no secondary changes such as pigmentation or vascular markings noted. Clinical diagnosis of a benign soft tissue tumor was put forth. The mass was excised under local anaesthesia and sent for

histopathological examination. Gross revealed a skin covered mass measuring 1x0.5 cm. Cut surface was solid and grey white. Microscopy showed a centrally located, circumscribed tumor underlying an epidermal collarette. The tumor was composed of epithelioid cells arranged in sheets and storiform pattern. (Fig 1). Individual cells showed abundant eosinophilic cytoplasm with round vesicular nuclei and prominent nucleoli. (Fig 2). Areas of myxoid change were seen. Also seen were foamy macrophages, giant cells, hemosiderin laden macrophages and inflammatory cell infiltrate.



**Fig 1: Photomicrograph of Epithelioid Cell Histiocytoma (5X)**



**Fig 2: Photomicrograph of Epithelioid Cell Histiocytoma (40X)**

**Discussion:**

Epithelioid cell histiocytoma (ECH) is a rare and recently recognized variant of cutaneous fibrous histiocytoma first described by Wilson et al.<sup>4</sup> This tumor falls into the category of Dermatofibroma with architectural and cellular/ stromal peculiarities.<sup>5</sup> The age incidence of ECH is fourth decade with a female preponderance.<sup>1,3</sup>

Clinically the lesions are most commonly present over the trunk, upper and lower extremities, followed by head and neck regions as circumscribed papules measuring 1 x2 cm in greatest dimension.<sup>1</sup> In our case study, location of the lesion at an uncommon site has been emphasised upon. The most distinguishing feature of ECH is the predominance of angulated epithelioid histiocytes with prominent nucleoli which simulates amelanotic melanoma.<sup>2,6</sup> However a sharp circumscription, central location, presence of giant cells, foamy cells and hemosiderin laden macrophages helps to differentiate ECH from malignant melanoma.<sup>2,7</sup> In our case, special stains for melanin were negative.

Epithelioid cell histiocytoma may clinically resemble many lesions including bacillary angiomatosis, histiocytoma, dermatofibroma, pyogenic granulomas, blue nevus, nodular malignant melanoma, metastatic melanoma and spitz nevus. Histologically this form of histiocytoma could be mistaken for spitz nevus, solitary reticulocytoma and atypical fibroxanthoma.<sup>3</sup> The other differential diagnoses that can be considered are epithelioid blue nevus, and cellular neurothekeoma.<sup>5,8</sup> A spitz nevus shows epithelioid cells usually in singles against a background of abundant dense, collagenous stroma.<sup>8</sup> Relative lack of circumscription, a larger size and extension of the lesion into the adjacent subcutaneous tissue differentiate a cellular blue nevus from an ECH. Cellular neurothekeoma is a poorly circumscribed reticular dermal lesion showing mitotic activity and cytologic atypia which is unlikely to happen in ECH.<sup>8</sup>

ECH are CD 163, CD v68, and vimentin positive with focal nuclear immunoreactivity for microphthalmia transcription factor and focal reactivity for Factor XIIIa and S 100.

Epithelioid cells are negative for CD3, CD10, CD 20, CD -30, S 100 and keratin.<sup>(1)</sup> Thus S 100 positivity in case of spitz nevus and cellular blue nevus helps to differentiate them from ECH. ECH has to be widely excised to prevent recurrence.

**Conclusion:**

ECH is the new, rare variant of dermatofibroma that can ape benign non neoplastic and neoplastic lesions both clinically and histopathologically .The present case paramounts on placing this entity in the differential diagnosis of epithelioid cell rich lesions. Awareness of this entity to both pathologist and clinician can halt unnecessary treatment.

**References:**

1. Sarma DP, Repertinger SK. Epithelioid Cell Histiocytoma: a Case Report and Brief Review of the Literature, with an Emphasis on Differential Diagnosis. *The Internet Journal of Dermatology*. 2009;7(2).
2. Glusac EJ, McNiff JM. Epithelioid cell histiocytoma: a simulant of vascular and melanocytic neoplasms. *Am J Dermatopathol*. Feb 1999;21(1):1-7.
3. Dezfoulian B, Nikkels AF, Pierard-Franchimont C and Pierard GE. Epithelioid Cell histiocytoma: A report of two cases. *Dermatology* 1995;190:349-350.
4. Wilson Jones E, CERio R, Smith NP. Epithelioid cell histiocytoma:A rare entity. *Br J dermatol* 1989;120:185 -195.
5. Zelger BG, Zelger B. Dermatofibroma. A clinicopathologic classification scheme. *Pathologe*. 1998 Nov;19(6):412-419.
6. Glusac EJ, Barr RJ, Everett MA, Pitha J, Santa Cruz DJ. Epithelioid cell histiocytoma. A report of 10 cases including a new cellular variant. *Am J Surg Pathol*. Jun 1994;18(6):583-590.
7. Zelger BG, Sidoroff A, Zelger B. Combined dermatofibroma: co-existence of two or more variant patterns in a single lesion. *Histopathology*. Jun 2000;36(6):529-539.
8. Zelger B. Fibrohistiocytic skin lesions. *Verh Dtsch Ges Pathol*. 1998;82:290-300.