

Case Report

A Case of Rhinolithiasis

Authors

Rakesh Kumar Singh, Saurabh Varshney, Sampan Singh Bist, Nitin Gupta, Rajat Bhatia,

Department of Otolaryngology Head and Neck Surgery,

Sanjeev Kishor,

Department of pathology,

Himalayan Institute of Medical Sciences, Dehradun

Address For Correspondence

Dr. Rakesh Kumar Singh,

Department of Otolaryngology Head and Neck Surgery,

Himalayan Institute of Medical Sciences,

Jollygrant, Doiwala,

Dehradun

E-mail: rkstent5@gmail.com

Citation

Singh RK, Varshney S, Bist SS, Gupta N, Bhatia R, Kishor S. A case Of Rhinolithiasis. *Online J Health Allied Scs.* 2008;7(2):7

URL

<http://www.ojhas.org/issue26/2008-2-7.htm>

Submitted: May 6, 2008; Accepted: June 28, 2008; Published: July 21, 2008

Abstract:

Rhinolith is an uncommon nasal mass in children and adolescents. We report a 8 years old boy with a history of long standing foul smelling right sided nasal discharge, progressive nasal obstruction and recurrent epistaxis, which was clinically suspected as being due to the presence of a long standing foreign body. Rhinolith in the right nasal cavity was diagnosed on rigid endoscopic examination. Rhinolith was removed by using a 0° rigid nasal endoscope.

Key Words: Rhinolith, Endoscopy

Introduction:

Rhinoliths are calcareous concretions around calcinated intranasal foreign bodies within the nasal cavity.¹ They are usually found in the anterior part of the nasal cavity and are usually diagnosed on history and anterior rhinoscopy.² In such a condition, radiological evaluation is only needed for differential diagnosis and to detect any related complications. Radiology may be useful in a posteriorly situated mass which may cause difficulties in diagnosis.^{3,4} However, endoscopic examination can be of immense help in such situations.^{2,5} We present a rare case of posteriorly situated rhinolith in a child that was diagnosed and treated with the help of a rigid nasal endoscope.

Case Report:

A 8 years old boy presented with a 3 year history of right sided nasal obstruction, foul-smelling purulent nasal discharge, intermittent nasal bleeding and posterior nasal drip. The patient did not give any history of putting a foreign object inside the nose. There was no history of prior nasal trauma or nasal surgery. Anterior rhinoscopy revealed hyperaemic nasal mucosa on the right side, purulent nasal discharge and suspicious mass in the posterior part of the nasal cavity. Probing revealed a hard stony mass with gritty sensation. Posterior rhinoscopy showed purulent discharge trickling along the lower part of the eustachian tube opening. The initial clinical suspicion was that of a long standing foreign body in the right nasal cavity.

After proper decongestion with Oxymetazoline and anaesthetising the nasal cavity with 2% Xylocaine, the nasal cavity was evaluated with a 0° rigid nasal endoscope. Endoscopic examination of the nasal cavity revealed an irregular hard foreign body extending from the roof to the floor of the posterior part of the right nasal cavity (Fig. 1).

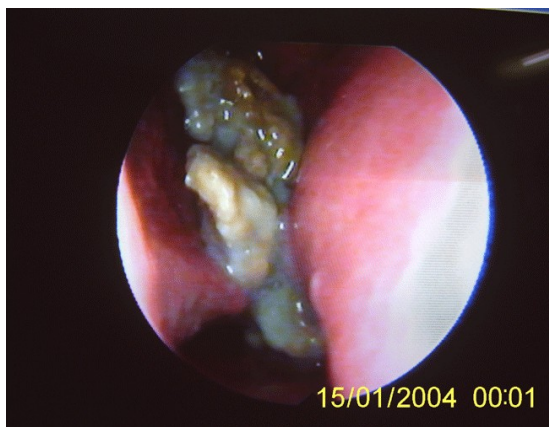


Fig 1: Endoscopic picture of rhinolith present in the right nasal cavity

The object was situated lateral to the nasal septum and medial to the inferior and middle turbinates, displacing the

middle turbinate laterally. The object also encircled the free ends of the middle and inferior turbinates. The surrounding mucosa was hyperaemic and edematous. A plain CT scan of the nose and paranasal sinuses showed a homogenous well-defined calcified object with central translucency at the floor of nasal cavity without any bony erosion (Fig. 2).

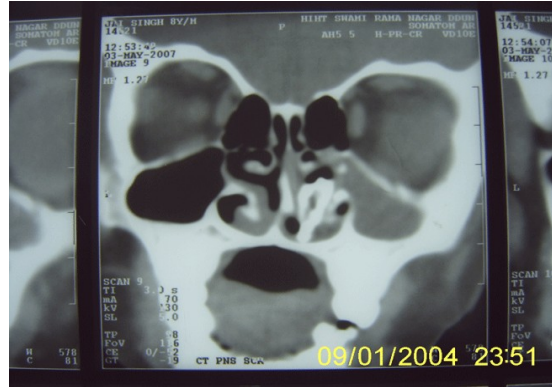


Fig 2: Coronal CT scan of nose and paranasal sinuses showing a rhinolith in right nasal cavity and collection of fluid in right maxillary antrum

Based on above findings, clinical diagnosis of rhinolith of the right nasal cavity was made and the patient was taken up for surgery under general anaesthesia. With the help of a 0° rigid nasal endoscope, the mass was visualized and a blunt dissector was passed all around the object with the purpose of freeing it from the surrounding mucosa. It was pushed into the nasopharynx and was taken out via the oral cavity (Fig 3).

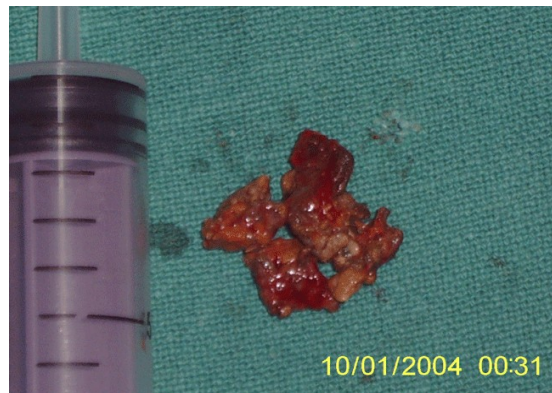

Fig 3: Specimen of rhinolith after endoscopic assisted removal

Uncinectomy, middle meatal antrostomy and anterior ethmoidectomy was done to clear the maxillary sinus. The specimen was sent for histopathological examination. The

histopathological report revealed calcium crystals over degenerated materials suggestive of rhinolith (Fig: 4).

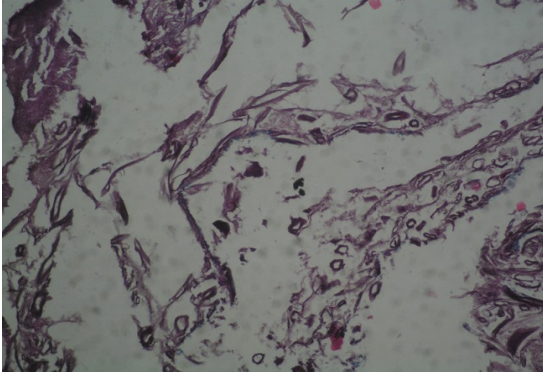


Fig 4: Microscopic picture of the rhinolith showing calcium crystals and degenerated material (H & E, X40)

Minimum bleeding was encountered during the procedure which was controlled by anterior nasal packing with Meroceel. Antibiotics, nasal decongestant and anti-inflammatory drugs were given to the patient for seven days post surgery. The patient was relieved of the presenting symptoms after surgery and no complication was noted postoperatively.

Discussion:

Rhinoliths are grey to brown coloured, foul-smelling, rough-surfaced, friable structures often situated in the anterior half of the nasal cavity most commonly on its floor². The other locations reported are in the maxillary and frontal sinuses.¹ Bertholin gave the first documented description in 1654.² Rhinoliths usually present in the third decade of life and rarely occur in children with females more commonly affected than male.⁴

The pathogenesis of rhinolith is not clear. It has been speculated that a foreign body incites a chronic inflammatory reaction, with the deposition of mineral salts. The foreign body acts as a nidus that causes obstruction of nasal secretions, acute and chronic inflammation, deposition of minerals and enzymatic activities of bacterial pathogens.^{2,3} Most foreign bodies are exogenous, such as beads, buttons, pieces of paper, cherry pits, stones, sand, fruits, peas, parasites, wood or glass and they usually enter through the anterior nares. Rare endogenous agents causing true rhinolith include clotted blood, bacteria, leukocytes, bone fragments and teeth.⁶

Axmann carried out the first chemical analysis of rhinolith in 1829.² Since then, several techniques have been used for mineralogical analysis such as Electron-ray microprobe, X-ray diffractometry and infrared-spectroscopy. The predominant material (up to 90%) is inorganic. Calcium phos-

phate, calcium carbonate and magnesium phosphate, as well as other rare substances, have been described. The organic components may derive from nasal secretions and lacrimal fluid.^{1,2}

The typical symptoms of rhinolith are unilateral nasal obstruction, foul smelling purulent nasal discharge and epistaxis. Other symptoms include crusting, swelling of nose or face, anosmia, epiphora and headache.⁶ At rhinoscopy, a mass or nodule with well- or ill-defined borders with a hard gritty sensation on probing is often found.⁵

In 1900, MacIntyre gave the first radiological description of rhinolith.⁴ The typical radiological features are radio-opacity with central translucency. On CT scan, it appears as a homogenous, high-density lesion with smooth mineralization. The central portion of the lesion, which may contain organic material, may be of a somewhat lower density, or a foreign-body nidus may be seen. CT cannot differentiate a rhinolith from any other calcified mass, but can detect the related complications of rhinoliths.^{3,4}

Rigid endoscopy has a great role in establishing a diagnosis, and in evaluating the posterior extent of a rhinolith without providing any risk of radiation exposure. It is a cost-effective diagnostic as well as therapeutic method. The endoscopic nasal surgery provides an opportunity for manipulation and removal of the entire mass under direct visual control. At the same time it is helpful in managing any complications of rhinolith.^{1,3,5}

The most important differential diagnosis include haemangioma, osteoma, calcified polyps, enchondroma, dermoid, chondrosarcoma, osteosarcoma, syphilis and tuberculosis. The complications reported are sinusitis, septal perforation, palatal perforation, recurrent otitis media, and recurrent dacryocystitis.^{1,4,6} Our patient developed ipsilateral maxillary sinusitis that was treated with uncinectomy, middle meatal antrostomy and anterior ethmoidectomy.

In most cases, rhinolith of nasal cavity can be removed through the nostrils. Only in rare cases are extended surgical approaches, for e.g. alar release or lateral rhinotomy, necessary for complete removal of the stone. A rhinolith that cannot be removed surgically could be disintegrated using a lithotripsy.³ The use of the nasal endoscope has begun a new method in the diagnosis and management of rhinolith. The diagnosis is straightforward and easy with a rigid endoscope. Endoscopically controlled surgery can also be immensely helpful in complete and uneventful removal of the rhinolith and in dealing with complications such as sinusitis. It is a cost-effective and more accurate method for diagnosis and treatment.^{2,5} Ours is a typical case with respect to the age and sex of the patient, the location, diagnostic and therapeutic approach for a rhinolith.

References:

1. Keck T, Liener K, Strater J, Rozsasi A. Rhinolith of the nasal septum. *Int J Pediatr Otorhinolaryngol* 2000;53:225-228.
2. Sinha B K, Bhandary S, Singh R K, Karki P. Giant rhinolith with nasopharyngeal extension-a rare case report. *Pakistan J Otolaryngol* 2005;21:42-43.
3. Hadi U, Ghossaini S, Zaytoun G. Rhinolithiasis: a forgotten entity. *Otolaryngol Head Neck Surg* 2002;126:48-51.
4. Royal S A, Gardner R E. Rhinolithiasis: an unusual pediatric nasal mass. *Pediatr Radiol* 1998;28:54-55.
5. Ogretmenoglu O. The value of endoscopy in the diagnosis of rhinolith: a case report. *Kulak Burun Bogaz Ihtis Derg* 2003;11:89-92.
6. Aksungur E H, Binokay F B, Bicakci K et al. A rhinolith which is mimicking a nasal benign tumor. *Eur J Radiol* 1999;31:53-55.