

Role of Tissue-Doppler Imaging to Assess Left Ventricular Function in Patients with Right Ventricular Pacing

AR Moarref¹, E Fallahzadeh^{2*}, J Zamani¹, KS Najib³

¹Department of Cardiology, ²Department of Internal Medicine, ³Department of Pediatrics, Shiraz University of Medical Sciences, Shiraz, Iran

Abstract

Background: Right ventricular apical (RVA) pacing has been reported to impair diastolic and systolic function. These changes were usually studied by conventional echocardiography, while tissue-doppler imaging (TDI) has provided a new way to evaluate global and regional systolic left ventricular (LV) function and abnormal LV relaxation. We designed this study to evaluate the changes of TDI-derived indices of asynchrony after RVA pacing.

Methods: We followed 41 patients with LV ejection fraction (LVEF) $\geq 45\%$ and LV end-diastolic dimension (LVEDD) ≤ 56 mm who underwent single- or dual-chamber RVA pacemaker implantation for performing pacemaker analysis and second 2-dimensional (2D) echocardiography and TDI, at least 4.2 months later. 2D measurements included LVEDD, LV end-systolic dimension (LVESD), left atrial (LA) volume and septum to lateral asynchrony, while TDI measurements were the peak velocities of myocardial shortening (Sm) and early myocardial relaxation (Em).

Results: Considering the exclusion criteria, 20 patients entered the study with the mean age of 66.05 years and follow-up of 7.86 months (4.20-12.25). The reduction of Sm, Em and LVEF, and the increment of LVEDD, LVESD, septum to lat asynchrony and LA volume were statistically significant. Changes of all these parameters, however, were independent of pacing duration, frequency or mode (single- or dual- chamber).

Conclusions: RVA pacing has deleterious effects on both LV systolic and diastolic parameters of not only conventional echocardiography but also TDI even in patients with normal LV function. Furthermore, LA volume increases significantly.

Keywords: Tissue-doppler imaging; Left ventricular function; Right ventricular pacing; Left atrial volume; Conventional echocardiography

Introduction

Cardiac pacing is known to be a safe and effective therapy in the management of symptomatic bradyarrhythmias¹. The modern era of cardiac pacing dates back to 1958.² The right ventricular apex (RVA) is the preferred site for cardiac stimulation and remains the most widely used locus in standard indications.^{3,4}

In concert with data⁵⁻¹⁴ regarding the adverse

hemodynamic and clinical effects of the spontaneous left bundle branch block (LBBB), newer data are emerging, which convincingly indicate that the iatrogenic variety of LBBB, produced by RVA pacing technique, may be equally harmful¹⁵⁻²¹ since this technique results in asynchronous patterns of the right and left ventricular (LV) contraction and relaxation.²²⁻²⁴

Chronic RVA pacing has been reported to impair diastolic function^{23,25,26} and reduce systolic contraction.^{1,25} These changes were usually studied by conventional echocardiography, while Tissue-Doppler Imaging (TDI) allows accurate assessment of the regional timing of mechanical events relative to the phases of the cardiac cycle.²⁷⁻³² It has provided a new

*Correspondence: Ebrahim Fallahzadeh, MD, Assistant Professor of Department of Internal Medicine, Nemazee Hospital, Shiraz University of Medical Sciences, Shiraz, Iran. Tel: +98-711-6261082, Fax: +98-711-2307594, e-mail: ebrahimfz@yahoo.com
Received: January 15, 2008 Accepted: August 12, 2008

way to evaluate global and regional systolic LV function and abnormal LV relaxation.³³ Even this technique has emerged for prediction of LV function improvement after cardiac resynchronization therapy (CRT).³⁴ However, data on the changes of TDI-derived indices of asynchrony after

RVA pacing are limited. In a study by John *et al.*,³⁵ usefulness of TDI for evaluation of unfavorable effects of continuous, atrial- synchronized ventricular pacing on ventricular function was investigated in patients with normal LV ejection fraction (LVEF), but the patients entered the study at least 6 months after pacemaker implantation, not before it.

We, therefore, in this prospective study compared conventional echocardiography and TDI indices of LV function in patients before and after pacemaker implantation to demonstrate the adverse effects of iatrogenic LBBB on normal LV systolic and diastolic function by TDI technique.

Materials and Methods

This study included 41 consecutive patients with LVEF \geq 45% and LV end-diastolic dimension (LVEDD) \leq 56 mm undergoing single- or dual-chamber pacemaker implantation in RVA. Then, they were followed for follow-up (FU) echocardiography (by the same cardiologist) and pace analysis after at least 4.2 months.

Two-Dimensional (2D) echocardiography and TDI were performed, using a commercially available ultrasound system (Acuson Sequoia, Siemens, and Mountain View, CA, USA) according to American Society of Echocardiography Guidelines.^{36,37}

2D measurements included LV dimension at end-diastole (LVEDD) and end-systole (LVESD) and left atrial volume (LAV) at end-systole from the apical 4- and 2-chamber views (method of discs). LVEF was measured, using the Simpson's rule. The peak velocity average of myocardial shortening (Sm) and the peak velocity average of early myocardial relaxation (Em) were measured, using TDI in the apical 4- and 2- chamber view by placement of a 3-mm sample volume at the lateral, septal, anterior and inferior mitral annulus.³⁶

Exclusion criteria were 1) Spontaneous wide QRS complex (\geq 120 msec) (n=5), 2) Recent or during FU acute coronary syndrome (ACS) (n=1), 3) Significant valvular heart disease (n=1), 4) Pacing frequency

<90% (n=3), 5) Cardiac or non-cardiac death (n=8), 6) Losing FU (n=3) 7) Muscular dystrophy, 8) Cardiac surgery and 9) atrial fibrillation rhythm.

The data are presented as mean \pm standard deviation. The patients were used as their own controls and comparison was performed, using paired t-test. The *p*-value <0.05 was considered as statistically significant.

Results

Twenty patients, whose demographic and echocardiographic characteristics prior to pacemaker implantation are displayed in Table 1, entered the study. The mean age of the group was 66.05 years (35-83) and 65% were female. They were followed for 7.86 months (4.20-12.25). Indication of pacemaker implantation was complete atrioventricular block (CAVB) in 17 patients and sick sinus syndrome (SSS) in the others. Pacemakers were single-chamber (VVIR) in 13 patients and the remaining had dual-chamber (DDDR) variety.

Table 1: Demographic and echocardiographic data prior to pacemaker implantation

Parameter	Value (%)
Age (years)	66.05 \pm 10.84
Female	13 (65)
Follow-up Duration (mo)	7.86 \pm 2.44
Pacing indication	
CAVB	17 (85)
SSS	3 (15)
Pacing mode	
VVIR	11 (55)
DDDR	9 (45)
LVEF (%)	70.28 \pm 11.16
LVEDD (mm)	46.07 \pm 6.61

CAVB=Complete Atrio Ventricular Block, LVEDD=Left Ventricular End-Diastolic Dimension, LVESD=Left Ventricular End-Systolic Dimension, SSS=Sick Sinus Syndrome.

Changes in all the measured parameters were significant, as represented in Figure 1 and Table 2. Sm [cm/sec] decreased from 6.65 to 5.27 (*p*<0.001) and Em [cm/sec] from 7.32 to 5.10 (*p*<0.001). LAV [mm³] increased from 37.31 to 54.32 (*p*<0.001) and septum to lateral asynchrony [msec] from 18.35 to 61.65 (*p*<0.001). LVEF [%] variation was from 70.28 to 60.65 (*p*=0.001) and LVESD [mm] from 27.44 to 31.91 (*p*=0.001). LVEDD [mm] increased from 46.07 to 49.63 (*p*=0.005).

Table 2: Pre-and post- pacemaker implantation echocardiographic findings of patients with right ventricular apical pacing.

	Pre-pacemaker	Post-pacemaker	Change (%)	p value
LVEF [%]	70.28±11.16	60.65±13.21	13.75↓	0.001
LAV [ml]	37.31±9.68	54.32±16.97	45.59↑	<0.001
LVEDD [mm]	46.07±6.61	49.63±6.67	7.72 ↑	0.005
LVESD [mm]	27.41±6.21	31.91±7.76	16.38↑	0.001
Sm [cm/sec]	6.65±1.42	5.27±0.98	20.75 ↓	<0.001
Em [cm/sec]	7.32±2.21	5.10±1.52	30.32 ↓	<0.001
Septum to lateral asynchrony [msec]	18.35±15.87	61.65±24.35	235.96 ↑	<0.001

Em=Peak velocity of early diastolic myocardial relaxation (by tissue-Doppler imaging), LAV=Left atrial volume, LVEDD=Left ventricular end-diastolic diameter, LVEF=Left ventricular ejection fraction (by Simpson's rule), LVESD=Left ventricular end-systolic diameter, Sm=Peak velocity of myocardial shortening (by tissue-Doppler imaging).

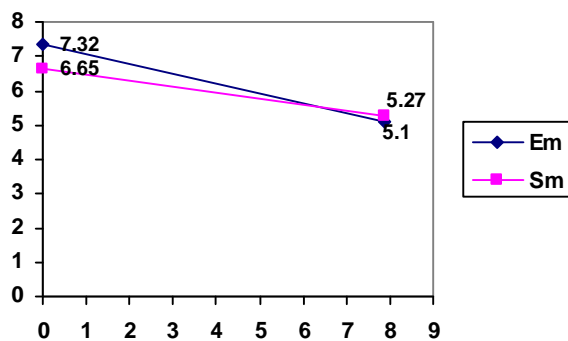


Fig 1: Variation of Tissue- Doppler Imaging parameters (Em and Sm); pre- and post- pacemaker implantation. Em=peak velocity of early diastolic myocardial relaxation, Sm= Peak velocity of myocardial shortening

Discussion

Several studies have demonstrated the deleterious consequences of short, mid and long-term RVA pacing on both systolic and diastolic LV function, especially in the presence of congestive heart failure (CHF). However, a few of them used TDI technique (instead of conventional echocardiography) for this purpose. In a longitudinal controlled study including 24 young patients with a mean FU of 9.5 years, RVA pacing led to irreversible LV systolic and diastolic dysfunction.¹⁷

In another study on 12 patients with RVA pacing, regional myocardial perfusion and wall motion abnormalities were demonstrated near the site of ventricular stimulation at 6 months after implantation, and these abnormalities increased and extended to remote sites with duration of pacing at 18 months of FU. This resulted in a significant reduction in global

LV function.²⁰ In addition, during a 20 month FU in a MADIT II sub-study, the patients (n=369) having high cumulative RV pacing (>50%), had a higher incidence of new or worsened heart failure (HF) or death compared to patients (n=198) with infrequent RV pacing.³⁸

In another study on 17 patients with chronic HF and a dual-chamber implantable cardioverter defibrillator, who were randomized either to back-up pacing or permanent RV pacing for 3 months, the authors concluded that for patients with chronic HF and adequate AV conduction, every effort should be made to minimize permanent RV pacing.³⁹

Among 307 chronic patients, 54% had symptoms of HF, with a slightly higher prevalence in those with single chamber pacemakers (57%) compared to a dual-chamber device (50%).⁴⁰ With increasing years of pacing, an increasing prevalence of both HF due to LV systolic dysfunction and of atrial fibrillation was documented.

Consistent with these studies, we observed a statistically significant reduction in EF and septum to lateral asynchrony as conventional echocardiographic characters of systolic LV dysfunction and also significant increment in LVEDD as a marker of diastolic LV dysfunction.

Regarding TDI technique, John *et al.* studied 21 patients with normal LV systolic function who had undergone conventional dual-chamber pacemaker implantation for SSS at least 6 months prior to entering the study. After a minimum FU of 3 months, the effects of ventricular pacing were evaluated by conventional echocardiography and TDI. Both methods showed significant reduction in systolic LV function, represented as decrease in LVEF and Sa (peak systolic velocity of filling wave at the septal and lateral mitral annulus). But LV diastolic function did not

show significant changes in both conventional and in TDI (as Ea which is peak early diastolic velocity of filling wave at the septal and lat mitral annulus). However, in our study a significant reduction was demonstrated not only in LV systolic (Sm) but also in LV diastolic function (Em), using TDI technique.

Changes of all the mentioned parameters, however, were independent of pacing duration, frequency or mode (single- VS dual- chamber). This is most likely due to short-duration and restrictive range of FU (mean=7.86 months), high cumulative pacing in all patients (>90%) and the limited number of patients, respectively.

One of the deleterious effects of RVA pacing is LA enlargement.⁴¹ However, we did not find any study that measured LAV for this purpose. For example, when Nielsen *et al.*^{33,42} followed 177 patients with SSS and AAIR or DDDR pacemaker for 2.9±1.1 years, they concluded that only DDDR group had increased LA diameter and no changes occurred in LA diameter during AAIR pacing. Therefore, they suggested that atrial pacing be preferred over RVA pacing in patients with SSS and normal AV conduction.

In our study, the mean LA volume increment was from 37.31 mm³ to 54.32 mm³, which was statistically significant. However, it did not correlate with FU duration, pacing frequency or mode. The positive correlation of LAV with LVEDD and LVESD and the negative correlation with LVEF had been demonstrated by Teresa *et al.*⁴³ In a study on 140 adults who were referred for a clinically- indicated echocardiogram,

they proved that LAV correlates positively with age, body surface area, cardiovascular risk score, LVEDD and LVESD and negatively with LVEF. This was also true for patients without a history of atrial arrhythmias or VHD; LAV expressed the severity of diastolic dysfunction and provided an index of cardiovascular risk and disease burden.

RVA pacing has deleterious effects on both LV systolic and diastolic parameters of not only conventional echocardiography but also TDI even in patients with normal LV function. In addition, LAV increases significantly and this increase correlates with LV systolic and diastolic dysfunction. According to this study which is consistent with the majority of previous studies, we can not be complacent with such a routine practice any longer and it may direct our attention to alternate sites of pacing, such as the LV and/or the RV outflow tract.

Although our patients had no evidence of ACS, they may have had clinically silent coronary artery disease that contributed to the functional myocardial abnormalities; limited number of patients and FU duration are other limitations.

Acknowledgement

We express our gratitude to Dr Aslani A. and the staff of the echocardiographic laboratory, without whose support and help this study would not have been possible.

Conflict of interest: None declared.

References

- 1 Tse HF, Lau CP. Long-term effect of right ventricular pacing on myocardial perfusion and function. *J Am Coll Cardiol* 1997;**29**:744-9. [9091519] [doi:10.1016/S0735-1097(96)00586-4]
- 2 Lamas GA, Ellenbogen KA. Evidence base for pacemaker mode selection: from physiology to randomized trials. *Circulation* 2004;**109**:443-51. [14757681] [doi:10.1161/01.CIR.0000115642.05037.0E]
- 3 de Cock CC, Giudici MC, Twisk JW. Comparison of the haemodynamic effects of right ventricular outflow-tract pacing with right ventricular apex pacing: a quantitative review. *Europace* 2003;**5**:275-8. [12842643] [doi:10.1016/S1099-5129(03)00031-X]
- 4 Melo CS (ed.). *Temas de marcapasso*. 2a ed. Sao Paulo: Lemos Editorial; 2004.
- 5 Baldasseroni S, Opasich C, Gorini M, Lucci D, Marchionni N, Marini M, Campana C, Perini G, Deorsola A, Masotti G, Tavazzi L, Maggioni AP; Italian Network on Congestive Heart Failure Investigators. Left bundle-branch block is associated with increased 1-year sudden and total mortality rate in 5517 outpatients with congestive heart failure: a report from the Italian network on congestive heart failure. *Am Heart J* 2002;**143**:398-405. [11868043] [doi:10.1067/mhj.2002.121264]
- 6 Shamim W, Francis DP, Yousufuddin M, Varney S, Pieopli MF, Anker SD, Coats AJ. Intraventricular conduction delay: a prognostic marker in chronic heart failure. *Int J Cardiol* 1999;**70**:171-8. [10454306] [doi:10.1016/S0167-5273(99)00077-7]
- 7 Grines CL, Bashore TM, Boudoulas H, Olson S, Shafer P, Wooley CF. Functional abnormalities in isolated left bundle branch block. The effect of interventricular asynchrony. *Circulation* 1989;**79**:845-53. [2924415]
- 8 Xiao HB, Lee CH, Gibson DG. Effect of left bundle branch block on diastolic function in dilated cardiomyopathy. *Br Heart J* 1991;**66**:443-7. [1772710] [doi:10.1136/hrt.66.6.443]
- 9 Xiao HB, Roy C, Fujimoto S, Gibson DG. Natural history of abnormal conduction and its relation to prognosis in patients with dilated cardiomyopathy. *Int J Cardiol* 1996;**53**:163-70. [8682602] [doi:10.1016/0167-5273(95)

- 02502-2]
- 10 Ozdemir K, Altunkeser BB, Daniş G, Ozdemir A, Uluca Y, Tokaç M, Telli HH, Gök H. Effect of the isolated left bundle branch block on systolic and diastolic functions of left ventricle. *J Am Soc Echocardiogr* 2001;**14**: 1075-9. [11696831] [doi:10.1067/mje.2001.115655]
 - 11 Lee SJ, McCulloch C, Mangat I, Foster E, De Marco T, Saxon LA. Isolated bundle branch block and left ventricular dysfunction. *J Card Fail* 2003;**9**:87-92. [12751128] [doi:10.1054/jcaf.2003.19]
 - 12 Littmann L, Symanski JD. Hemodynamic implications of left bundle branch block. *J Electrocardiol* 2000;**33**:115-21. [11265710] [doi:10.1054/jelc.2000.20330]
 - 13 Shenkman HJ, Pampati V, Khandelwal AK, McKinnon J, Nori D, Kaatz S, Sandberg KR, McCullough PA. Congestive heart failure and QRS duration: establishing prognosis study. *Chest* 2002;**122**:528-34. [12171827] [doi:10.1378/chest.122.2.528]
 - 14 Hesse B, Diaz LA, Snader CE, Blackstone EH, Lauer MS. Complete bundle branch block as an independent predictor of all-cause mortality: report of 7,073 patients referred for nuclear exercise testing. *Am J Med* 2001;**110**:253-9. [11239842] [doi:10.1016/S0002-9343(00)00713-0]
 - 15 Tanabe A, Mohri T, Ohga M, Yoshiga O, Hidaka Y, Ikeda H, Hiayamuta K, Koga Y, Toshima H. The effects of pacing-induced left bundle branch block on left ventricular systolic and diastolic performances. *Jpn Heart J* 1990;**31**:309-17. [2214133]
 - 16 Modena MG, Mattioli AV, Mattioli G. Right ventricular pacing and left ventricular filling pattern. An echodoppler study. *Chest* 1991;**100**:744-7. [1889268] [doi:10.1378/chest.100.3.744]
 - 17 Tantengco MV, Thomas RL, Karpawich PP. Left ventricular dysfunction after long-term right ventricular apical pacing in the young. *J Am Coll Cardiol* 2001;**37**:2093-100. [11419893] [doi:10.1016/S0735-1097(01)01302-X]
 - 18 Karpawich PP, Rabah R, Haas JE. Altered cardiac histology following apical right ventricular pacing in patients with congenital atrioventricular block. *Pacing Clin Electrophysiol* 1999;**22**:1372-7. [10527019] [doi:10.1111/j.1540-8159.1999.tb00631.x]
 - 19 Thambo JB, Bordachar P, Garrigue S, Lafitte S, Sanders P, Reuter S, Girardot R, Crepin D, Reant P, Roudaut R, Jais P, Haïssaguerre M, Clementy J, Jimenez M. Detrimental ventricular remodeling in patients with congenital complete heart block and chronic right ventricular apical pacing. *Circulation* 2004;**110**:3766-72. [15583083] [doi:10.1161/01.CIR.0000150336.86033.8D]
 - 20 Tse HF, Yu C, Wong KK, Tsang V, Leung YL, Ho WY, Lau CP. Functional abnormalities in patients with permanent right ventricular pacing: the effect of sites of electrical stimulation. *J Am Coll Cardiol* 2002;**40**:1451-8. [12392836] [doi:10.1016/S0735-1097(02)02169-1]
 - 21 Hamdan MH, Zagrodzky JD, Joglar JA, Sheehan CJ, Ramaswamy K, Erdner JF, Page RL, Smith ML. Biventricular pacing decreases sympathetic activity compared with right ventricular pacing in patients with depressed ejection fraction. *Circulation* 2000;**102**:1027-32. [10961968]
 - 22 Bedotto JB, Grayburn PA, Black WH, Raya TE, McBride W, Hsia HH, Eichhorn EJ. Alterations in left ventricular relaxation during atrioventricular pacing in humans. *J Am Coll Cardiol* 1990;**15**:658-64. [2303636]
 - 23 Badke FR, Boinay P, Covell JW. Effects of ventricular pacing on regional left ventricular performance in the dog. *Am J Physiol* 1980;**238**:H858-67. [7386645]
 - 24 Owen CH, Esposito DJ, Davis JW, Glower DD. The effects of ventricular pacing on left ventricular geometry, function, myocardial oxygen consumption, and efficiency of contraction in conscious dogs. *Pacing Clin Electrophysiol* 1998;**21**:1417-29. [9670186] [doi:10.1111/j.1540-8159.1998.tb00213.x]
 - 25 Betocchi S, Piscione F, Villari B, Pace L, Ciarmiello A, Perrone-Filardi P, Salvatore C, Salvatore M, Chiariello M. Effects of induced asynchrony on left ventricular diastolic function in patients with coronary artery disease. *J Am Coll Cardiol* 1993;**21**:1124-31. [8459065]
 - 26 Stojnić BB, Stojanov PL, Angelkov L, Pavlović SU, Radjen GS, Velimirović DB. Evaluation of asynchronous left ventricular relaxation by Doppler echocardiography during ventricular pacing with AV synchrony (VDD): comparison with atrial pacing (AAI). *Pacing Clin Electrophysiol* 1996;**19**:940-4. [8774824] [doi:10.1111/j.1540-8159.1996.tb03390.x]
 - 27 Søgaard P, Egeblad H, Kim WY, Jensen HK, Pedersen AK, Kristensen BØ, Mortensen PT. Tissue Doppler imaging predicts improved systolic performance and reversed left ventricular remodeling during long-term cardiac resynchronization therapy. *J Am Coll Cardiol* 2002;**40**:723-30. [12204503] [doi:10.1016/S0735-1097(02)02010-7]
 - 28 Ansalone G, Giannantoni P, Ricci R, Trambaiolo P, Laurenti A, Fedele F, Santini M. Doppler myocardial imaging in patients with heart failure receiving biventricular pacing treatment. *Am Heart J* 2001;**142**:881-96. [11685178] [doi:10.1067/mhj.2001.117324]
 - 29 Yu CM, Chau E, Sanderson JE, Fan K, Tang MO, Fung WH, Lin H, Kong SL, Lam YM, Hill MR, Lau CP. Tissue Doppler echocardiographic evidence of reverse remodeling and improved synchronicity by simultaneously delaying regional contraction after biventricular pacing therapy in heart failure. *Circulation* 2002;**105**:438-45. [11815425] [doi:10.1161/hc0402.102623]
 - 30 Ansalone G, Giannantoni P, Ricci R, Trambaiolo P, Fedele F, Santini M. Doppler myocardial imaging to evaluate the effectiveness of pacing sites in patients receiving biventricular pacing. *J Am Coll Cardiol* 2002;**39**:489-99. [11823088] [doi:10.1016/S0735-1097(01)01772-7]
 - 31 Garcia MJ, Rodriguez L, Ares M, Griffin BP, Klein AL, Stewart WJ, Thomas JD. Myocardial wall velocity assessment by pulsed Doppler tissue imaging: characteristic findings in normal subjects. *Am Heart J* 1996;**132**:648-56. [8800038] [doi:10.1016/S0002-8703(96)90251-3]
 - 32 Pellerin D, Berdeaux A, Cohen L, Giudicelli JF, Witczitz S, Veyrat C. Pre-ejectional left ventricular wall motions studied on conscious dogs using Doppler myocardial imaging: relationships with indices of left ventricular function. *Ultrasound Med Biol* 1998;**24**:1271-83. [10385949] [doi:10.1016/S0301-5629(98)00119-7]
 - 33 Sohn DW, Chai IH, Lee DJ, Kim HC, Kim HS, Oh BH, Lee MM, Park YB, Choi YS, Seo JD, Lee YW. Assessment of mitral annulus velocity by Doppler tissue imaging in the evaluation of left ventricular diastolic function. *J Am Coll Cardiol* 1997;**30**:474-80. [9247521] [doi:10.1016/S0735-1097(97)88335-0]
 - 34 Waggoner AD, Faddis MN, Gleva MJ, de las Fuentes L, Dávila-Román VG. Improvements in left ventricular diastolic function after cardiac resynchronization therapy are coupled to response in systolic performance. *J Am Coll Cardiol* 2005;**46**:2244-9. [16360053] [doi:10.1016/j.jacc.2005.05.094]
 - 35 Chiladakis JA, Koutsogiannis N, Kalogeropoulos A, Zagli F, Arvanitis P, Alexopoulos D. Unfavourable effects of continuous, atrial-synchronised ventricular pacing on ventricular systolic and diastolic function in patients with normal left ventricular ejection fraction: usefulness of tissue and colour Doppler echocardiography. *Hellenic J Cardiol* 2007;**48**:335-40. [18196655]

- 36 Quiñones MA, Otto CM, Stoddard M, Waggoner A, Zoghbi WA; Doppler Quantification Task Force of the Nomenclature and Standards Committee of the American Society of Echocardiography. Recommendations for quantification of Doppler echocardiography: a report from the Doppler Quantification Task Force of the Nomenclature and Standards Committee of the American Society of Echocardiography. *J Am Soc Echocardiogr* 2002;**15**:167-84. [11836492] [doi:10.1067/mje.2002.120202]
- 37 Schiller NB, Shah PM, Crawford M, DeMaria A, Devereux R, Feigenbaum H, Gutgesell H, Reichek N, Sahn D, Schnittger I, et al. Recommendations for quantitation of the left ventricle by two-dimensional echocardiography. American Society of Echocardiography Committee on Standards, Subcommittee on Quantitation of Two-Dimensional Echocardiograms. *J Am Soc Echocardiogr* 1989;**2**:358-67. [2698218]
- 38 Steinberg JS, Fischer A, Wang P, Schuger C, Daubert J, McNitt S, Andrews M, Brown M, Hall WJ, Zareba W, Moss AJ; MADIT II Investigators. The clinical implications of cumulative right ventricular pacing in the multicenter automatic defibrillator trial II. *J Cardiovasc Electrophysiol* 2005;**16**:359-65. [15828875]
- 39 Wonisch M, Lercher P, Scherr D, Maier R, Pokan R, Hofmann P, von Duvillard SP. Influence of permanent right ventricular pacing on cardiorespiratory exercise parameters in chronic heart failure patients with implanted cardioverter defibrillators. *Chest* 2005;**127**:787-93. [15764758] [doi:10.1378/chest.127.3.787]
- 40 Thackray SD, Witte KK, Nikitin NP, Clark AL, Kaye GC, Cleland JG. The prevalence of heart failure and asymptomatic left ventricular systolic dysfunction in a typical regional pacemaker population. *Eur Heart J* 2003;**24**:1143-52. [12804929] [doi:10.1016/S0195-668X(03)00199-4]
- 41 Manolis AS. The deleterious consequences of right ventricular apical pacing: time to seek alternate site pacing. *Pacing Clin Electrophysiol* 2006;**29**:298-315. [16606399] [doi:10.1111/j.1540-8159.2006.00338.x]
- 42 Nielsen JC, Kristensen L, Andersen HR, Mortensen PT, Pedersen OL, Pedersen AK. A randomized comparison of atrial and dual-chamber pacing in 177 consecutive patients with sick sinus syndrome: echocardiographic and clinical outcome. *J Am Coll Cardiol* 2003;**42**:614-23. [12932590] [doi:10.1016/S0735-1097(03)00757-5]
- 43 Tsang TS, Barnes ME, Gersh BJ, Bailey KR, Seward JB. Left atrial volume as a morphophysiologic expression of left ventricular diastolic dysfunction and relation to cardiovascular risk burden. *Am J Cardiol* 2002;**90**:1284-9. [12480035] [doi:10.1016/S0002-9149(02)02864-3]