

Vascular Insufficiency or Neurologic Problem? The Importance of Physical Examination

Dear Editor,

In atherosclerosis, the distal abdominal aorta and the iliac arteries are the most common sites of involvement. Aortoiliac occlusive disease rarely occurs in a younger group of patients (aged in their mid-50s), as compared with patients suffering from femoro-popliteal disease. It also differs from the disease of the femoral-popliteal-tibial segment since it is rarely limb threatening. Symptoms typically consist of bilateral thigh or buttock claudication and fatigue. Men report diminished penile tumescence, and later there may be complete failure of erectile function. These symptoms constitute Leriche's syndrome. Rest pain is unusual with isolated aortoiliac disease. Femoral pulses are usually diminished or absent. There are usually no stigmata of ischemia unless distal disease coexists.¹⁻⁴ A small group of patients report a prolonged history of thigh and buttock claudication that has recently become more severe. It is likely that this group has underlying significant aortoiliac disease that has suddenly progressed to acute occlusion of the terminal aorta⁵ as in the patient discussed in this article.

Our patient was a 48 years old man referred to our center due to increased levels of plasma BUN and Creatinine and admitted in the nephrology ward with the impression of acute renal failure. Because the patient had a history of lower extremity weakness which aggravated from one week prior to his admission, neurologic consultation was done but all workups including MRI and CT scan of the spine were normal. As cardiomegaly and collapse of the middle lobe of the right lung was detected in chest x-ray, chest CT scan was done and incidentally, total occlusion of descending aorta at the diaphragm level was detected. (Figure 1) Further physical examination showed the absence of distal pulses of lower extremities and very weak bilateral femoral pulses. As a result, the patient was operated with the impression of aortoiliac occlusive disease. During the

operation, aortic endarterectomy, aorto-superior mesenteric, bilateral aortorenal and aortobifemoral bypass grafting were done. In the post-op period, distal pulses of lower extremities and urine output restored to normal and the patient was discharged with outpatient follow-up.

As noticed here, a small group of patients reported a prolonged history of thigh and buttock claudication that has recently become more severe. It is likely that this group has underlying significant aortoiliac disease that has suddenly progressed to acute occlusion of the terminal aorta⁵ in which femoral pulses are usually diminished or absent.

The key point of this article is that if a complete physical examination of the patient is done at first visit, his/her problem can be detected more quickly. Although many imaging devices are used for clinical diagnosis, physical examination still has a very important role. So, as mentioned in our article, in addition to a good history taking, a complete physical examination can guide us to a definite clinical diagnosis.

Keywords: Aortoiliac occlusive disease; Physical examination; Neurologic problem

Conflict of interest: None declared.

H Hodjati¹, H Ghoddusi Johari^{1*}, S Zeraatian-Nejad Davani¹

¹General Surgery Department, Trauma Research Center, Shiraz University of Medical Sciences, Shiraz, Iran

*Correspondence: Hamed Ghoddusi Johari, MD, Resident of General Surgery, General Surgery Department, Trauma Research Center, Shiraz University of Medical Sciences, P.O.Box: 71345-1876, Shiraz, Iran. Tel: +98-917-713-1640, Fax: +98-711-2330724, e-mail: ghoddusih@yahoo.com
Received: May 2, 2008

Accepted: October 1, 2008

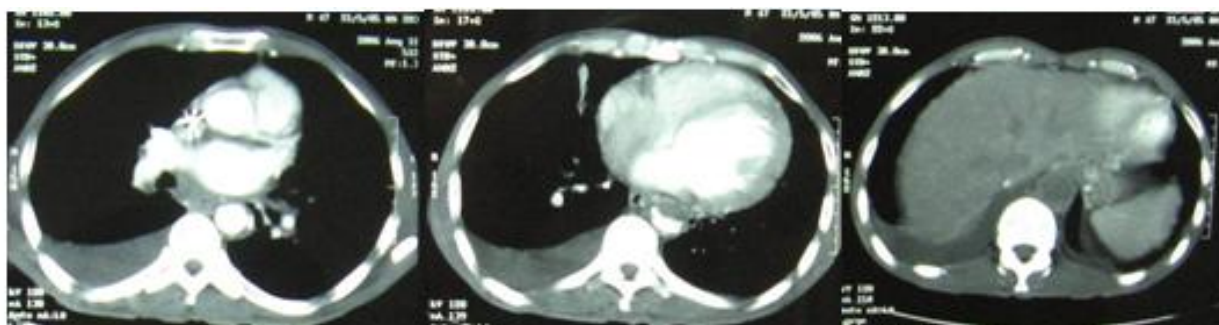


Fig 1: CT scan showing total occlusion of descending aorta at level of diaphragm.

References

- 1 Crawford ES, Bomberger RA, Glaeser DH, Saleh SA, Russell WL. Aortoiliac occlusive disease: factors influencing survival and function following reconstructive operation over a twenty-five-year period. *Surgery* 1981;**90**:1055-67. [7313940]
- 2 Rutherford RB. Aortobifemoral bypass, the gold standard: technical considerations. *Semin Vasc Surg* 1994;**7**:11-6. [8180750]
- 3 Dormandy JA, Rutherford RB. Management of peripheral arterial disease (PAD). TASC Working Group. TransAtlantic Inter-Society Consensus (TASC). *J Vasc Surg* 2000;**31**: S1-S296. [10666287] [doi:10.1016/S0741-5214(00)70062-0]
- 4 Rutherford RB. Options in the surgical management of aorto-iliac occlusive disease: a changing perspective. *Cardiovasc Surg* 1999;**7**:5-12. [10073753] [doi:10.1016/S0967-2109(98)00130-6]
- 5 Lumsden AB, et al. Arterial Disease in: Schwartz's Principles of Surgery. 8th ed., Mc Graw Hill Co., 2005; pp. 764-767.