

## Studies on the Fine Structure of Caeca in Domestic Geese

Yieng How Chen<sup>1</sup>, Hoang Kao Hsu<sup>2</sup> and Jenn Chung Hsu\*

Department of Animal Science, National Chung-Hsing University, 250 Kao-Kung Road, Taichung, 402, Taiwan, ROC

**ABSTRACT :** The objective of this study was to investigate the villus distribution in the caeca of domestic geese based on the fine structure. The caeca of White Roman geese, 14-week old, were sampled and specimens were detected under photomicroscope and scanning electron microscope (SEM). The results indicated that the villi existed at the proximal caecum. The morphologies of these villi showed finger-like, peak-like or tongue-like shapes. The heights of the villi decreased far from the proximal caecum. No villi were found in the middle and distal caecum. It was obvious that the proximal segment was the main portion for absorbing food nutrients in the caeca. The caecal content particles were small and possessed a viscoid character. The large particles filtered out at the proximal caecum just like a mesh. The surface of the middle caecum exhibited parallel ridges with no villi. There were band plicae circular shapes found in the middle caecum under scanning electron microscopy. (*Asian-Aust. J. Anim. Sci.* 2002. Vol 15, No. 7 : 1018-1021)

**Key Words :** Caecum, Scanning Electron Microscopy, Villi

### INTRODUCTION

Most birds possess caeca. However, in a few birds the caeca is small. Bee-eater birds have only a vestigial caeca with no function and caeca is absent in the swift (McLelland, 1989). Geese are herbivorous and have a pair of well-developed caeca which were 54-60 cm in length (Chen et al., 1992). The caecum is the main digestive segment for degrading cellulose in the alimentary canal of geese (Clemens et al., 1975); Yang and Lin (1975) showed that cellulose digestibility decreased 21% in caecal ligated geese. It was suggested that the caeca of geese possessed the function for digesting cellulose. Caeca with a fine structure has been reported in some species of poultry, e.g. quail (Fenna and Boag, 1974), turkeys (Sudo and Duke, 1980) and chickens (Ferrer et al., 1991). However, the fine structure of caeca in geese has not been investigated. This study, therefore, was conducted to explore the villus distribution in the caeca using the photomicroscope and scanning electron microscope (SEM) in order to establish basal data on the fine structure of the caecum in geese.

### MATERIALS AND METHODS

#### Experimental materials

White Roman geese were fed a commercial diet. Water and feed were supplied *ad libitum*. At 14 wks of age, geese were slaughtered by neck vein bleeding. At necropsy, the caeca were immediately removed and divided into three

parts, proximal, middle, and distal segments. The left caecum was taken for the histological detection and the right caecum for the SEM examination (figure 1).

#### Preparation of samples for SEM

Caecal samples were prepared for the SEM according to the method of Paulini et al. (1987) that was a modified method of Moore et al. (1988). All caecal samples were first rinsed with physiological salt water (0.9%), then fixed in 2.5% glutaric dialdehyde in phosphate buffer (pH 7.3) for 2 h (Tsai and Wang, 1993). The specimens were postfixed in 1% Osmium tetroxide 0.1 M phosphate buffer solution (pH 7.3) for 2 h. The samples were rinsed in the phosphate buffered solution 1 time and distilled water 3 times, for a duration of 10 min each. Thereafter, the samples were gradually dehydrated using increasing alcohol concentrations (30%, 50%, 70%, 80%, 90%, and 95%) for 15 min each and the absolute alcohol for the final 3 rinses. The samples were dried at the critical point dryer (CPD), mounted on aluminum stubs with double adhesive tape and coated with gold film about 20 nm thickness, and observed with SEM (Topcon 150S) at 15 kv.

#### Preparation of samples for histological detection

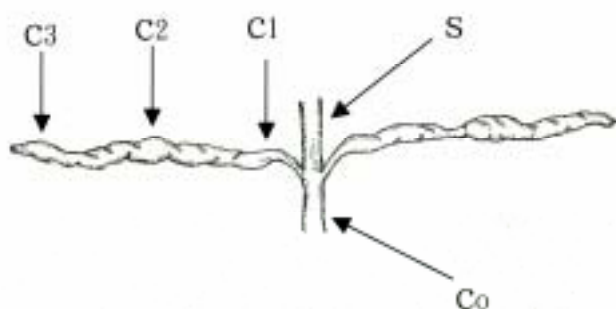
Caecal samples were placed into 10% buffered neutral formaldehyde solution (pH 7.2) and shaken 24 h for fixation according to the method of Chiou et al. (1996). Then, all samples were dehydrated gradually by increasing concentrations of ethyl alcohol (60-100%) for 1-1.5 h each. Those specimens were embedded in paraffin and then sliced into 6 µm strips. The slices were stained with hematoxylin and eosin, and mounted with mounting media. Thereafter, the specimens were placed into a photomicroscope (ZEISS AXIOSKOP) for histological observation.

\* Address reprint request to Jenn-Chung Hsu. Tel: +886-4-22850315, Fax: +886-4-22860265, E-mail: jchsu@dragon.nchu.edu.tw

<sup>1</sup> Department of Animal Science, College of Agriculture, Tunghai University, Taichung, Taiwan 406, ROC.

<sup>2</sup> Department of Plant Pathology, National Chung-Hsing University, 250 Kao-Kung Road, Taichung, 402, Taiwan, ROC.

Received August 27, 2001; Accepted January 24, 2002



C1: Proximal caecum, C2: Middle caecum, C3: Distal caecum, S: Small intestine, Co: Colon.

**Figure 1.** Shape of caeca and sampling position.

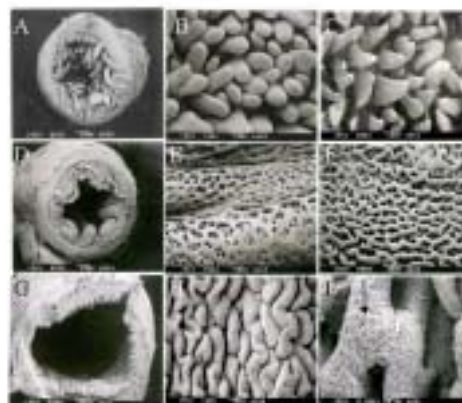## RESULTS

Figure 2 shows the scanning electron micrograph of the caecal in geese. There were villi in the proximal caecum (figure 2-A). The morphologies of these villi exhibited a finger-like (figure 2-B), peak-like or tongue-like shape (figure 2-C). The height of the villi increased as the villi neared the proximal caecum. Conversely, the villi height decreased as the position moved far from the proximal caecum. There were no villi (figure 2-D) but plicae circulares (figure 2-E) in the middle caecum. These plicae circulares were like long banded circle wires (figure 2-F). The distal caecum had no villi (Figure 2-G) and the surface was wrinkled (figure 2-H) with a few single glands (figure 2-I).

The histological detection results are showed in figure 3. In the proximal caecum, villi were found and had goblet cells and crypts, and the muscle layer was thicker (figure 3-A, 3-B). No villi in the middle zone caecum was found and the muscle layer was thin with saw-shaped or parallel ridged tract lumen (figure 3-C, 3-D). The distal caecal muscle layer was thinner than that in the proximal caecum and its surface was saw-shaped and no parallel ridges or villi were found. (figure 3-E, 3-F).

## DISCUSSION

The goose proximal caecum in this study showed that the villi were like that of chicken (Ferrer et al., 1991). These findings were different from Chiou et al. (1996) and Yu et al. (1998) who did not find villi in the caeca of geese with SEM. The different results may be due to sampling from a different position. This report took the sample from proximal middle and distal caecum in this study. However, Yu et al. (1998) took the samples from one position that might be middle or distal caecum. This study indicated that the height of the villi decreased as position moved far from



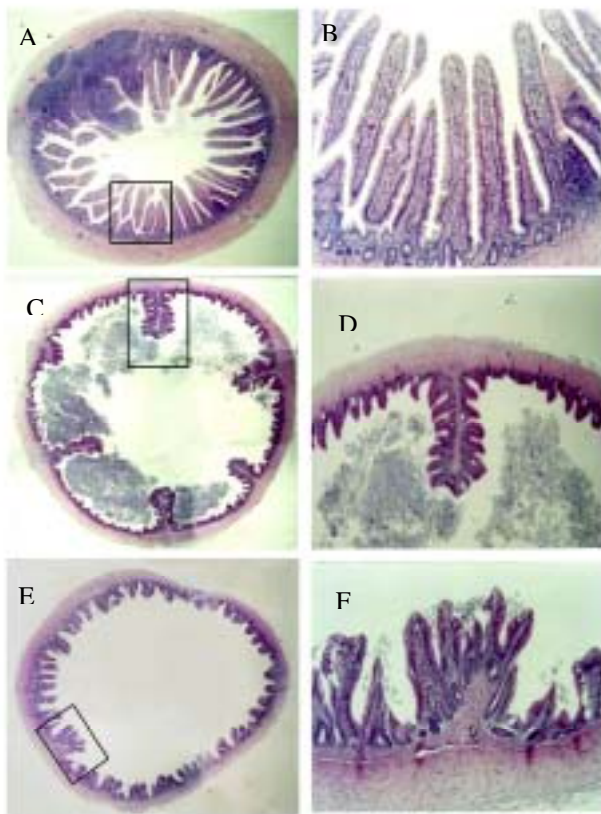
A	B	C
D	E	F
G	H	I

- A. Cross-section of the proximal zone showing villi filling the lumen ( $\times 25$ )  
 B. Finger-like villi in the proximal zone ( $\times 100$ )  
 C. Peak-like villi in the proximal zone ( $\times 80$ )  
 D. Cross-section of the middle zone showing no villi but plicae circulares ( $\times 25$ )  
 E. Plicae circulares surface in the middle zone ( $\times 50$ )  
 F. Lumen surface in the middle zone showing a wire-like structure ( $50\times$ )  
 G. Cross-section of the distal zone ( $\times 30$ )  
 H. Lumen surface in the distal zone showing plicae structure ( $\times 100$ )  
 I. Single glandular gland ( arrow ) in the distal zone ( $\times 500$ )

**Figure 2.** Scanning electron micrograph of the fine caecal structure in geese.

the proximal caecum. No villi were found in middle and distal caecum. These results concur with the findings in turkey and in Japanese quail reported by Sudo and Duke (1980) and Fenna and Boag (1974), who indicated that turkeys possessed well developed villi in the proximal caeca and the Japanese quail showed elongated villi filling the lumen in the proximal caeca. Hill (1971a,b) reported that the proximal part of the caeca was the main digestive portion for absorbing nutrients in domestic fowl. Sudo and Duke (1980) also pointed out that the mucosa of the proximal caecum in turkeys possessed well developed villi and this caecum portion would appear to have a greater potential for nutrient absorption than the distal segment. The present study also suggests a possibility that the proximal caecum might be absorptive function in geese.

The caecal contents in these geese had a smooth, viscous character which is in agreement with the findings of Fenna and Boag (1974) who observed that the caecal contents of



A (×10)	B (×40)	A. Up left show the proximal caecum, B. right is magnified partially
C (×10)	D (×40)	C. Middle left show the middle caecum, D. right is magnified partially
E (×10)	F (×100)	E. Bottom left show the distal caecum, F. right is magnified partially

**Figure 3.** The morphology of the caecal structure in geese.

birds were smooth and viscid because proximal caecum was just like a mesh that filtered out the large particles. Bjornhang and Seperber (1977) also found dry matter particle sizes larger than 0.2 mm were 3% in caeca, 38-45% in the small intestine, and 50% in the colon in turkey. In this study, the observed smooth character of caecal contents was associated with, or perhaps responsible for, the reduction in the particle size in the caecal contents. Globet cells produced mucus (Young and Heath, 2000) and were affected by medicine, e.g. Cyclosporine that increased the mucin volume (Phillips et al., 2000). The caecal villi have globet cells that may produce mucus, there by affecting the viscid content character in the caeca.

The histological specimens from the proximal caecum of geese exhibited the same character as that discussed in Fenna and Boag (1974) who stated that the Japanese quail caecum possessed villi and the middle zone of the caecal structure showing parallel ridges. Comparing histological

specimen photographs (figure 3-C) with the findings in SEM (figure 2-E), the parallel ridges are plicae circulares that end at the distal caecum. These parallel ridges increase the caecal wall surface area (Fenna and Boag, 1974; Ferrer et al., 1991). The histological specimens from the middle geese caecum showed parallel ridges like the Japanese quail (Fenna and Boag, 1974), but no villi in this segment were found in SEM (Yu et al., 1998). Long band plicae circulares drew digesta into the caecum and delayed the digesta rate (Stevens and Hume, 1995). Plicae circulares may have a blocking function when the caecal contents are emptied. The proximal end was narrow. The caecal contents of geese emptied once every 4 h (Yang and Lin, 1975), with not all contents emptied once a day, so plicae circulares were correlated to content digestion. Whether this phenomenon relates to nutrient absorption or another physiological function is unknown. This study suggest that further research is required to resolve this problem.

Histological specimens from the caecum showed tract lumen in the middle and distal caecum that had a saw-like shape. SEM examination showed a wire net structure.

#### ACKNOWLEDGEMENTS

This study was funded by National Science Council ( NSC 86-2313-B005-023 ) in Taiwan. We give our thanks and appreciation to instructor Cheng-Chung Lin, and Ching-Lin Shyu, Miss Shu-Hui Chang, and Mr. Ching-Chang Cheng of the Department of Veterinary Medicine for their help with sample preparation for histological detection and photo microscopic examination.

#### REFERENCES

- Bjornhang, G. and I. Seperber, 1977. Transport of various food components through the digestive tract of turkey, geese, and guinea fowl. *Swedish J. Agric. Res.* 7:57-66.
- Chen, Y. H., J. C. Hsu and B. Yu. 1992. Effects of dietary fiber levels on growth performance, intestinal fermentation and cellulase activity of goslings. *J. Chin. Soc. Anim. Sci.* 21(2):15-28. (in Chinese)
- Chiou, P. W. S., T. W. Lu, J. C. Hsu and B. Yu. 1996. Effect of different sources of fiber on the intestinal morphology of domestic geese. *Asian-Aus. J. Anim. Sci.* 9(5):539-550.
- Clemens, T. C., C. E. Stevens and M. Southworth. 1975. Sites of organic acid production and pattern of digesta movement in the gastrointestinal tract of geese. *J. Nutr.* 115:1341-1350.
- Fenna, L. and D. A. Boag, 1974. Adaptive significance of the caeca in Japanese quail and spruce grouse. *Can. J. Zool.* 52:1577-1584.
- Ferrer, R., J. M. Planas, M. Durfort and M. Moreto, 1991. Morphological study of the caecal epithelium of the chicken (*Gallus Gallus Domesticus L.*) *Br. Poult. Sci.* 32:679-691.
- Hill, K. J. 1971a. The structure of the alimentary tract. In:

- Physiology and biochemistry of the domestic fowl. Vol. . (Ed. D. J. Bell and B. M. Freeman). Academic Press, New York. p. 20.
- Hill, K. J. 1971b. The physiology of digestion. In: Physiology and biochemistry of the domestic fowl. Vol. I. (Ed. D. J. Bell and B. M. Freeman). Academic Press, New York. p. 32.
- McLelland, J. 1989. Anatomy of the avian cecum. J. Exp. Zool. Suppl. 3:2-9.
- Moore, R. J., E. T. Kornegay, R. L. Grayson and M. D. Lindemann. 1988. Growth, nutrient utilization and intestinal morphology of pigs fed high fiber diets. J. Anim. Sci. 66:1570-1579.
- Paulini, I., T. Mehta and A. Hargis. 1987. Intestinal structural changes in African green monkeys after long term psyllium or cellulose feeding. J. Nutr. 117:253-266.
- Phillips, T. E., J. McHugh and C. P. Moore. 2000. Cyclosporine has a direct effect on the differentiation of mucin-secreting cell line. J. Cell Physiol. 184(3):400-408.
- Sudo S. Z. and G. E. Duke. 1980. Kinetics of absorption of volatile fatty acids from the ceca of domestic turkeys. Comp. Biochem. Physiol. 67A:231-237.
- Stevens, C. E. and I. D. Hume, 1995. Comparative Physiology of the Vertebrate Digestive System. Cambridge University, New York, USA. pp. 21-145.
- Tsai S. F. and J. S. Wang. 1993. Observations on the endogenous stages of *Eimeria stiedae* under scanning electron microscopy. J. Chin. Parasitol. 6:35-39.
- Yang, C. P. and C. S. Lin, 1975. The available of fiber feed of domestic geese. .The function of caecum digest cellulose. J. Chin. Soc. Anim. Sci. 4:41-46 ( in Chinese ) .
- Young, B. and J. W. Heath, 2000. Wheater's Functional Histology. Harcourt Publisher, New York, USA. p. 263.
- Yu, B., C. C. Tsai, J. C. Hsu and P. W. S. Chiou, 1998. Effect of different source of dietary fiber on growth performance, intestinal morphology and caecal carbohydrases of domestic geese. Br. Poult. Sci. 39:560-567.















